

UDC: 616-092.19-06-07

[https://doi.org/10.32345/USMYJ.4\(142\).2023.28-36](https://doi.org/10.32345/USMYJ.4(142).2023.28-36)

Received: April 17, 2023

Accepted: October 14, 2023

## Antisynthetase syndrome: a case report and review of the literature

Fiialkovska Olesia<sup>1</sup>, Karasevska Tetiana<sup>2</sup>, Ivashkivskiy Oleksiy<sup>3</sup>, Potomka Ruslana<sup>3</sup>,  
Novytska Hanna<sup>3</sup>, Dzhus Marta<sup>2,3</sup>

<sup>1</sup>Student of Bogomolets National Medical University, Kyiv, Ukraine

<sup>2</sup>Internal Medicine Department №2, Bogomolets National Medical University, Kyiv, Ukraine

<sup>3</sup>Communal non-commercial enterprise «Olexandrivska Clinical Hospital of Kyiv», Ukraine

### Address for correspondence:

Fiialkovska Olesia

E-mail: [fiialkovska.olesia@gmail.com](mailto:fiialkovska.olesia@gmail.com)

**Abstract:** *antisynthetase syndrome is a rare autoimmune disease characterized by interstitial lung disease, non-erosive arthritis, myositis, Raynaud's disease, and/or "mechanic hand" when autoantibodies directed against aminoacyl-tRNA synthetases are detected. Antisynthetase syndrome belongs to the group of idiopathic inflammatory myopathies and is the so-called overlap myositis. The article provides the latest literature data on the diagnostic value of myositis-specific autoantibodies based on a literature review for the period from 2013 to 2023 using the scientometric databases MEDLINE/PubMed, Wiley Online Library, and Scopus. Data from the literature show that certain myositis-specific autoantibodies, namely anti-PL-7 and anti-PL-12, can affect the risk of developing interstitial lung disease, and determine the course and prognosis of the disease. The presence of interstitial lung disease in patients with myositis correlates with increased morbidity and mortality. The article describes a clinical case of the debut of the antisynthetase syndrome from interstitial lung disease, which was falsely diagnosed as a coronavirus disease. The patient's condition improved only because of using glucocorticoids, which the patient stopped taking over time, which led to the worsening of pulmonary symptoms, the appearance of new clinical signs of damage to the joints and skin, progressive decrease in muscle function, and dysphagia. After an examination in the rheumatology department, based on the presence of interstitial lung disease in the patient - fibrotic alveolitis, which was confirmed by computer tomography, myositis, arthritis, characteristic skin changes, the presence of antinuclear antibodies, anti-SS-A/Ro52, specific antisynthetase antibodies (Jo-1, Pl-7, Pl-12), the diagnosis of the antisynthetase syndrome was established. A detailed laboratory and instrumental examination made it possible to rule out a paraneoplastic process at the time of examination. The prescribed treatment included pulse therapy with methylprednisolone and cyclophosphamide, which led to improvement in the patient's condition. The work carried out emphasizes the need for interdisciplinary interaction of pulmonologists, rheumatologists, and infectious disease specialists at the stage of verification of the final diagnosis and the therapy appointment. Achieving clinical and laboratory remission of the disease requires long-term monitoring by a rheumatologist.*

**Keywords:** [Autoantibodies](#), [Idiopathic Inflammatory Myopathy](#), [Lung Diseases](#), [Antibodies](#)

## Introduction

Idiopathic inflammatory myopathies (IIMs) are a heterogeneous group of systemic autoimmune rheumatic disorders characterized by progressive muscle weakness, histological changes in the form of inflammatory infiltrates of various degrees of severity in muscle tissue, and possible concomitant extra muscular lesions, mostly of the skin, lungs and joints (Lundberg IE et al., 2017). The incidence is approximately 5 per 100,000 people per year, and the annual prevalence can range from 15 to 33 per 100,000 people. This group of diseases includes polymyositis, dermatomyositis, necrotic autoimmune myopathy, sporadic myositis with inclusions, and overlap myositis (including antisynthetase syndrome). More than 50% of all patients with IIMs have unique autoantibodies, some of which are specific for myositis and some of which are simply associated with myositis. They are usually called myositis-specific autoantibodies (MSAs) and myositis-associated autoantibodies (MAAs), respectively (Hallowell RW, Danoff SK, 2023).

MSAs are highly specific for myositis and are used for differential diagnosis and determination of clinical variants of the disease, such as antisynthetase syndrome. The most common MSAs are synthetase antibodies directed against aminoacyl-tRNA synthetases: histidyl-tRNA synthetase (anti-Jo-1), glycyl-tRNA synthetase (anti-EJ), threonyl-tRNA synthetase (anti-PL-7), alanyl-tRNA synthetase (anti-PL-12), asparaginyl-tRNA synthetase (anti-KS), isoleucyl-tRNA synthetase (anti-OJ), tyrosyl-tRNA synthetase (anti-HA/YRS) and phenylalanyl-tRNA synthetase (anti-ZO). The antisynthetase syndrome is characterized by the formation of antisynthetase autoantibodies and the presence of one or more of the following signs: inflammatory myopathy, interstitial lung disease (ILD), arthritis, Raynaud's syndrome, fever or changes in the skin of the palms (flaking, cracking and redness), known as «mechanic hands». The prevalence of detection of antisynthetase antibodies among dermatomyositis patients is 15-20% for anti-Jo1, 5-10% for anti-PL-7, and less than 5% for anti-PL-12. In particular, anti-PL-7 and anti-PL-12 are most associated with ILD (Alfrazi N. et al., 2021). Anti-MDA5 antibodies are detected quite often, from 6.9% to 40.6% of cases, with

rapidly progressive ILD in combination with skin lesions. Anti-MDA5 antibodies are more common in the Asian population and among patients with clinically amyopathic dermatomyositis, besides their presence is associated with rapidly progressive ILD and a high mortality rate in these cohorts. Classical skin changes are associated with the presence of MDA-5 autoantibodies: palmar papules, deep ulcers with clear edges, and areas of skin necrosis (Hallowell RW, Danoff SK, 2023).

The classical MSA associated with dermatomyositis is anti-Mi-2, and its presence is associated with a good response to glucocorticoid treatment and a good prognosis (Satoh M. et al., 2017).

There are recommendations to repeat the determination of autoantibodies for all patients with signs of myositis and/or ILD, as seeing the entire spectrum of autoantibodies cannot be detected at the beginning of the disease. The frequency of detection of the main groups of autoantibodies in IIM and the clinical manifestations associated with them are shown in the table.

It is worth noting that patients with a newly established diagnosis of IIM should undergo an examination to exclude malignant neoplasms (Hallowell RW, Paik JJ, 2022). Cancer of the lungs, ovaries, mammary gland, colon, prostate gland, and cervix, as well as hematological malignancies, are most often detected. In paraneoplastic myositis, damage to the skin and muscle lesions is often severe, sometimes in the absence of other signs of connective tissue involvement, such as ILD, or may be asymptomatic in the presence of MAAs. First of all, this applies to patients who have autoantibodies with a high affinity to the paraneoplastic process, namely: anti-NXP2, anti-TIF1 $\gamma/\alpha$ . The prevalence of anti-TIF1 $\gamma/\alpha$  in dermatomyositis associated with cancer ranges from 22% to 100% (Satoh M. et al., 2017). Patients with IIM require an examination to rule out malignancy at the time of diagnosis and subsequently with a frequency of 1 time in 3 years. The scope of examinations may include tumor markers and PET/CT.

## Aim

The purpose of this study was to demonstrate a clinical case of antisynthetase syndrome, to analyze the stages of diagnosis verification, the value of laboratory markers and instrumental studies,

**Table.** The frequency of detection of the main groups of autoantibodies in IIM and the clinical manifestations associated with them

Autoantibodies	Frequency	Clinical manifestations
Anti-Jo1	20-30%	Myositis with progressive lung damage and skin rash (~50% of patients); "mechanic hands" and Raynaud's syndrome
Anti-PL7	2-5%	Myositis with severe manifestations of ILD, heliotropic rash, possible pericardial effusion.
Anti-PL12	2-5%	Isolated ILD with mild manifestations of myositis, Raynaud's syndrome
Anti-EJ	< 1%	
Anti-OJ	< 1%	Severe myopathy, less frequent Raynaud's syndrome
Anti- Ks	< 1%	Isolated ILD
Anti-ZO	< 1%	
Anti-HA	< 1%	
<b>Antibodies are associated with overlap myositis</b>		
Anti-SS-A/ Ro52/Ro60	50-70% together with anti-Jo1	Associated with Sjogren's syndrome, SLE and systemic scleroderma. Double positivity of Ro52 and Jo-1 is a high risk of paraneoplastic process.
Anti-PM/ Scl	Up to 10%	Combination of myositis and scleroderma, accompanied by muscle weakness, interstitial lung disease and skin lesions.
Anti- Ku	8-10%	Associated with systemic scleroderma, SLE; high frequency of ILD with low tolerance to GCs
Anti-U1RNP	20-30%	Signs of myositis, scleroderma and systemic lupus erythematosus; glomerulonephritis and pulmonary hypertension are possible
<b>Dermatomyositis -associated antibodies</b>		
Anti Mi-2	5-10%	DM with the appearance of a classic skin rash
Anti-MDA5	15-30%	Skin rash without muscle damage (hypomyopathic or amyopathic dermatomyositis); Sometimes rapidly progressive ILD
Anti-NXP2	10-15%	Mild and moderate muscle damage with myalgia , classic skin rash, distal extensor weakness and edema, as well as dysphagia; increased risk of paraneoplastic process
Anti-TIF1	Up to 20%	A strong connection with the paraneoplastic process; mild muscle damage with severe skin damage.

*Notes:* The table is adapted from RW Hallowell, JJ Paik, 2022. ILD – interstitial lung disease; DM - dermatomyositis; SLE - systemic lupus erythematosus; GC - glucocorticoids.

to evaluate the effectiveness of the proposed treatment, and, based on it, to conduct a literature review of the latest data on modern methods of diagnosis and treatment.

#### **Description of a clinical case**

A 70-year-old patient was admitted to the rheumatology department of the "Olexandrivska Clinical Hospital of Kyiv" in February 2023 with complaints of constant marked weakness in the muscles of the upper and lower limbs, difficulty in getting out of bed, walking, and raising the arms, pain in joints, difficulty swallowing both solid and

liquid food, dry cough and shortness of breath with minimal physical activity, a significant decrease in appetite and weight loss.

She has considered herself sick since March 2022. At that time, the patient was temporarily evacuated to another region of Ukraine due to martial law. A cough, shortness of breath, and increased body temperature gradually appeared. During the laboratory examination, an increase in markers of systemic inflammation (ESR, CRP) and AST was noted. The patient underwent a computer tomography of the chest cavity, which

revealed foci of increased density of the «ground glass opacities» type with unclear confluent contours – bilateral polysegmental pneumonia. PCR was conducted for SARS-CoV-2 and despite the negative result, the infectious disease specialist diagnosed: Coronavirus disease (COVID-19), bilateral polysegmental pneumonia. The patient was hospitalized at the place of temporary stay, and treatment was started according to the guideline, and it should be noted that without positive dynamics. Seeing the increasing signs of ILD and a drop in saturation, glucocorticoids (GCs) – methylprednisolone 500 mg IV were prescribed for five days, which led to improvement of the condition. It is recommended to continue oral methylprednisolone at a dose of 48 mg with a gradual decrease until withdrawal. In August, GCs stopped taking it. Difficulties in self-care and movement gradually arose due to weakness in the muscles of the upper and lower limbs, the patient continued to be bothered by a cough, and shortness of breath increased. In connection with the worsening of her condition, the patient was hospitalized in the rheumatology department.

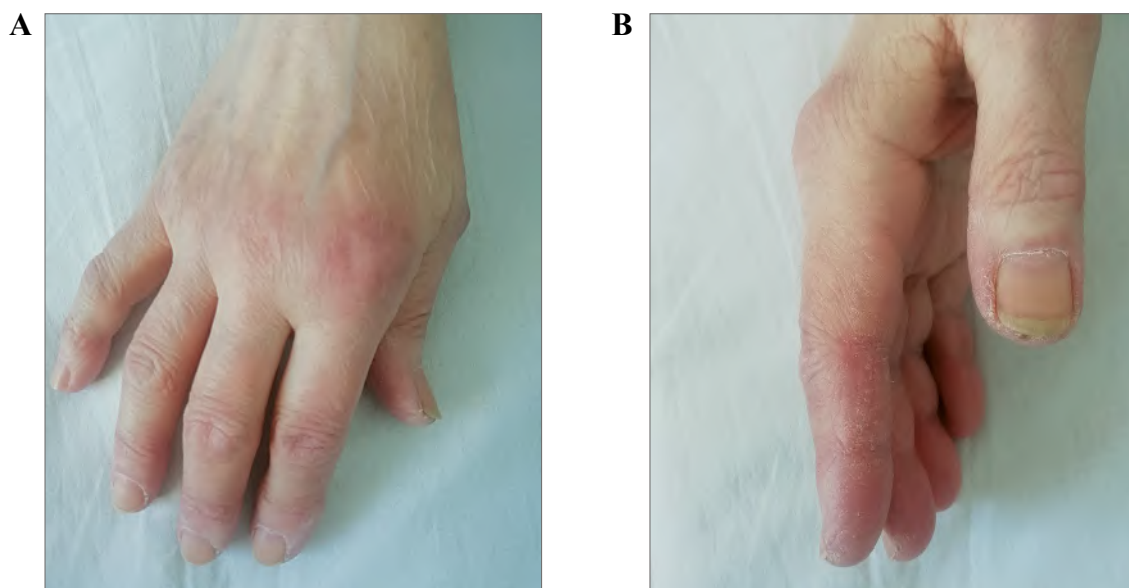
During an objective examination: the patient moves slowly, has a «duck» gait, cannot get out of bed or climb the stairs by herself, cannot keep her upper limbs raised and cannot dress. It is difficult for the patient to raise his head and turn in bed. Erythema, hyperkeratosis, peeling and cracks in the skin of the palms, purple spots over the metacarpal-phalangeal and proximal interphalangeal joints (Fig. 1), symmetrical weakness and pain during palpation in the muscles of the upper shoulder girdle and thighs, pain upon palpation and swelling of the ankle-foot and proximal interphalangeal joints of the hand. On both sides, weakened breathing, crepitation, and wheezing of various calibers over the lower lobes of the lungs were heard, and a decrease in SaO<sub>2</sub> to 91% was also determined. During the laboratory examination, an increase in acute-phase parameters was determined (ESR – 45 mm/h, CRP – 43 mg/l), mild anemia (hemoglobin – 119g/l, erythrocytes –  $3.9 \times 10^{12}/l$ , leukocytes –  $7.0 \times 10^9/l$ , platelets –  $408 \times 10^9/l$ ). Biochemical analysis revealed an increase in the activity of muscle enzymes in blood serum: CPK – 1800 U/l, AST – 175 U/ml, ALT – 181 U/ml, LDH – 570 U/l; other parameters are within normal limits:

creatinine – 67 mkmol /l, urea – 7.8 mkmol/l, uric acid – 245 mkmol/l, bilirubin – 11.5 mkmol/l. General analysis of urine was without pathology. The QuantiFERON test was negative. There were conducted studies: ECG, ultrasound of abdominal organs and kidneys, pelvis, mammography – without clinically significant changes; on echocardiography – pulmonary hypertension of the II degrees, relative insufficiency of the tricuspid valve. The immunological examination revealed positive SS-A/Ro52 IgG antibodies, histidyl-tRNA-synthetase (Jo1) IgG antibodies, threonyl-tRNA-synthetase (PL-7) IgG antibodies, alanine- tRNA-synthetase (PL-12) IgG antibodies, Ring-dependent-synthetase (Ro-52) of IgG antibodies; the rest of the antibodies (Mi-2 IgG antibodies, Ku-IgG antibodies, complex PM- Sc IgG antibodies ) were negative.

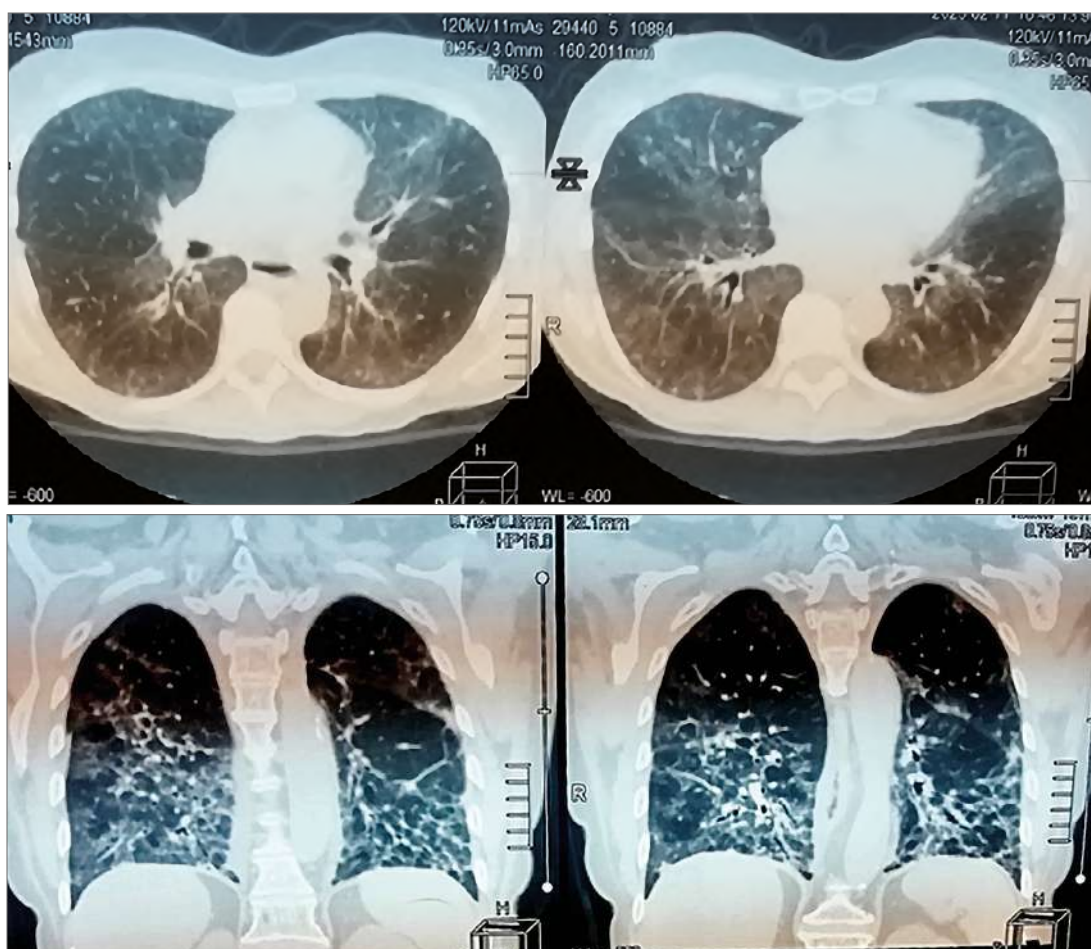
Computer tomography of the chest revealed signs of bilateral ILD: the parenchyma of both lungs was unevenly compacted in the «ground glass opacities» type almost along its entire length with the presence of compaction of the interlobular and intralobular membranes, reticular changes and areas of subpleural linear consolidation, the changes were more noticeable in the lower lung fields (Fig. 2).

MRI of muscles and biopsy to detect inflammation in muscle tissue and electroneuromyography to confirm primary muscle damage (Lundberg IE et al., 2016) are essential and recommended for the diagnosis of IIM. In the given clinical case, these examinations were not performed because, according to the EULAR/ACR 2017 classification criteria, the probability of IIM was  $\geq 100\%$ .

The conducted studies (ultrasound of the abdominal cavity and kidneys, pelvis, mammography, and computer tomography of the chest) made it possible to rule out paraneoplastic syndrome at the time of examination. The diagnosis was established based on the presence of ILD, myositis, arthritis, characteristic skin changes and of specific anti-synthetase antibodies: Antisynthetase syndrome, anti-SS-A/Ro52, Jo1, PL-7, PL-12 positivity, chronic course, active phase, III degrees of activity, with damage to the proximal group of muscles of the upper and lower limbs, neck, pharynx (dysphagia), skin (Gottron's sign ), joints (arthritis, arthralgia), lungs (interstitial lung disease – fibrosing alveolitis).



**Fig. 1.** Gottron's sign: purple spots over the calcaneal-phalangeal and proximal interphalangeal joints (A); changes in the skin of the palms: erythema, hyperkeratosis, peeling, cracks (B) – «mechanic's hand»



**Fig. 2.** CT image of the patient's lung. Changes according to the type of «ground glass opacities» with signs of cellularity in the basal and subpleural areas of both lungs with the presence of compaction of interlobular and intralobular membranes, reticular changes and areas of subpleural linear consolidation, changes are more noticeable in the lower lung fields.

The patient was treated with methylprednisolone at a dose of 1000 mg for three consecutive days in combination with cyclophosphane at the rate of 0.6 g/m<sup>2</sup> (900 mg) once by intravenous administration due to severe dysphagia. As a result of the treatment, the improvement of the condition was noted: reduction of muscle weakness, improvement of muscle function, the gradual restoration of self-care, reduction of dysphagia phenomena, the disappearance of pain and swelling of joints, reduction of cough and shortness of breath, an increase in tolerance to physical exertion.

During the control laboratory examination, positive dynamics were also observed: a decrease in acute-phase indicators (ESR – 20 mm/h, CRP – 20 mg/l), a significant decrease in the activity of muscle enzymes (CPK – 105 U/l; LDH – 400 U/l), normalization of AST – 32 U/l, ALT – 29 U/l, as well as increase and stabilization of SaO<sub>2</sub> within 98%. It is recommended to continue by GCs therapy (36 mg of methylprednisolone per os) for three weeks, then gradually reducing the dose to the minimum possible depending on the clinical situation; continue cyclophosphamide intravenous administration once every four weeks during six months; conduct regular monitoring of the effectiveness of the prescribed therapy and possible side effects every 3-4 weeks; in the future, the transition to oral immunosuppressive therapy is planned.

### Discussion

Management of patients with IIM is a complex task. First of all, difficulties arise in diagnosis, because sometimes the manifestation of the disease from non-specific symptoms postpones the consultation of a rheumatologist. When establishing a diagnosis, it is important to use classification criteria. The first classification criteria of IIM were introduced in 1975 by Bohan and Peter (Bohan A., Peter JB, 1975), which subsequently underwent modification based on new diagnostic possibilities and obtaining information about the disease. Current EULAR/ACR criteria for adult and juvenile IIM and their main subgroups were published in 2017 (Lundberg IE et al., 2017). An online calculator for evaluating clinical manifestations, accompanying laboratory and instrumental data, and muscle biopsy results are convenient, which was also used in the above clinical case ([http://](http://www.imm.ki.se/biostatistics/calculators/iim/)

[www.imm.ki.se/biostatistics/calculators/iim/](http://www.imm.ki.se/biostatistics/calculators/iim/)).

The conducted literature search covers articles for the period from 2013 to 2023 using scientometric databases MEDLINE/ PubMed, ScienceDirect, Wiley Online Library, and Scopus. Search requests included keywords: «antisynthetase syndrome», «autoantibodies», «interstitial lung disease», and «idiopathic inflammatory myopathy». The final analysis included two hundred six pre-selected sources and thirteen review articles, the full text of which is available in English. Also was used the classification criteria of IIM published for the first time (Bohan A., Peter JB, 1975) and the modern EULAR/ACR criteria for adult and juvenile IIM and their main subgroups published in 2017 (Lundberg IE et al., 2017).

The presented clinical case and the conducted literature analysis demonstrate the possible debut of the disease with ILD. It is worth remembering that the cause of ILD can be systemic diseases of the connective tissue, particularly IIM. Lung damage in patients with the antisynthetase syndrome is registered in 70%-90% of cases. In addition, it is the main cause of mortality, which is due to the weakness of the respiratory muscles, autoimmune inflammation of the lung tissue, and the development of aspiration pneumonia against the background of dysphagia (Huang K., Aggarwal R., 2020). The age of onset of the disease is over 60 years, and a malignant neoplasm is also an independent predictor of unfavorable prognosis (Chatterjee S., Prayson R., Farver C., 2013).

According to the literature, the detection of MSAs and MAAs is associated with certain clinical manifestations, the nature and degree of severity of damage to internal organs, and the prognosis of the disease (see table). MSAs targets mainly the cytoplasmic aminoacyl-tRNA synthetase enzymes, the Mi-2 nuclear helicase protein, and the signal recognition particle of the cytoplasmic complex. The latter is associated with immune-mediated necrotic myopathy, while anti-Mi2 is more common in dermatomyositis. Their presence is associated with an acute onset of the disease and a lower mortality rate. Jo-1 antisynthetase antibodies may predict mild to moderate muscle damage with progressive lung damage and characteristic skin involvement, such as mechanic's hand and Raynaud's syndrome. The detection frequency of anti-Jo-1 antibodies

in the case of IIM reaches 20-30%. In the case of antisynthetase syndrome approaches up to 75% and it is a strong predictor of developing ILD (70-90%) (Marin FL, Sampaio HP, 2019). Detection of accompanying antisynthetase antibodies, namely anti-PL-7 and anti-PL-12, significantly worsens the prognosis of ILD. It is also worth noting that in patients with the antisynthetase syndrome, the appearance of anti-Ro/SSA antibodies is associated with a severe course. Cytoplasmic antigen Ro/SSA has two polypeptide components: Ro52 and Ro60, autoantibodies to both of which are usually observed in systemic connective tissue diseases (Basuita M. et al., 2022).

Among MAAs, anti-Ro52 antibodies have attracted a lot of attention due to their importance for prognosis and defining therapeutic strategies. The Ro52 is biochemically and immunologically distinct from Ro60 and is considered more immunogenic. The Anti-Ro52 is present in approximately 30% of cases of IIM and has a strong association with antisynthetase antibodies. It is found in 40–72% of patients with antisynthetase syndrome and may not be accompanied by clinical signs of Sjogren's syndrome. It is known that patients with detected anti-PL-7, anti-PL-12, and anti-EJ have more often anti-Ro52, compared to anti-Jo-1-positive patients (Alenzi F.M., 2020). The presence of anti-Ro52 in patients with the antisynthetase syndrome is associated with more severe ILD, relapses, and refractory disease; however, the presence of this autoantibody was not associated with the degree of myositis, arthritis, or skin manifestations. Acute respiratory failure and the development of pulmonary fibrosis were more often observed in antisynthetase syndrome with anti-Ro52, especially in patients positive for anti-PL-7 (Huang K., Aggarwal R., 2020).

The presence of anti-Ku antibodies is more often associated with overlapping conditions, for example, overlap myositis with systemic scleroderma. The diagnosis of overlap myositis with systemic scleroderma is confirmed in the presence of appropriate clinical signs and anti-Pm/Scl.

Clinical recommendations for treating IIM include the appointment of GCs and immunosuppressive drugs (Glaubitz S., Zeng R., Schmidt J., 2020). Remission induction therapy consists of the appointment of high doses of GCs,

that is the use of pulse therapy, oral administration of 0.5-1 mg/kg of body weight with prednisolone, followed by a slight decrease to a maintenance dose (5-10 mg) and an attempt to cancel GCs over the next six months. Azathioprine 2-3 mg/kg/day or methotrexate 7.5-25 mg/week is used as basic first-line therapy. In case of a combination of IIM and ILD, GCs therapy along with mofetil mycophenolate 1-3 g/day, or tacrolimus 0.1-0.2 mg/kg/day, or cyclophosphamide is recommended. In patients resistant to treatment, intravenous immunoglobulin or rituximab is used. The effectiveness of the therapy is recommended to be evaluated based on the scale of clinical response to treatment in dermatomyositis and polymyositis in adults ACR/EULAR 2016, which is available in the form of an online calculator [https://www.niehs.nih.gov/research/resources/imacs/response\\_criteria/adult.html](https://www.niehs.nih.gov/research/resources/imacs/response_criteria/adult.html)

### Conclusions

The antisynthetase syndrome is a rare rheumatological disease that belongs to IIM and is the so-called overlap myositis. ILD is one of the clinical manifestations of this syndrome. Misdiagnosis, as in the above clinical case, due to epidemiological vigilance regarding Covid-19, can lead to negative consequences because lung damage is the main cause of mortality in this group of patients. An example of an atypical debut of the disease presented with gradual worsening of pulmonary symptoms, progressive muscle damage, dysphagia, skin and joint involvement is presented. An error in the diagnosis during the initial contact of the doctor with the patient led to the progression of lung damage and deterioration of the patient's condition. This fact again emphasizes the need for a multidisciplinary team with the participation of pulmonologists, rheumatologists, and infectious disease specialists at the stage of verification of the final diagnosis. For differential diagnosis, an immunological study is essential because it determines the nature of the disease and predicts the severity of damage to internal organs. It is important to remember that the presence of specific antisynthetase antibodies (anti-PL-7, anti-PL-12) in combination with anti-Ro 52 affects the course, is associated with greater severity of ILD, worsens the prognosis, and requires intensification of therapy. At the same time, achieving clinical and

laboratory remission requires continued treatment under the supervision of a rheumatologist.

### Financing

This study did not receive external funding.

### Conflict of interests

When writing this article, the authors had no conflict of interest in any form.

### Consent to publish

The patient's consent for publication was obtained. In this article, all personal data of the patient are hidden.

### ORCID ID and author contribution

[0009-0000-3751-787X](https://orcid.org/0009-0000-3751-787X) (A, B, D) Fiialkovska Olesia

[0000-0003-3687-6218](https://orcid.org/0000-0003-3687-6218) (A, B, D, E, F) Tetiana Karasevska

[0000-0002-1487-1902](https://orcid.org/0000-0002-1487-1902) (B, E, F) Oleksiy I. Ivashkivskyi

[0000-0001-9719-323X](https://orcid.org/0000-0001-9719-323X) (A, B, E, F) Ruslana A. Potomka

[0000-0002-1630-8793](https://orcid.org/0000-0002-1630-8793) (A, B, E, F) Hanna L. Novytska

[0000-0002-7500-8520](https://orcid.org/0000-0002-7500-8520) (A, B, D, E, F) Marta B. Dzhus

A – Conception and design of the work, B – Data collection and analysis, C – Responsibility for statistical analysis, D – Writing of the article, E – Critical review, F – Final approval of the article

## LITERATURE

Alenzi FM (2020). Myositis Specific Autoantibodies: A Clinical Perspective. *Open access rheumatology: research and reviews*, 12, 9–14. <https://doi.org/10.2147/OARRR.S231195>

Alfrazi, N., Mazahir, U., Chaudhri, M., & Miskoff, J. (2021). Anti-synthetase syndrome : a rare and challenging diagnosis for bilateral ground-glass opacities – a case report with literature review. *BMC pulmonary medicine*, 21 (1), 11. <https://doi.org/10.1186/s12890-020-01388-0>

Basuita M, Fidler LM. Myositis Antibodies and Interstitial Lung Disease. *J Appl Lab Med*. 2022 Jan 5;7(1):240-258. doi: 10.1093/jalm/jfab108. PMID: 34996093. (Basuita M. et al., 2022)

Bohan A, Peter JB. Polymyositis and dermatomyositis (first of two parts). *N Engl J Med* 1975; 292:344–7. 8. Bohan A, Peter JB. Polymyositis and dermatomyositis (second of two parts). *N Engl J Med* 1975; 292:403–7

Brunasso, AM, Aberer, W., & Massone, C. (2014). New onset of dermatomyositis / polymyositis during anti -TNF- $\alpha$  therapies: a systematic literature review. *TheScientificWorldJournal*, 2014, 179180. <https://doi.org/10.1155/2014/179180>

Cavagna, L., Trallero-Araguás, E., Meloni, F., Cavazzana, I., Rojas-Serrano, J., Feist, E., Zanframundo, G., Morandi, V., Meyer, A., Pereira yes Silva, JA, Matos Costa, CJ, Molberg, O., Andersson, H., Codullo, V., Mosca, M., Barsotti, S., Neri, R., Scirè, C., Govoni, M., Furini, F., ... Gonzalez-Gay, MA (2019). Influence of Antisynthetase Antibodies \_ Specificities he Antisynthetase Syndrome Clinical Spectrum Time Course. *Journal of clinical medicine*, 8 (11), 2013. <https://doi.org/10.3390/jcm8112013> (Cavagna L. and others, 2013);

Chatterjee, S., Prayson, R., & Farver, C. (2013). Antisynthetase syndrome: not just an inflammatory myopathy. *Cleveland Clinic journal of medicine*, 80 (10), 655–666. <https://doi.org/10.3949/ccjm.80a.12171>

Glaubitz, S., Zeng, R., & Schmidt, J. (2020). New insights into the treatment of myositis. *Therapeutic advances in musculoskeletal disease*, 12, 1759720X19886494. <https://doi.org/10.1177/1759720X19886494>

Hallowell, RW, & Danoff, SK (2023). Diagnosis and Management of Myositis-Associated Lung Disease. *Chest*, S0012-3692(23)00162-9. Advance online publication. <https://doi.org/10.1016/j.chest.2023.01.031>

Hallowell, RW, & Paik, JJ (2022). Myositis-associated interstitial lung disease: a comprehensive approach that diagnosis and management. *Clinical and experimental rheumatology*, 40(2), 373–383. <https://doi.org/10.55563/clinexprheumatol/brv11v>

Huang, K., & Aggarwal, R. (2020). Antisynthetase syndrome: A distinct disease spectrum. *Journal of scleroderma and related disorders*, 5 (3), 178–191. <https://doi.org/10.1177/2397198320902667>

Lundberg, IE, Miller, FW, Tjárnlund, A., & Bottai, M. (2016). Diagnosis and classification of idiopathic inflammatory myopathies. *Journal of internal medicine*, 280(1), 39–51. <https://doi.org/10.1111/joim.12524>

Lundberg, IE, Tjárnlund, A., Bottai, M., Werth, VP, Pilkington, C., Visser, M., Alfredsson, L., Amato, AA, Barohn, RJ, Liang, MH, Singh, JA, Aggarwal, R., Arnardottir, S., Chinoy, H., Cooper, RG, Dankó, K., Dimachkie, MM, Feldman, BM, Torre, IG, Gordon, P. International Myositis Classification Criteria Project consortium, The Euromyositis register and The Juvenile Dermatomyositis Cohort Biomarker Study and Repository (JDRG) (UK and Ireland) (2017). 2017 European League Against Rheumatism / American College of Rheumatology classification criteria for adult and juvenile idiopathic inflammatory myopathies and their major subgroups. *Annals of the rheumatic diseases*, 76(12), 1955–1964. <https://doi.org/10.1136/annrheumdis-2017-211468>

Marin, FL, & Sampaio, HP (2019). Antisynthetase Syndrome and Autoantibodies: A Literature Review and Report of 4 Cases. *The American journal of case reports*, 20, 1094–1103. <https://doi.org/10.12659/AJCR.916178>



Satoh, M., Tanaka, S., Ceribelli, A., Calise, SJ, & Chan, EK (2017). A Comprehensive Overview of Myositis-Specific Antibodies: New and Old Biomarkers in Idiopathic Inflammatory Myopathy. *Clinical reviews in allergy & immunology*, 52(1), 1–19. <https://doi.org/10.1007/s12016-015-8510-y>

## Антисинтетазний синдром: опис клінічного випадку та огляд літератури

Фіалковська Олеся<sup>1</sup>, Карасевська Тетяна<sup>2</sup>, Івашківський Олексій<sup>3</sup>, Потьомка Руслана<sup>3</sup>, Новицька Ганна<sup>3</sup>, Джус Марта<sup>2,3</sup>

<sup>1</sup>Студентка Національного медичного університету імені О.О.Богомольця, м. Київ, Україна.

<sup>2</sup>Кафедра внутрішньої медицини №2, Національний медичний університет імені О.О. Богомольця, м.Київ, Україна

<sup>3</sup>Комунальне некомерційне підприємство «Олександрівська клінічна лікарня м.Києва», Україна

### Address for correspondence:

Fialkowska Olesia

E-mail: [fialkowska.olesia@gmail.com](mailto:fialkowska.olesia@gmail.com)

**Анотація:** антисинтетазний синдром – це рідкісне аутоімунне захворювання, яке характеризується наявністю інтерстиціального захворювання легень, неерозивного артриту, міозиту, хвороби Рейно та/або «руки механіка» при виявленні аутоантитіл спрямованих проти аміноацил-тРНК-синтетаз. Антисинтетазний синдром відноситься до групи ідіопатичних запальних міопатій і так званого оверлап-міозитом. В статті наведені останні літературні дані щодо діагностичного значення міозит-специфічних аутоантитіл на підставі проведеного літературного огляду за період з 2013 по 2023 роки, використовуючи наукометричні бази MEDLINE/PubMed, Wiley Online Library та Scopus. Дані літератури свідчать про те, що окремі міозит-специфічні аутоантитіла, а саме анти-PL-7, анти-PL-12, можуть впливати на ризик розвитку інтерстиціального захворювання легень, визначають перебіг та прогноз захворювання. Наявність інтерстиціального захворювання легень у пацієнтів з міозитом корелює з підвищенням захворюваності та смертності. В статті описано клінічний випадок дебюту антисинтетазного синдрому з інтерстиціальним захворюванням легень, який хибно діагностували як коронавірусну хворобу. Стан хворої покращився тільки на тлі застосування глюкокортикоїдів, прийом яких з часом пацієнтка припинила, що призвело до погіршення легеневої симптоматики, появи нових клінічних ознак ураження суглобів, шкіри, прогресивного зниження функції м'язів, дисфагії. Після обстеження в ревматологічному відділенні, на підставі наявності у хворої інтерстиціального захворювання легень – фіброзуючого альвеоліту, яке підтверджено при комп'ютерній томографії, міозиту, артриту, характерних змін шкіри, наявності антинуклеарних антитіл, анти SS-A/Ro52, специфічних антисинтетазних антитіл (Jo-1, PL-7, PL-12) встановлено діагноз антисинтетазний синдром. Детальне лабораторне та інструментальне дослідження дозволили на момент огляду виключити паранеопластичний процес. Призначене лікування включало пульс-терапію метилпреднізолоном та циклофосфан, що призвело до покращення стану хворої. Проведена робота підкреслює потребу у міждисциплінарній взаємодії пульмонологів, ревматологів, інфекціоністів на етапі верифікації остаточного діагнозу та призначення терапії. Досягнення клініко-лабораторної ремісії захворювання вимагає тривалого спостереження ревматолога.

**Ключові слова:** аутоантитіла, ідіопатичні запальні міопатії, інтерстиціальне захворювання легень.



Copyright: © 2022 by the authors; licensee USMYJ, Kyiv, Ukraine.

This article is an **open access** article distributed under the terms and conditions of the Creative Commons Attribution License (<http://creativecommons.org/licenses/by/4.0/>)