

## MEDICINE / МЕДИЦИНА

UDC: 616.45-006.55-06-072.5

[https://doi.org/10.32345/USMYJ.3\(141\).2023.14-18](https://doi.org/10.32345/USMYJ.3(141).2023.14-18)

Received: April 11, 2023

Accepted: July 21, 2023

**Bilateral adrenal pathology:  
Conn syndrome and autonomous cortisol secretion**Hradova Diana<sup>1</sup>, Yuzvenko Violetta<sup>2</sup><sup>1</sup>Student, Bogomolets National Medical University, Kyiv, Ukraine<sup>2</sup>Ukrainian Scientific and Practical Center of Endocrine Surgery, Transplantation of Endocrine Organs and Tissues of MoH of Ukraine, Kyiv, Ukraine**Adress for correspondence:**

Hradova Diana

E-mail: [gradovadiana2@gmail.com](mailto:gradovadiana2@gmail.com)

*Abstract:* this case report presents the route of a patient with bilateral adrenal pathology and severe complaints, who where admitted to the Ukrainian Scientific and Practical Center for Endocrine Surgery, Transplantation of Endocrine Organs and Tissues of MoH of Ukraine as scheduled. The selective blood sampling from adrenal veins, which was performed at the Center, in patient with bilateral adrenal pathology, is analyzed. This method is the gold standard of diagnosis, which allows to choose the optimal method of treatment for such patients.

**Keywords:** [adrenalectomy](#), [adrenocortical adenoma](#), [hydrocortisone](#), [hyperaldosteronism](#), [hyperplasia](#), [hypertension](#).

**Introduction**

Adenoma of the adrenal glands is one of the main (50-60%) causes of primary hyperaldosteronism, while primary hyperaldosteronism is the most common cause of secondary (symptomatic) arterial hypertension, accounting for 5-10% of cases (with a tendency to increase). There is a precise correlation between the severity of arterial hypertension and the regularity of detection of primary hyperaldosteronism: in the case of refractory arterial hypertension, it accounts for 17-23% (Grasso, Scaroni, & Ceccato, 2018). Practicing physicians should pay attention to arterial hypertension, especially in young individuals, regarding differential diagnosis. Endocrine arterial hypertension should be diagnosed as quickly as possible at the first stages of visiting doctors of

different specialties (cardiologist, family doctor, therapist) to provide a better future for the patient (Shuper, Trefanenko & Reva, 2022).

It should be noted that adrenal adenoma, as well as the tumor form of primary hyperaldosteronism, is most often characteristic of working-age people (30-60 years old), and the average age for diagnosis is 57 years old, with women being twice as likely to develop the pathology as men. Adrenal adenomas are usually benign tumors, but in 0,7-1,2% of cases, they undergo malignancy, with the malignant form characterized by rapid growth accompanied by metastasis (Deandreis, Schlumberger & Baudin, 2011).

Adrenal adenoma and primary hyperaldosteronism are pathologies that, in addition to arterial hypertension, are characterized by

dyslipidemia, obesity (in the abdominal type), and changes in carbohydrate metabolism in the form of impaired glucose tolerance, which is a risk factor for the development of adverse cardiovascular events and a worsening of the prognosis of concomitant diseases (Zubryk, 2020).

Complex highly specialized treatment is necessary for these patients to improve their quality of life and prevent the progression of complications (Liashuk et al., 2021; Tovkai O. A. et al., 2022).

### **Aim**

This study aims to investigate and analyze the diagnostic and therapeutic interventions performed in the case of a female patient with bilateral adrenal pathology and manifestations of primary hyperaldosteronism and autonomous cortisol production.

### **Clinical case description**

Patient I., 38 years old, was admitted to the Endocrinology department of the Ukrainian Scientific and Practical Center for Endocrine Surgery, Transplantation of Endocrine Organs and Tissues of MoH of Ukraine with the diagnosis of Adenoma of the left adrenal gland, nodular hyperplasia of the right adrenal gland, primary hyperaldosteronism. Secondary arterial hypertension of grade II, 2nd stage, heart failure stage 1. Dyslipidemia. Impaired glucose tolerance. Class 1 obesity. The purpose of hospitalization was to perform selective blood sampling from the adrenal gland veins to refine the diagnosis. According to the CT data from 2020: bilateral nodular hyperplasia of the adrenal glands with a dominant left adrenal gland (adenoma).

At admission, the patient complained of high blood pressure, which was poorly controlled by taking three drugs, including Spironolactone 100 mg/day, an increase in blood glucose levels – documented impaired glucose tolerance (taking Metformin 1000 mg/day), and increasing muscle weakness.

Objectively, at the time of examination by the endocrinologist, the patient's condition is relatively satisfactory. The skin is of normal color and moisture, there are no phenotypic signs of Cushing's syndrome, and the menstrual cycle is not disturbed. The blood pressure on the right is 160/90 mmHg. Patient's pulse rate is 64 beats per minute, respiratory rate is 16 breaths per minute.

Body mass index (BMI) is 32 kg/m<sup>2</sup> (height 165 cm, weight 88 kg). Peripheral edema is absent. The thyroid gland is not enlarged and is diffuse upon palpation.

From the medical history, it is known that the patient has had high blood pressure since 2013, during and after the second childbirth. Elevated levels of prolactin and DHEA-sulfate in the blood were detected during a gynecological examination for galactorrhea. Cabergoline was taken for 2 months, and short-term dexamethasone treatment was prescribed for increased androgen levels. Stable antihypertensive therapy has been ongoing since 2015, and medication is taken regularly. The patient has a history of acute pyelonephritis. Initially, according to ultrasound data, urolithiasis was confirmed, but recent ultrasound (2020) and CT scans have confirmed medullary calcinosis. There is no impairment of kidney function. Primary hyperparathyroidism has been excluded. CT monitoring has been conducted once a year from 2017 to 2020, and the size of the left adrenal gland formation has not changed.

The patient was referred for a CT scan of the abdominal organs, which revealed an adenoma on the left adrenal gland (medial pedicle), nodular hyperplasia of the right adrenal gland, and nephrocalcinosis. Additional functional tests were conducted, including an electrocardiogram (ECG) and a chest x-ray, which were normal. Laboratory tests showed that the patient's complete blood count and urine analysis were within normal limits. However, the patient had dyslipidemia, with a total cholesterol level of 7,84 mmol/L (normal < 5,2 mmol/L), triglycerides of 1,07 mmol/L (normal < 1,7 mmol/L), low-density lipoprotein cholesterol of 5,59 mmol/L (normal < 3 mmol/L), and a venous blood glucose level of 6,35 mmol/L (normal range 3,3-5,5 mmol/L).

Before admission, the patient had an ACTH level of 5,55 pg/mL (normal range 6,0-58,0 pg/mL), a morning cortisol level of 469 nmol/L (normal range 138-690 nmol/L), and a nighttime dexamethasone suppression test result of 48,8 nmol/L. The patient's urine analysis was normal, and tests for HCV, HbsAg, and RW were negative. Coagulation tests showed an activated partial thromboplastin time (aPTT) of 28,5 seconds

(normal range 24-34 seconds), a prothrombin time (PT) of 13,6 seconds (normal range 14-18 seconds), an international normalized ratio (INR) of 1,1 (normal range 0,85-1,15), and a fibrinogen level of 292 mg/dL (normal range 52-129 mg/dL).

The patient was transferred to the interventional cardiology and radiology department for selective blood sampling from the adrenal glands veins (tabl. 1).

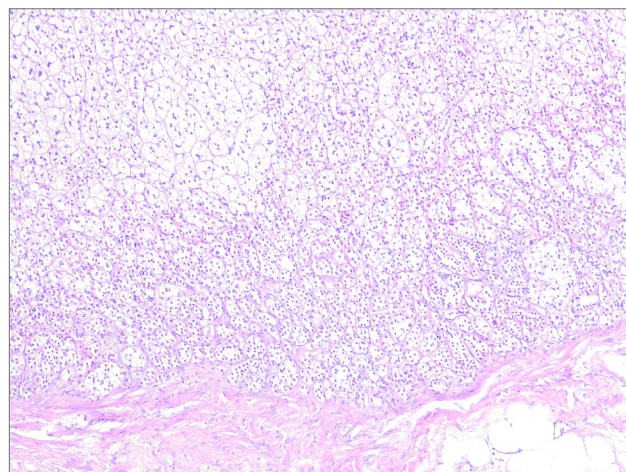
A lateralization index  $> 2$  indicates lateralized (left-sided) hyperproduction of aldosterone in combination with cortisol.

After performing selective blood sampling and evaluating the results, consultation with an endocrine surgeon in a highly specialized center is recommended based on CT data and results of selective blood sampling from adrenal veins to determine the need for planned surgical intervention, specifically left adrenalectomy.

After consultation with an endocrine surgeon, the diagnosis was established as Left adrenal gland tumor. Primary hyperaldosteronism. Autonomous secretion of cortisol. Surgical treatment was recommended specifically laparoscopic left adrenalectomy.

One week later, the patient was admitted to the surgical department of the Ukrainian Scientific and Practical Center of Endocrine Surgery, Transplantation of Endocrine Organs and Tissues of MoH of Ukraine for planned surgical treatment. Under conditions of combined general anesthesia, laparoscopic left adrenalectomy was performed on the patient. Intraoperative blood loss was 50 ml.

According to the results of the pathological study, diffuse hyperplasia of the cortical layer of the left adrenal gland (predominantly due to the reticular and fascicular zones) was detected.



**Figure №1:** Reticular and fascicular zones of the cortex layer of the left adrenal gland

The results of the tests after the surgery: cortisol in the blood - in the morning (9:00): 11,98 mcg/dL (normal range 4,30-22,40 mcg/dL); potassium in the blood – 4,23 mmol/L (normal range 3,5-5,1 mmol/L).

On the next day after the operation, the patient's blood pressure was 110/70 mmHg. The pulse rate was 84 beats per minute. The temperature was 36,8°C. The patient's general condition was satisfactory with no complaints. The skin was clean. Vesicular breathing was heard with no wheezing. Heart sounds were audible and rhythmic. The abdomen was not distended, symmetrical, participating in the act of respiration, and soft and painless on palpation. There were no signs of peritoneal irritation. Bowel sounds were audible and flatulence was present. The surgical wound edges showed no signs of inflammation.

Four days after the surgical intervention, the patient was recommended for discharge and outpatient follow-up with further recommendations.

**Table 1.** Selective blood sampling results from the adrenal veins

Parametr:	Right adrenal gland	Left adrenal gland	Inferior vena cava
Aldosterone	153,6 pg/mL	394,4 pg/mL	154,3 pg/mL
Cortisol	10,76 mcg/dL	46,3 mcg/dL	12,14 mcg/dL
A/C ratio	15,3	8,5	
Selectivity index sin: 3,8			
Lateralization index (aldosterone sin/aldosterone dex = 2,57)			

The postoperative period was uneventful. The surgical wound healed by primary intention. The patient was discharged in satisfactory condition with the following recommendations: observation by a surgeon, endocrinologist, and cardiologist at the place of residence, monitoring of blood pressure, and monitoring of cortisol levels in daily urine after 2 weeks and 2 months. In case of acute adrenal insufficiency (blood pressure decrease to 90-80/50-40 mmHg), hydrocortisone solution 150-200-250 mg intravenously or hydrocortisone solution 125 mg intramuscularly under blood pressure and pulse control should be administered.

Ten days later, the patient returned to the surgical department to have the postoperative stitches removed. The patient's general condition was satisfactory, and the blood pressure during the examination was 120/80 mmHg. There were no signs of acute adrenal insufficiency. One month after surgical treatment, upon re-examination, the patient had no complaints, blood pressure was within the range of 120/80 mmHg to 145/90 mmHg, and blood potassium level was 3,9 mmol/L.

### Results

Despite the difficult situation in our country, all patients should receive highly specialized medical care. This clinical case highlights the algorithm and route of a patient with bilateral adrenal pathology. Selective blood sampling from the adrenal veins is the most reliable method of visualization to determine whether there is unilateral or bilateral adrenal adenoma as a source of primary aldosteronism. After the diagnosis, together with endocrine surgeons, we decide on the issue of surgical intervention. After adrenalectomy, we recommend continuous monitoring by an endocrinologist.

### Discussion and conclusions

Adrenal gland adenoma, in particular hormone-producing adenoma (Conn syndrome and autonomous cortisol secretion), occurs mainly in people of working age. Taking into account all the diagnostic and treatment procedures for bilateral pathology, we can assure the absolute expediency of using the method of selective blood sampling from the adrenal veins, which makes it possible to reliably carry out a differential diagnosis between hyperplasia of both adrenal glands and their hormone-active or non-hormonal-active neoplasms.

According to the invasive study (selective blood sampling), the necessity of performing a surgical procedure, laparoscopic left adrenalectomy, was established. As a result, there was a significant improvement in the patient's condition, the quality of life was improved, and the patient gained the ability to live without previous complaints caused by adrenal pathology.

### Financing

This study did not receive external funding.

### Conflict of interest

The authors declare that there is no conflict of interest and no financial interest in the preparation of this article.

### Consent for publication

The authors obtained consent to publish this work from a patient relevant to this manuscript.

### ORCID ID and author contribution

[0000-0002-5562-4406](https://orcid.org/0000-0002-5562-4406) (A, B, C, E, F) Violetta Yuzvenko

[0000-0001-9659-5747](https://orcid.org/0000-0001-9659-5747) (C, D) Diana Hradova

A – Research concept and design, B – Collection and/or assembly of data, C – Data analysis and interpretation, D – Writing the article, E – Critical revision of the article, F – Final approval of article

## REFERENCES

- Deandreis, D., Leboulleux, S., Caramella, C., Schlumberger, M., & Baudin, E. (2011). FDG PET in the management of patients with adrenal masses and adrenocortical carcinoma. *Hormones and Cancer*, 2, 354-362.
- Grasso, M., Boscaro, M., Scaroni, C., & Ceccato, F. (2018). Secondary arterial hypertension: from routine clinical practice to evidence in patients with adrenal tumor. *High Blood Pressure & Cardiovascular Prevention*, 25, 345-354.
- Liashuk P.M., Liashuk R.P. (2021). Arterial hypertension in rare endocrine pathology: practical observation. <https://doi.org/10.24061/2413-0737.XXV.4.100.2021.18>
- Shuper V. O., Shuper S. V., Trefanenko I. V., Shumko H. I., Reva T. V. (2022). Pharmacotherapeutic Features of the Management of Patients with Secondary Arterial Hypertension of Endocrine Genesis. <https://doi.org/10.26693/jmbs07.04.122>

Tovkai O. A., Tretyak O. E., Kuts V. V. (2022). Algorithm for the diagnosis of subclinical hypercortisolemia in patients with adrenal incidentalomas and their implementation in MS Excel environment. *Clinical Endocrinology and Endocrine Surgery*, (1), 31-41. <http://doi.org/10.30978/CEES-2022-1-31>

Zubryk, I. V. (2020). Diagnosis and selection of treatment tactic in patients with primary aldosteronism. Doctoral dissertation, Zaporizhzhia State Medical University. [http://dspace.zsmu.edu.ua/bitstream/123456789/15794/1/200207\\_dis\\_Zubryk.pdf](http://dspace.zsmu.edu.ua/bitstream/123456789/15794/1/200207_dis_Zubryk.pdf)

## Двостороння патологія наднирників: синдром Кона та автономна продукція кортизолу

Градова Діана<sup>1</sup>, Юзвенко Віолетта<sup>2</sup>

<sup>1</sup>Студентка, Національний медичний університет імені О.О. Богомольця, м. Київ, Україна.

<sup>2</sup>Український науково-практичний центр ендокринної хірургії,  
трансплантації ендокринних органів і тканин МОЗ України, м. Київ.

### Address for correspondence:

Hradova Diana

E-mail: [gradovadiana2@gmail.com](mailto:gradovadiana2@gmail.com)

*Анотація:* даний клінічний випадок описує маршрут пацієнтки з двосторонньою патологією наднирників, яка поступила планово в клініку з вираженими скаргами. Аналізується проведення селективного забору крові з наднирникових вен, який виконано в Українському науково-практичному центрі ендокринної хірургії, трансплантації ендокринних органів і тканин МОЗ України м. Києва у пацієнтів з двостороннім ураженням наднирників. Цей метод являється золотим стандартом діагностики який дозволяє в майбутньому вибрати оптимальний метод лікування даних пацієнтів.

**Ключові слова:** аденома наднирника, адреналектомія, артеріальна гіпертензія, гіперплазія, кортизол, первинний гіперальдостеронізм.



Copyright: © 2022 by the authors;  
licensee USMYJ, Kyiv, Ukraine.

This article is an **open access** article distributed under the terms and conditions of the Creative Commons Attribution License (<http://creativecommons.org/licenses/by/4.0/>)