

DOI: 10.31393/reports-vnmedical-2022-26(3)-03

UDC: 616-001.17:615.451.3

## ELECTRONIC-MICROSCOPIC CHANGES OF THE HEART OF OLD RATS WITH HYPERHOMOCYSTEMIA

**Kaminsky R. F.**

Bogomolets National Medical University (13, T. Shevchenko blvd., Kyiv, Ukraine, 01601

*Responsible for correspondence:*  
e-mail: [Anatomyntmu@gmail.com](mailto:Anatomyntmu@gmail.com)

Received: April, 25, 2022; Accepted: May, 31, 2022

**Annotation.** *Hyperhomocysteinemia (HHCys) is a pathological condition characterized by an increase in plasma homocysteine (HCys) levels above 15 μmol/l and causes abnormal functioning of the human body. Increasing the concentration of HCys in plasma can cause structural and functional changes in all organs and systems of the body, but, as research shows, the most vulnerable is the cardiovascular system. The aim of the research is to study the ultrastructural changes in the heart of old rats under conditions of HHCys. The experimental study was performed on 22 white nonlinear old (24-26 months) male rats. During the experiment, the animals were divided into two groups - control and experimental. Simulation of persistent HHCys was achieved by administering to rats the experimental group thiolactone HCys at a dose of 200 mg/kg body weight intragastrally for 60 days. Ultrathin sections were studied in the PEM - 125K electron microscope. It was found that the introduction of thiolactone HCys to old rats at a dose of 200 mg/kg is associated with the development of destructive-dystrophic changes in the heart of animals. They are visible in all layers of the organ in the form of a significant increase in the volume of connective tissue. The lumens of most hemocapillaries were dilated and filled with blood cells. In endotheliocytes there are severe ultrastructural disorders, manifested by the disappearance of micropinocytic vesicles and caveolae, the formation of large caveolae-like structures, which led to a violation of transcapillary metabolism. Intracellular edema, hypertrophied mitochondria with locally enlightened matrix, destroyed crystals, damaged outer membrane were found in cardiomyocytes. Myofibrils became thinner, they showed lysis of myofibrils.*

**Keywords:** *homocysteine, hyperhomocysteinemia, hypertrophy, cardiomyocytes, collagen fibers, hemocapillaries, rats.*

### Introduction

Hyperhomocysteinemia (HHCys) is a pathological condition characterized by an increase in the level of homocysteine (HCys) in blood plasma above 15 μmol / l and causes a violation of the normal functioning of the human body. The factors that cause the development of HHCys have been identified. Because HCys metabolism is directly dependent on vitamins B6, B9 and B12, which act as cofactors and donors of methyl groups and folate, in the absence or insufficient amount in the body of them, HCys is not able to be utilized, and accumulates in cells and blood plasma. It is also known that cancers such as breast and pancreatic cancer, ovarian cancer, lymphoblastic leukemia are accompanied by HHCys, because malignant cells have high mitotic activity, requiring a significant number of methyl groups. Experimental studies show the negative effects of smoking, excessive coffee consumption and alcohol abuse on blood HCys levels [1, 4, 10, 12, 14, 19].

Increasing the concentration of HCys in plasma can cause structural and functional changes in all organs and systems of the body, but, as research shows, the most vulnerable is the cardiovascular system. The state of HHCys significantly increases the risk of myocardial infarction, ischemic and/or hemorrhagic strokes, venous thrombosis, coronary heart disease [2, 6].

To date, the mechanisms by which HCys is able to exert a pathological effect on the organs of the cardiovascular system remain unknown. The available data of experimental works prove the fact that HHCys causes damage of endothelial cells of the vascular wall, smooth

myocytes, platelets, disrupts the normal functioning of the coagulation and fibrinolytic systems of the body. Endothelial dysfunction is a frequent complication of HHCys, resulting from impaired synthesis and bioavailability of nitric oxide (NO) in the epithelial cells of vascular walls, the production of reactive oxygen species (ROS) and, as a consequence, the development of oxidative stress (OS). The presence of positive correlations between the plasma HCys level and structural changes in the myocardium of rats was also found. In particular, the development of diastolic dysfunction and left ventricular remodeling was observed in hypertensive rats with HHCys. In addition, HHCys disrupts the absorption of oxygen in the myocardium, increases the content of superoxide radicals due to increased activity of NADPH oxidase [11, 21, 22].

Currently, a small number of works on the peculiarities of histological changes in the structural components of the heart under conditions of HHCys have been found in scientific sources, which determines the relevance of our chosen research topic.

*The aim* of the research is to study the ultrastructural changes in the heart of old rats under conditions of HHCys.

### Materials and methods

The studies were performed on 64 white nonlinear old (24-26 months) male rats. During the experiment, the animals were divided into two groups - control and experimental (32 animals in each group). Simulation of the state of HHCys was achieved by administering to rats

of the experimental group thiolactone HCys at a dose of 200 mg / kg body weight intragastrally for 60 days. Animals were decontaminated by decapitation under thiopental anesthesia. Small pieces of rat heart were selected for ultrastructural study. They were fixed in 2.5-3% solution of glutaraldehyde and postfixed in 1% osmium tetroxide solution on the pH 7.2-7.4 phosphate buffer, followed by dehydration in alcohol and propylene oxide and then embedded into mixture of epoxy resins. Ultrathin sections were contrasted with uraniacetate and lead citrate according to Reynolds and studied in the PEM - 125K electron microscope [9, 13].

The experimental study was carried out in compliance with international recommendations on conducting medical and biological research using animals in accordance with the "General principles of work on animals", approved by the 1st National Congress on Bioethics (Kyiv, Ukraine, 2001) and agreed with the provisions of the "European Convention for the Protection of Vertebrate Animals , which are used for experimental and other scientific purposes" (Strasbourg, France, 1986). Compliance with the ethical principles of work is certified by the bioethics committee of the National Medical University named after O.O. Bogomolets (protocol № 6 dated September 6, 2020).

### Results

Submicroscopic studies of the heart of old animals in experimental HHCys revealed profound destructive and degenerative changes in the organ wall. In the endocardium, edema of the cytoplasm of endothelial cells and violation of their integrity, thickening of collagen fibers in connective tissue were revealed. Significant destructive changes in the myocardium were observed. Some muscle fibers were destroyed. The structure of the intercalated discs was disrupted, the intercellular contacts were damaged, and the microcellular spaces were expanded (Fig. 1).

Significant changes were found in cardiomyocytes. The nuclei are hypertrophied, they were dominated by heterochromatin, which in the form of dense bodies had a submembrane location. Karyoplasm was electron light. The perinuclear space has expanded significantly.

Deep destruction of membrane organelles was detected in the cytoplasm. Hypertrophied mitochondria contain a locally enlightened matrix and destroyed, fragmented cristae. In some of these organelles, the outer membrane was damaged. Intracellular edema was detected, which was manifested by dilation of the tubules of the endoplasmic reticulum and their partial fragmentation. Myofibrils became thinner, they revealed lysis of myofibrils and disruption of the order of sarcomeres. Locally, myofilaments in myofibrils were compacted and homogenized (Fig. 2). However, locally hypertrophied myofibrils have been found in muscle fibers.

The volume and thickness of collagen fibers in the myocardial connective tissue have increased. Also they

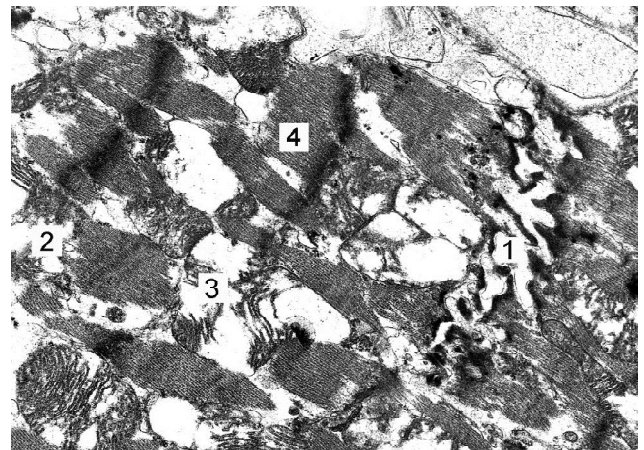


Fig. 1. Electronogram of myocardial cardiomyocytes of an old rat with hyperhomocysteinemia: 1 - intercalated disc; 2 - cytoplasm of the cardiomyocyte; 3 - mitochondria; 4 - myofibrils. x 12000 magnification.

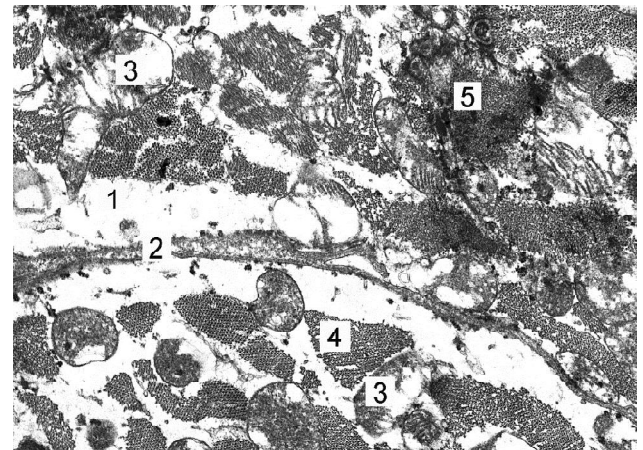


Fig. 2. Electronogram of myocardial cardiomyocytes of an old rat with hyperhomocysteinemia: 1 - cytoplasm of cardiomyocytes; 2 - plasmalemma of cardiomyocytes; 3 - mitochondria; 4 - myofibrils, 5 - local area of myofibril compaction. x 10 000 magnification.

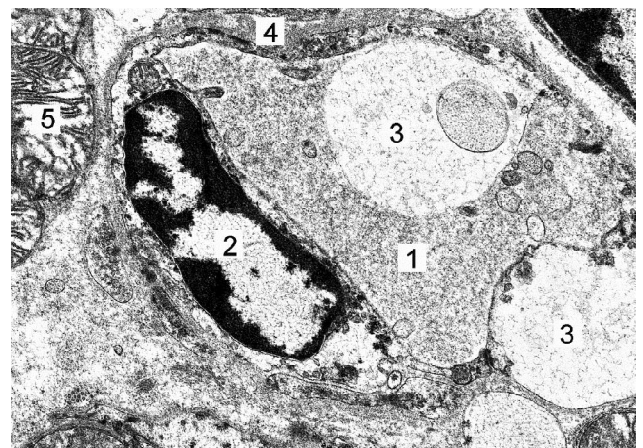


Fig. 3. Electronogram of the hemocapillary of the myocardium of an old rat with hyperhomocysteinemia: 1 - lumen of the hemocapillary; 2 - endothelial cell nucleus; 3 - peripheral, swollen part of the cytoplasm; 4 - basement membrane; 5 - cytoplasm of the cardiomyocyte. x 8 000 magnification.

formed thick bundles. Hemocapillaries were dilated, filled with formal blood elements. Significant ultrastructural disorders are present in endotheliocytes. The luminal surface was fragmentarily damaged. Micropinocytic vesicles and caveolae were rare. The cytoplasm contained locally swollen areas with the formation of large vacuole-like structures. The basement membrane is thickened, contains thick bundles of collagen fibers, or compacted, osmiophilic. Areas with leukocyte infiltration were found in the pericapillary spaces (Fig. 3).

### Discussion

The results of experimental studies show that HCys induces apoptosis of cardiomyocytes and causes the development of cardiac dysfunction. These effects are associated with activation of p22<sup>phox</sup> and increased p62 activity mediated by NADPH oxidase (NOX). The researchers noted that under experimental conditions in rats, inhibition of p22<sup>phox</sup> and p62 expression in cardiomyocytes significantly reduced ROS production. Disruption of the NOX-p62 relationship prevented the development of diastolic dysfunction in animals. Thus, the authors proved the existence of a mechanism of apoptosis of cardiomyocytes under conditions of HHCys - a special signaling pathway NOX-p62 [23].

HHCys caused by methionine administration intraperitoneally at a dose of 300 mg / kg for 1 month causes excessive accumulation in the myocardium of experimental rats of fibrillar collagen types I and III in the interstitium and perivascular spaces. This process leads to the development of fibrosis, increased expression of transforming growth factor  $\beta$  (TGF- $\beta$ 1), matrix metalloproteinases (MMP-9), tissue metalloproteinase inhibitor (TIMP-2) and decreased expression of MMP-2, TIMP-1. HHCys also acts as an initiator of apoptosis of cardiomyocytes and fibroblasts of heart tissue by increasing the expression of caspase-3. The results confirm the fact that HHCys is a factor that activates the processes of remodeling of the heart [3, 5].

Under the conditions of methionine administration to rats for three weeks, the normal functioning of mitochondria of heart cells is disrupted, which is manifested by an increase in lactate levels in the cytoplasm, as well as the development of OS and carbonylation of mitochondrial proteins. Activation of the antioxidant defense system somewhat compensates for the manifestations of OS, but is not able to completely eliminate the negative impact of

HHCys on the body. The authors also note that under these conditions modeling of NO deficiency, by introducing L-NG-Nitro arginine methyl ester (L-NAME) - a non-selective inhibitor of NO synthase, causes inhibition of aerobic oxidation in mitochondria. The last manifests itself in the form of a statistically significant decrease in the activity of the enzymes succinate dehydrogenase, lactate dehydrogenase and the accumulation of lactate in the cytoplasm of cardiomyocytes. In addition, inhibition of oxidative phosphorylation processes has been registered in organelles [7, 15, 16, 17].

It was found that HHCys increases the expression of MMP-2 in the heart of transgenic mice, leading to decreased functional activity of the heart and severe morphological changes, namely ventricular remodeling, hypertrophy of contractile cardiomyocytes, lysis of myofilaments, destruction of sarcomeres,  $\alpha$ -actinin and fibroblast proliferation. In addition, it is known that OS causes the activation of the intracellular isoform of MMP-2, which due to significant structural changes in the myocardium leads to heart failure. In the extracellular matrix, this enzyme is activated by peroxynitrite, which increases under conditions of HHCys and OS. The presence of products of oxidative modification and glutathione affects the catalytic center of MMP-2, activating it [8, 18, 20].

### Conclusions and prospects for further development

1. Ultrastructural studies have shown that experimental hyperhomocysteinemia in the heart of old rats develops destructive-dystrophic changes. They are visible in all layers of the organ in the form of a significant increase in the volume of connective tissue. The lumens of most hemocapillaries were dilated and filled with blood cells. In endotheliocytes there are deep ultrastructural disorders, manifested by the disappearance of micropinocytic vesicles and caveolae, the formation of large caveola-like structures, which led to a violation of transcapillary metabolism. Intracellular edema, hypertrophied mitochondria with locally enlightened matrix, destroyed crystals, damaged outer membrane were found in cardiomyocytes. Myofibrils became thinner, they showed lysis of myofibrils.

The study of histological changes in the structural components of the heart under conditions of HHCys in the age aspect increases the value of experimental work, given the fact that diseases of the cardiovascular system are more common among adults and the elderly.

### References

- [1] Ables, G. P., Ouattara, A., Hampton, T. G., Cooke, D., Perodin, F., Augie, I., ... & Orentreich, D. S. (2015). Dietary methionine restriction in mice elicits an adaptive cardiovascular response to hyperhomocysteinemia. *Sci Rep.*, 5, 8886. doi: 10.1038/srep08886
- [2] Aghayan, S. S., Farajzaden, A., Bagheri-Hosseinabadi, Z., Fadaei, H., Yarmohammadi, M., & Jafarizani, M. (2020). Elevated homocysteine, as a biomarker of cardiac injury, in panic disorder patients due to oxidative stress. *Brain and Behavior*, 10(12), e01851. doi: 10.1002/brb3.1851
- [3] Arpino, V., Brock, M., & Gill, S. E. (2015). The role of TIMPs in regulation of extracellular matrix proteolysis. *Matrix Biol.*, 44-46, 247-254. doi: 10.1016/j.matbio.2015.03.005
- [4] Barroso, M., Handy, D. E., & Castro, R. (2017). The Link Between Hyperhomocysteinemia and Hypomethylation: Implications for Cardiovascular Disease. *Journal of Inborn Errors of Metabolism & Screening*, 5, 1-15. doi: 10.1177/2326409817698994

- [5] Chaouad, B., Moudilou, E. N., Ghoul, A., Zerrouk, F., Moulahoum, A., Othmani-Mecif, K., ... & Benazzoug, Y. (2019). Hyperhomocysteinemia and myocardial remodeling in the sand rat, *Psammomys obesus*. *Acta Histochem*, 121(7), 823-832. doi: 10.1016/j.acthis.2019.07.008
- [6] Chrysant, S. G., & Chrysant, G. S. (2018). The current status of homocysteine as a risk factor for cardiovascular disease: a mini review. *Expert Rev Cardiovasc Ther.*, 16(8), 559-565. doi: 10.1080/14779072.2018.1497974
- [7] Cueto, R., Zhang, L., Shan, H. M., Huang, X., Li, X., Li, Y. F., ... & Wang, H. (2018). Identification of homocysteine-suppressive mitochondrial ETC complex genes and tissue expression profile-novel hypothesis establishment. *Redox Biol.*, 17, 70-88. doi: 10.1016/j.redox.2018.03.015
- [8] Deleon-Pennell, K. Y., Meschiari, C. A., Jung, M., & Lindsey, M. L. (2017). Matrix Metalloproteinases in Myocardial Infarction and Heart Failure. *Prog Mol Biol., Transl Sci.*, 147, 75-100. doi: 10.1016/bs.pmbts.2017.02.001
- [9] Dobrelia, N. V., Boitsova, L. V., & Danova, I. V. (2015). Legal basis for ethical examination of preclinical studies of drugs using laboratory animals. *Pharmacology and drug toxicology*, 2, 95-100.
- [10] Favarszani, J. L., Hammerschmidt, T. G., Sitta, A., Deon, M., Wajner, M., & Vargas, C. R. (2017). Oxidative Stress in Homocysteinuria Due to Cystathionine  $\beta$ -Synthase Deficiency: Findings in Patients and in Animal Models. *Cell Mol Neurobiol.*, 37(8), 1477-1485. doi: 10.1007/s10571-017-0478-0
- [11] Ganguli, P., & Alam, S. F. (2015). Role of homocysteine in the development of cardiovascular disease. *Nutr J.*, 14(6). doi: 10.1186/1475-2891-14-6
- [12] Haloul, M., Vinjamuri, S. J., Naquiallah, D., Mizza, M. I., Qureshi, M., Hassan, C., ... & Mahmoud, A. M. (2020). Hyperhomocysteinemia and Low Folate and Vitamin B12 Are Associated with Vascular Dysfunction and Impaired Nitric Oxide Sensitivity in Morbidly Obese Patients. *Nutrients*, 12(7), 2014. doi: 10.3390/nu12072014
- [13] Horalskyi, L. P., Khomych, V. T., & Kononskyi, O. I. (2011). *Fundamentals of histological technique and morphofunctional research methods in normal and pathology*. Zhytomyr: Polissya.
- [14] Jeremic, J., Turnic, T. N., Zivkovic, V., Jeremic, N., Milosavljevic, I., Srejskovic, I., ... & Jakovljevic, V. (2018). Vitamin B complex mitigates cardiac dysfunction in high-methionine diet-induced hyperhomocysteinemia. *Clin Exp Pharmacol Physiol.*, 45(7), 683-693. doi: 10.1111/1440-1681.12930
- [15] Kaplan, P., Tatarkova, Z., Sionova, M. K., Racay, P., & Lehotsky, J. (2020). Homocysteine and Mitochondria in Cardiovascular and Cerebrovascular Systems. *Int J Mol Sci.*, 21(20), e7698. doi: 10.3390/ijms21207698
- [16] Kiyuna, L. A., Albuquerque, R. P., Chen, C. M., Mochly-Rosen, D., & Ferreira, J. C. B. (2018). Targeting mitochondrial dysfunction and oxidative stress in heart failure: challenges and opportunities. *Free Radic Biol Med.*, 129, 155-168. doi: 10.1016/j.freeradbiomed
- [17] Madungwe, N. B., Zilberstein, N., Feng, Y., & Bopassa, J. C. (2016). Critical role of mitochondrial ROS is dependent on their site of production on the electron transport chain in ischemic heart. *Am J Cardiovasc Dis.*, 6(3), 93-108.
- [18] Mohammad, G., & Kowluru, R. A. (2020). Homocysteine Disrupts Balance between MMP-9 and Its Tissue Inhibitor in Diabetic Retinopathy: The Role of DNA Methylation. *Int J Mol Sci.*, 21(5), 1771. doi: 10.3390/ijms21051771
- [19] Provotorov, V., Korokin, M. V., Pokrovskii, M. V., Povetkin, S. V., Lazareva, G. A., Stepchenko, A. A., ... & Bystrova, N. A. (2016). Endothelial and cardioprotective effects of vitamin B6 and folic acid in modelling methionine-induced hyperhomocysteinemia. *Research Results in Pharmacology*, 2(1), 16-19. doi: 10.18413/2313-8971-2016-2-1-16-19
- [20] Radosinska, J., Barancik, M., & Vrbjar, N. (2017). Heart failure and role of circulating MMP-2 and MMP-9. *Panminerva Med.*, 59(3), 241-253. doi: 10.23736/S0031-0808.17.03321-3
- [21] Rehman, T., Shabbir, M. A., Inam-Ur-Roheem, M., Manzoor, M. F., Ahmad, N., Liu, Z. W., ... & Aadil, R. M. (2020). Cysteine and homocysteine as biomarker of various diseases. *Food Sci Nutr.*, 8(9), 4696-4707. doi: 10.1002/fsn3.1818
- [22] Tinelli, C., Pino, A. D., Ficulle, E., Marcelli, S., & Feligioni, M. (2019). Hyperhomocysteinemia as a Risk Factor and Potential Nutraceutical Target for Certain Pathologies. *Front Nutr.*, 6, 49. doi: 10.3389/fnut.2019.00049
- [23] Yin, R., Wang, H., Li, C., Wang, L., Lai, S., Yang, X., ... & Zhang, W. (2022). Induction of apoptosis and autosis in cardiomyocytes by the combination of homocysteine and copper via NOX-mediated p62 expression. *Cell Death Discov.*, 8, 75. doi: 10.1038/s41420-022-00870-4

#### ЕЛЕКТРОННО-МІКРОСКОПІЧНІ ЗМІНИ СЕРЦЯ СТАРИХ ЩУРІВ ПРИ ГІПЕРГОМОЦИСТЕЇНЕМІЇ

Камінський Р. Ф.

**Анотація.** Гіпергомоцистеїнемія (ГГц) є патологічним станом, який характеризується зростанням рівня Гц плазми крові вище 15 мкмоль/л та стає причиною порушення нормального функціонування організму людини. Підвищення концентрації в плазмі крові Гц здатне спричинити структурно-функціональні зміни всіх органів і систем організму, але, як показують результати досліджень, найбільш вразливою є серцево-судинна система. Метою дослідження є вивчення ультраструктурних змін серця старих щурів за умов ГГц. Експериментальне дослідження проведене на 22 білих нелійних старих (24-26 місяці) щурах. Протягом дослідження тварин було поділено на дві групи - контрольну та дослідну. Моделювання стійкої ГГц досягали шляхом введення щурам дослідної групи тіолактону Гц у дозі of 200 мг/кг маси тіла інтрагастрально протягом 60 днів. Ультратонкі зрізи досліджували за допомогою електронного мікроскопа - ПЕМ - 125К. Встановлено, що введення тіолактону Гц старим щурам у дозі 200 мг/кг асоціюється з розвитком деструктивно-дистрофічних змін серця тварин. Вони помітні в усіх оболонках органу у вигляді значного зростання об'єму сполучної тканини. Просвіти більшості гемокапілярів були розширені та заповнювались форменими елементами крові. В ендотеліюцитах наявні глибокі ультраструктурні порушення, що проявлялися зникненням мікропіноцитозних міхурців і кавеол, утворенням великих кавеолеподібних структур, що призвело до порушення транскapілярного обміну. У кардіоміюцитах виявлено внутрішньоклітинний набряк, гіпертрофовані мітохондрії з локально просвітленим матриксом, зруйнованими кристами, порушеною зовнішньою мембраною. Міофібрили стали тоншими, у них виявляється лізис міофібрил.

**Ключові слова:** гомоцистеїн, гіпергомоцистеїнемія, гіпертрофія, кардіоміюцити, колагенові волокна, гемокапіляри, щури.