

PRACA ORYGINALNA
ORIGINAL ARTICLE

THE INFLUENCE OF DRUG TREATMENT ON CARDIO-VASCULAR SYSTEM OF THE RATS WITH CONGENITAL HYPOTHYROIDISM

Svetlana Chuhray¹, Viktoriya Lavrynenko², Rostyslav Kaminsky¹, Olena Ustyomenko¹, Iryna Dzevulska¹, Ruzhena Matkivska¹, Oleksandr Kovalchuk², Olena Holubchenko¹, Liudmyla Sokurenko^{1,2}

¹BOGOMOLETS NATIONAL MEDICAL UNIVERSITY, KYIV, UKRAINE

²TARAS SHEVCHENKO NATIONAL UNIVERSITY OF KYIV, UKRAINE

ABSTRACT

Introduction: In the treatment of hypothyroidism substitution therapy with L-thyroxine is used, it is also advisable to use the metabolites with membrane-stabilizing properties that normalize the metabolism in the body, for example, calcitonin, which significantly reduces the depth of the dystrophic phenomena in the myocardium.

The aim was to study the patterns of structural changes in the left ventricular myocardial capillaries of rats with congenital hypothyroidism in combinative drug therapy with L-thyroxine and calcitonin.

Materials and methods: 30 white Wistar line rats were used as experimental animals: 10 with treatment and 10 without as well as control – 10 intact Wistar line rats of the same age. Mercazolil was used to inhibit thyroid gland in order to model congenital hypothyroidism. After birth, the rats received L-thyroxine at a dose of 10 µg / kg per os daily, calcitonin at a dose of 1.0 MU / kg per day intramuscularly, then with mother's milk, later by themselves for 100 days. The arterial pressure was measured in all experimental groups during extraction from the experiment by plethysmograph, their left ventricular myocardium was examined under electron microscope and micropinocytotic vesicles in their cells were studied morphometrically.

Results: In rats with congenital hypothyroidism, for which L-thyroxin drug in combination with calcitonin was used as a substitution therapy, after pharmacological correction, in general there is no pronounced heteromorphism of the ultrastructure of the left ventricular myocardial blood capillaries, which was characteristic for animals without pharmacological correction. The analysis showed normalization of the content of free thyroxine in blood plasma and blood pressure of rats with congenital hypothyroidism after complex substitution therapy.

Conclusions: In rats with congenital hypothyroidism, which received L-thyroxine and calcitonin at birth, the myocardium capillaries generally remain intact and have morphological and functional characteristics similar to intact animals, which is the theoretical basis for the need for calcitonin to be used in substitution therapy in hypothyroidism.

KEY WORDS: myocardium, blood capillaries, rat, hypertension, electron microscopy, L-thyroxine, calcitonin

Wiad Lek 2019, 72, 7, 1300-1303

INTRODUCTION

Congenital hypothyroidism (CH) is defined as thyroid hormone deficiency present at birth and exact cause for the vast majority of cases of thyroid dysgenesis remains unknown, but management of CH is based on restoring thyroid function to normal, not necessarily knowing the exact underlying cause [1].

In the treatment of hypothyroidism substitution L-thyroxine therapy is used, which, according to some authors, has a positive effect on the level of arterial pressure [2, 3]. It is also advisable to use the metabolites with antioxidant membrane-stabilizing properties, that normalize the metabolism in the body [4, 5]. Experimental studies have shown that monotherapy with L-thyroxin only delays the formation of structural and functional changes in the myocardium of rats with thyroid-ectomy but does not prevent them, while the combined treatment significantly reduces the depth of myocardial dystrophic changes [6].

THE AIM

The aim of the study was examination of the patterns of structural changes in the left ventricular myocardial capillaries of the congenital hypothyroidism rats in a combined pharmacotherapy with L-thyroxine and calcitonin.

MATERIALS AND METHODS

30 white Wistar line rats were used for the experiments. All animals were kept in the Bogomolets National Medical University vivarium in standard conditions. Experimental group included 10 sexually-mature (100-day) Wistar CHT rats with treatment and 10 without. Control group included 10 intact Wistar line rats of the same age. The rats were treated with Mercazolil – thyreostatic that inhibited thyroid gland activity thus modeling the congenital hypothyroidism. Pregnant female rats were administered with Mercazolil from the 14th day of perinatal development. After birth, Mercazolil was received with the mother's milk,

Table I. Changes in the content of free thyroxine in blood plasma and AP figures in rats with substitution correction

	Control	CHT	CHT with correction
Arterial pressure, mm Hg	109,4±5,3	131,6±5,2* ^{**}	115,4±5,7
Thyroxine, pmol/l	8,58±0,72	2,77±0,76* ^{**}	8,96±1,39 ^{**}

Note: * – $p < 0,05$ in comparison with the data of the Control;

** – $p < 0,05$ in comparison with the data of the group without substitution correction.

and later – by self-feeding. Throughout the experiment the daily dose of the drug was 20 mg / kg of body weight. Water was used as a solvent. When control and CHT rats were removed from the experiment, the immune-enzymatic method on the Sunrise RC device, TEKAN was used to control the development of hypothyroidism.

Correction of thyroid hormones deficiency began after birth of rats. Animals received L-thyroxine (Pharmac, Ukraine) at a dose of 10 μg / kg per os daily, calcitonin (a preparation “Miacalcic”, a manufacturer of “Novartis”, Switzerland) at a dose of 1.0 MU / kg intramuscularly every other day with mother’s milk, and then independently for 100 days.

Animal studies were performed according to “General ethical principles of animal experiments”, adopted by the First National Congress on Bioethics (Kiev, 2001) as well as the Law of Ukraine “On protection of animals from cruelty” (2006).

When experimental rats were extracted from the experiment, the immune-enzymatic method on the Sunrise RC device, TEKAN was used to control the development of hypothyroidism while AP (arterial pressure) was controlled by plethysmograph.

Left ventricular myocardium of experimental rats was studied under electron microscope. General techniques of electron microscopic examination were used in material processing [7]. Ultratome Reihart (Austria) was used for production of ultra-thin sections that were further studied under electron microscope PEM-125K.

Analysis of all morphometric characteristics was conducted by the program “Organelle” on a semi-automatic graphic research processing device. The characteristics included: volumetric and quantitative densities, cross-section area and form factor of micropinocytotic vesicles (MPV). Student parametric and Kolmogorov-Smirnov nonparametric criteria were used for statistical processing according to the variation statistics principles.

RESULTS

CHANGES IN FUNCTIONAL PARAMETERS IN EXPERIMENTAL RATS

The immune-enzyme analysis showed no significant difference in the content of free thyroxine in the blood plasma of intact rats (8.58 ± 0.72 pmol / l) and rats with congenital hypothyroidism with complex substitution correction (8.96 ± 1.39 pmol / l), as well as blood pressure index (115.4 ± 5.7 mm Hg) (Table I).

ULTRASTRUCTURE OF BLOOD CAPILLARIES OF MYOCARDIUM IN RATS WITH SUBSTITUTIVE CORRECTION

In rats with congenital hypothyroidism, for which the preparation of L-thyroxine in combination with calcitonin was used, the lumen of most left ventricular myocardial circulatory capillaries is enlarged, incompletely filled with finely dispersed substance. The lumen surface of the endothelium is smooth, contains a moderate amount of shallow invaginations and micro-outgrowths (Fig.1, Fig. 2). Peripheral areas of the cells had insignificant thickness.

The nuclei of these endothelial cells are oval, slightly elongated, with a smoothed surface due to the fact that the nuclear membrane does not form deep invaginations. Karyoplasm is sometimes spotty due to the uneven distribution of chromatin, among which, nevertheless, euchromatin predominates.

The cytoplasm contains a large number of mitochondria, ribosomes, tubules of the granular endoplasmic reticulum (Fig. 1, Fig. 2). Mitochondria are represented by structures of mostly round shape and large size. They have a matrix of moderate electron density, which contains intramitochondrial membranes – well-structured cristae, the amount of which varies in different organelles (Fig.1, Fig. 2).

The endoplasmic reticulum is represented by its rough form, its small, moderately enlarged tubules, as well as ribosomes and polysomes, are located throughout the cytoplasm (Fig.1, Fig.2).

As for the characteristic endothelial structures – the bodies of Weibel-Palade, the cytoplasm contains their typical forms, in contrast to rats with congenital hypothyroidism without correction. Interestingly, from our point of view, is that these bodies are present in the endothelium of rats with arterial hypertension after pharmacological correction.

MICROPINOCYTOTIC VESICLES IN ENDOTHELIAL CELLS OF MYOCARDIAL BLOOD CAPILLARIES IN RATS WITH SUBSTITUTIVE CORRECTION

In nuclei of cells with signs of active transport chromatin is distributed unevenly, mainly under the membrane. Micropinocytotic vesicles are found both attached to the basal or lumen membranes or detached (Fig.1, Fig. 2). Their quantitative density is statistically the same with control parameters and significantly differs from the indicators in untreated animals (Table II).

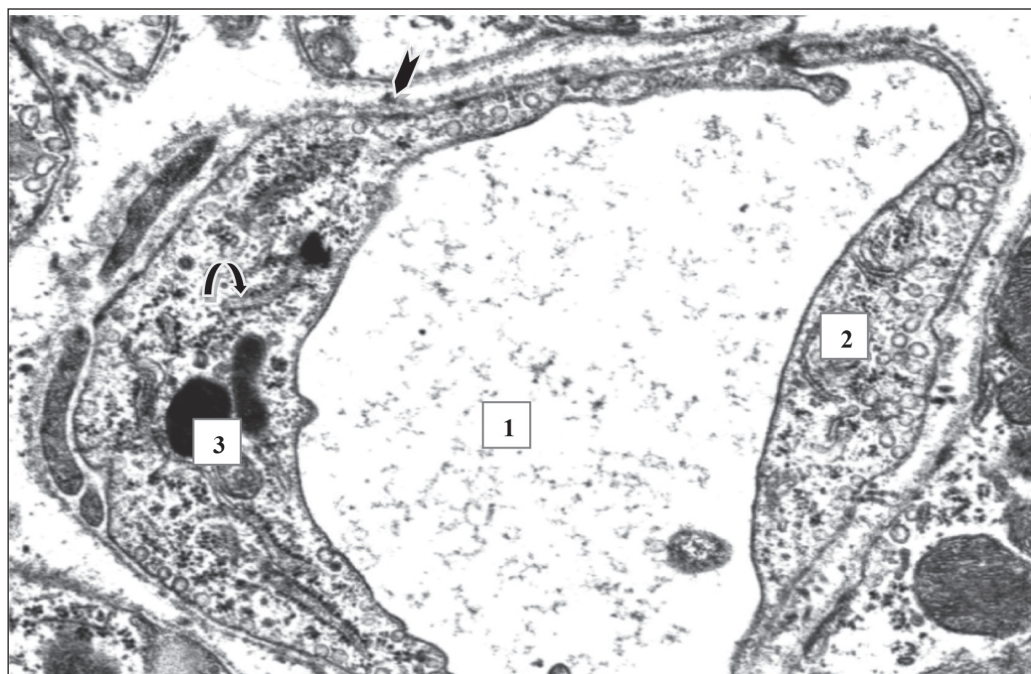


Fig.1. Blood capillaries of the left ventricle myocardium of rats with combined correction of congenital hypothyroidism by L-thyroxine and calcitonin. Electron microscopic photo. Magnification: 28000. Lumen (1) of the capillary, mitochondria (2), Weibel–Palade bodies (3), ER tubules (▲) in endothelial cells, basement membrane (▲).

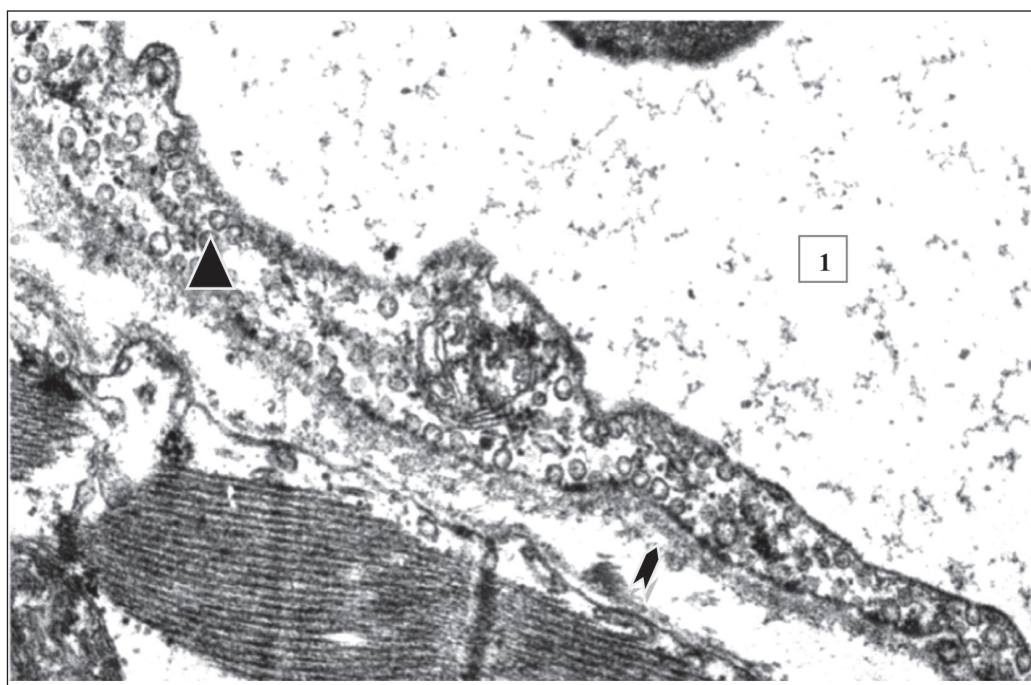


Fig.2. Blood capillaries of the left ventricle myocardium of rats with combined correction of congenital hypotireosis by L-thyroxine and calcitonin. Electron microscopic photo. Magnification: 40000. Lumen (1) of the capillary, mitochondria (2), micropinocytotic vesicles (▲) in endothelial cells, basement membrane (▲).

DISCUSSION

It is known from the literature that in blood capillaries of the myocardium in sexually mature (100-day) rats with CHT destructive-dystrophic processes are approximately balanced with compensatory and adaptive

ones. In the myocardium, the quantitative density of the capillaries decreases. Activation of transcytosis occurs against significant violations of vesiculation. Some of the endothelial cells of experimental animals contain a moderate amount of transport vesicles, while others

Table II. The morphometric indexes of MPV in endothelial cells of myocardial circulatory capillaries

Groups	Volumetric density, %	Quantitative density, 1/ μm^3	Average area, $10^{-2} \mu\text{m}^2$	Form factor
Control	21,95±0,85	332,5±18,6	0,57±0,01	0,85±0,007
CHT	23,00±1,49	443,7±25,9*	0,55±0,01	0,84±0,006
CHT and correction	19,28±1, 19	307,6±32,7**	0,54±0,01	0,86±0,01

Note: * – $p < 0,05$ in comparison with the data of the Control;

** – $p < 0,05$ in comparison with the data of the group before treatment.

are overfilled with these structures and desquamate into the lumen [8].

The choice of pharmacological correction drugs for rats with congenital hypothyroidism was dictated by the fact that one of the reasons for the inefficiency of monotherapy with L-thyroxin may be the deficiency of calcitonin, a iodine-independent hormone of thyroid gland, whose content is lowered in blood plasma of patients with thyroidectomy [9]. The immune-enzyme analysis showed no significant difference in the plasma levels of free thyroxine in intact rats and rats with congenital hypothyroidism after complex substitution therapy (8.96 ± 1.39 pmol / l). The indicator is not significantly different from its value in intact animals of the same age and blood pressure.

In rats with congenital hypothyroidism, for which the drug L-thyroxin in combination with calcitonin was used, after the pharmacological correction, in general there is no apparent heteromorphism of the ultrastructure of the left ventricular myocardial blood capillaries, which was characteristic of animals without pharmacological correction. Capillaries in general maintain their integrity and have morphological features of functional activity similar to intact animals. Another feature in this observation group was the absence of apoptotic altered endothelial cells, which is obviously due to the ability of calcitonin to increase the activity of anti-apoptotic proteins in the cells [10].

CONCLUSIONS

In rats with congenital hypothyroidism, which have received L-thyroxine and calcitonin at birth, the myocardium capillaries generally remain intact and have morphological and functional signs of activity similar to intact animals, which is the theoretical basis for the need for calcitonin to be used in substitution therapy in hypothyroidism.

REFERENCES

1. Rastogi M. V., LaFranchi S. H. Congenital hypothyroidism. *Orphanet J Rare Dis.* 2010; 5: 17.
2. Katerhenchuk V.I., Beregova O.P. Cardiovascular hypothyroidism masks *Internal Medicine.* 2007; 3(3): 50-55.

3. Dernellis J., Panaretou M. Effects of thyroid replacement therapy on arterial blood pressure in patients with hypertension and hypothyroidism. *Am. Heart J.* 2002;143(4):718-24.
4. Maksutina N. P., Pylypchuk L. V. Structured system of natural vitamins-antioxidants. *Liki Ukr.* 2002; 10: 31-34.
5. Parkhomenko A.N. Metabolic therapy, or cardioprotection in coronary heart disease: outcomes and perspectives. *Cardiology.* 2008; 4: 15-19.
6. Udovcic M, Pena RH, Patham B, Tabatabai L, Kansara A. Hypothyroidism and the Heart. *Methodist Debakey Cardiovasc J.* 2017;13(2):55-59.
7. Karupu V.Ya. *Electron microscopy.* K.: Vishcha School, 1984: 208 p.
8. Chuhay S. M., Lavrynenko V. E., Kaminsky R. F., Dzevulska I. V., Malikov O. V., Kovalchuk O. I., Sokurenko L. M. Morphofunctional status of cardio-vascular system of rats with congenital hypotireosis. *Wiad Lek* 2019; 72(2): 229-233.
9. Schulz R., Heusch G. Hibernating myocardium. *Heart.* 2000; 84(6): 587-594.
10. Sueur S., Pesant M, Rochette L, Connat J.L. Antiapoptotic effect of calcitonin gene-related peptide on oxidative stress-induced injury in H9c2 cardiomyocytes via the RAMP1/CRLR complex. *J Mol Cell Cardiol.* 2005; 39(6): 955-963.

Acknowledgements: The authors would like to thank the employees of the Scientific Research Institute Experimental And Clinical Medicine (Institute of Pathologists Problems) at Bogomolets National Medical University prof. L.O. Stechenko and T.P.Kuftyreva.

Authors' contributions:

According to the order of the Authorship.

Conflict of interest:

The Authors declare no conflict of interest.

CORRESPONDING AUTHOR

Liudmyla M. Sokurenko

Department of Histology and Embryology,

Bogomolets National Medical University

Kyiv, Ukraine

tel: +380675010815

e-mail: l-sokurenko@i.ua

Received: 01.03.2019

Accepted: 11.06.2019