

Prospective analysis of surgical and functional outcomes after total proctocolectomy with ileal pouch-anal anastomosis in 86 patients with ulcerative colitis

M. Kucher

Bogomolets National Medical University, Kyiv

✉ Prof. Mykola Kucher: nickkucher45@yahoo.com

M. Kucher, Department of Surgery No 1, <http://orcid.org/0000-0001-8820-2923>

Proctocolectomy with an ileal pouch-anal anastomosis is currently considered the procedure of choice for the majority of patients with ulcerative colitis. Certain controversies about pouch design and pouch-anal anastomosis technique remain a matter of debate, and possible advantages of laparoscopic approach are still being discussed.

OBJECTIVE — to investigate short-term and long-term outcomes of laparoscopic and open restorative proctocolectomy for UC in terms of postoperative morbidity and pouch function depending on the three types of construction of a neorectum described in our research.

MATERIALS AND METHODS. 86 patients with inflammatory bowel disease underwent one-stage or two-stage restorative proctocolectomy. The two ileal pouch configurations were used: S-pouch — in 16 patients and J-pouch — in 70 patients. Removal of the distal rectum and ileal pouch-anal anastomosis were performed using transanal distal rectum mucosectomy followed by a handsewn pouch-anal anastomosis ($n=45$) or a double-stapled technique ($n=31$). Laparoscopic approach was applied in 39 patients, and open surgery — in 47 patients. The short-term (30 days after surgery) and long-term surgical outcomes were prospectively studied. The analysis of functional outcomes was based on the number of bowel movements a day, episodes of fecal incontinence, seepage, and urgency. Instrumental investigation included measurement of the anal sphincter pressures and ileal pouch threshold volume as well as the study of its residual volume. Statistical analysis was performed using SPSS statistical software.

RESULTS. There was no postoperative mortality. In the laparoscopic group, 4 (10.3%) patients had early postoperative complications compared with 13 (27.7%) patients in the open surgery group, but the difference was not statistically significant (Fisher exact test value is 0.0579 at $p<0.05$). Pouch failure occurred in 4 patients. The second-stage laparoscopic restorative procedure revealed the abdominal cavity almost free of adhesions in 19 (86.4%) patients after laparoscopic total colectomy. The total number of early and late mucosectomy complications was significantly higher, 12 (75.0%) vs. 10 (26.0%) ($p=0.0018$), in patients managed with a handsewn S pouch-anal anastomosis than in patients treated with a J-pouch-anal anastomosis. Good functional outcomes were observed in 44 (51.0%) patients. A strong negative correlation was found between the pouch threshold volume and the number of bowel movements per 24 hours ($r=-0.7347$, $p<0.0001$). The seepage episodes were detected in 30 (34.8%) patients. The resting anal sphincter pressure was the only measured parameter which correlated accurately with the number of day and night seepage episodes ($r=-0.74$, $p<0.0001$).

CONCLUSIONS. Good functional outcomes of construction of a neorectum were associated with the resting anal sphincter pressure (≥ 30 mm Hg) and ileal pouch threshold volume (150–250 ml).

The S-shaped and J-shaped pouches demonstrated the same functional outcomes and posed similar risks. The S-pouch was associated with a higher postoperative morbidity ($p=0.0018$). There was no significant difference between laparoscopic and open surgery groups in terms of morbidity rate and functional outcomes. However, it was much easier to perform the second-stage surgery after laparoscopy due to less adhesion formation.

KEYWORDS

ulcerative colitis, laparoscopic restorative proctocolectomy, ileal pouch function.

ARTICLE • Received 2021-12-21 • Received in revised form 2022-01-15

© General Surgery, 2022

Ulcerative colitis (UC) is the most common inflammatory bowel disease (IBD). In the 21st century, it is diagnosed worldwide [25]. Although medical therapy has improved over the past decades, colectomy rates remain up to 15 % [29].

Proctocolectomy and reconstruction with an ileal pouch-anal anastomosis (IPAA) has been considered the procedure of choice for the majority of patients with ulcerative colitis since its first description in 1978 [28]. Over the time, the procedure has undergone some modifications due to the development of the anorectal mucosectomy approach as well as introduction of the pouch-anal anastomosis technique and pouch configuration. Transanal mucosectomy with a handsewn IPAA is still considered the most complete curative surgical procedure for UC, especially when the distal rectal mucosa becomes inflamed or dysplastic [16]. The modification, in which the ileal pouch is stapled to the anus 1,5–2 cm above the dentate line, suggested in 1986 [8, 14], greatly simplified its implementation. At the same time, this procedure provides preservation of the anal transition zone. Each technique has both advantages and disadvantages in terms of long-term functional outcomes, operative and postoperative complications, and the risk of neoplasia. Consequently, the proper indications for their application are still being specified [3, 16]. Pouch configuration with either three (S-shape) or two (J-shape) loops of the small bowel is still in use, however, J-pouch construction [36] has become the most commonly used technique as it is safe and practical [24].

Despite strong data supporting the feasibility, durability and the maintenance of long-term functional outcomes of the procedure, certain controversies about the method of construction of a neorectum remain a matter of debate.

Laparoscopic approach for total proctocolectomy was introduced in 1992 for the purpose of reducing the incidence of surgical trauma, thus ensuring fast recovery [30]. Over the past 30 years, laparoscopic-assisted proctocolectomy with IPAA has been gradually gaining acceptance among the surgeons, however, the benefits and proper indications for laparoscopic approach are still being discussed [17].

OBJECTIVE – to investigate short-term and long-term outcomes of laparoscopic and open restorative proctocolectomy for UC in terms of postoperative morbidity and pouch function depending on the three types of construction of a neorectum described in our research.

Materials and methods

This is a prospective single-center and a single-surgeon study. Between 1997 and 2020, 86 patients

with inflammatory bowel disease (IBD) underwent a one- or two-stage procedure for restorative proctocolectomy that was performed by one surgeon. 73 patients with preoperative diagnosis of UC and 13 patients with indeterminate colitis (IC) were included in the study. Patients with a preoperatively confirmed diagnosis of Crohn's disease were excluded from this study. 35 patients with UC underwent primary restorative (one-stage) proctocolectomy in an elective surgery setting. These patients had satisfactory nutrition status and low comorbidity. In all but one case, a temporary diverting ileostomy was applied.

38 patients with severe ulcerative colitis and 13 patients with indeterminate colitis were treated with a two-stage surgery in an emergency setting.

39 patients were operated using a laparoscopic technique: 17 patients underwent a primary restorative ileal-pouch procedure and 22 patients underwent two-stage laparoscopic ileal-pouch construction and a pouch-anal anastomosis that followed laparoscopic total colectomy and an end ileostomy. The technical aspects of laparoscopic restorative proctocolectomy have been previously reported in our study [15].

47 patients were operated using an open surgery technique: 18 patients underwent primary restorative proctocolectomy with an ileal pouch-anal anastomosis and 29 patients underwent the two-stage procedure for construction of an ileal-pouch and a pouch-anal anastomosis. 23 of them were operated after the open first-stage colectomy, and 6 patients – after the laparoscopic first-stage colectomy. The reason to choose open surgery for the second-stage procedure for these 6 patients was the presence of abdominal complications after the first-stage laparoscopic colectomy.

The two ileal pouch configurations were used: the S-pouch – in 16 patients and the J-pouch – in 70 patients. The S-pouch was constructed using one-layer continuous suturing of three ileal loops. The length of the S-pouch was about 12 cm and its volume was 120–130 ml. The J-pouch was constructed of two intestinal loops, using two sequential fires of an 80 mm GIA linear stapler. The length of the J-pouch was about 15 cm and its volume was 110–120 ml. For all but one laparoscopically operated patient, construction of a pouch was carried out outside the abdomen (Fig. 1).

Removal of the distal rectum and ileal pouch-anal anastomosis were also performed using two techniques. The first technique included transanal approach for the distal rectum mucosectomy followed by the hand-sewn pouch-anal anastomosis at the site of the dentate line (45 patients). The

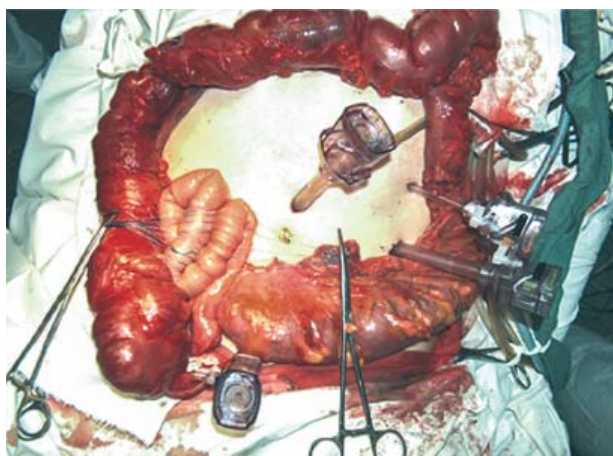


Figure 1. **Removed specimen after laparoscopic total colectomy, and extracorporeal performance of the ileal S-pouch**

second technique was administered as a procedure of double-stapling. The abdominal part of surgery involved a deep mesorectal dissection down to the levator ani muscles. Transection of the rectum was made using a linear endostapler 2–3 cm above the dentate line. The pouch-anal anastomosis was performed using a circular stapler 1.5–2.0 cm above the dentate line (31 patients). The first technique allows complete removal of the rectal mucosa. The second technique ensures the preservation of the anal transitional zone, however, leaving behind a cuff of inflamed distal rectum mucosa.

The combinations of pouch design and the pouch-anal anastomosis techniques used for both laparoscopic and open surgery are shown in Table 1.

Before diverting ileostomy closure, the pouch contrast media filling X-ray (pouchgram) was done,

the anal sphincter resting pressures (RP), and the maximum squeeze anal sphincter pressure (SP) were measured. Follow-up was performed 6 months after surgery, one year after surgery, and annually thereafter.

The short-term (30 days after surgery) and long-term surgical outcomes were prospectively studied.

The analysis of functional outcomes was based on the number of bowel movements per 24 hours, episodes of fecal incontinence, seepage (during day and night), and urgency (inability to delay a bowel movement for more than 15 minutes). Physical examination was performed simultaneously with pouch endoscopy. In case of endoscopic signs of pouchitis, the pouch mucosa biopsy was performed. Instrumental investigation included measurement of anal sphincter pressures, ileal pouch threshold volume, as well as the study of ileal pouch emptying and its residual volume. The threshold volume was determined as the volume of the ileal pouch distension at the time of its filling until the intraluminal pressure reached 25 mm Hg. It was established experimentally that distention of the pouch up to the above-indicated pressure level evokes the urge to evacuate, coincident with the onset of high-pressure waves in the small bowel [34]. The residual pouch volume was calculated as a difference between threshold volume and single pouch evacuation volume.

Pouch failure was defined as the need for permanent fecal diversion with a proximal loop ileostomy with or without pouch excision.

Good functional outcomes were observed in patients with an adequate bowel function: the number of bowel movements was about 5–6 times per day and not more than 2 times at night with no or occasional urgency and good continence [35].

Table 1. **Operative details (a pouch design and anastomosis type) given by the surgical method (laparoscopy or open surgery) and by the stages of performance in 86 patients undergoing one-stage or two-stage restorative proctocolectomy**

Method of surgery	ME+HS sIPAA	ME+HS jIPAA	DS jIPAA
Laparoscopic surgery			
Primary restorative (one-stage) procedure	4	5	8
2nd stage procedure	1	17	4
Open Surgery			
Primary restorative (one-stage) procedure	5	6	7
2nd stage procedure	6	11	12
Total	16	39	31

Note. ME+HS sIPAA — mucosectomy with a handsewn S-ileal pouch-anal anastomosis; ME+HS jIPAA — mucosectomy with a handsewn J-ileal pouch-anal anastomosis; DS jIPAA — double-stapling J-ileal pouch-anal anastomosis.

Statistical Analysis. Categorical variables were compared using the χ^2 or Fisher's exact test as appropriate. Continuous variables were compared using the T-test. Results with a p-value < 0.05 were considered statistically significant; all p-values were two tailed. Correlation of test results to functional outcomes was accomplished with the Pearson correlation coefficient. Statistical analysis was performed using SPSS statistical software.

Results

86 consecutive patients underwent one- or two-stage colectomy, proctectomy, S- or J-pouch-anal anastomosis, and temporary diverting ileostomy closure. In the laparoscopic group, two (5.1%) patients required conversion to open surgery due to bleeding in the pelvis. In both cases, the rectal stump dissection was complicated by pelvic fibrosis, which occurred after the formation of pelvic abscess resulting from the first-stage colectomy. Another major intraoperative complication observed in laparoscopic second-stage restorative surgery included damage to the posterior bladder wall caused by an attempt to dissect the rectal stump from the pelvic

scar tissues. The complication was removed via laparoscopic sewing of the bladder wall.

In general, the second-stage laparoscopic restorative procedure revealed the abdominal cavity almost free of adhesions in 19 (86.4%) of patients after laparoscopic total colectomy. The dense adhesions in the pelvis and complicated dissection of the rectal stump were noted in 3 patients due to pelvic abscess and presacral sinus formation after first-stage surgery (total colectomy). There were two cases of small bowel injury during the second-stage reconstructive surgery in the open surgery group. In all 86 cases the ileal pouch-anal anastomosis was completed successfully.

Bowel function was restored within 26 hours (in the range of 16 to 38 hours) after laparoscopic surgery, and within 38 hours (in the range of 24–60 hours) after open surgery. The difference in the time of bowel function restoration was statistically significant between the groups ($p = 0.004$).

There was no postoperative mortality. Early and late postoperative complications are given in Table 2.

In the laparoscopic group, 4 (10.3%) patients developed early postoperative complications

Table 2. **Surgical morbidity in the laparoscopy and open surgery groups after restorative proctocolectomy (n = 86)**

Index	ME+HS sIPAA			ME+HS jIPAA			DS jIPAA		
	Lap. (n = 5)	Open (n = 11)	Total (n = 16)	Lap. (n = 22)	Open (n = 17)	Total (n = 39)	Lap. (n = 12)	Open (n = 19)	Total (n = 31)
Patients with early complications	2	5	7	1	5	6	1	3	4
Pouch-anastomotic leak	1*	1	2	1	–	1	–	–	–
Incontinence	1	1	2	–	1	1	–	–	–
Pelvic abscess	–	2	2	–	1	1	1	1	2
Wound infection	–	1	1	–	3	3	–	2	2
Patients with late complications	3# (60.0%)	9 (82.0%)	12 (75.0%)	2 (9.0%)	8 (47.0%)	10 (26.0%)	1 (8.0%)	8 (42.0%)	9 (29.0%)
Parapouch presacral sinus	–	1	1	–	–	–	–	1	1
Distal pouch stricture	–	–	–	1	2	3	–	1	1
Small-bowel obstruction	1*	1	2	–	1	1	–	2	2
Pouch-vaginal fistula	–	1	1	–	–	–	–	1	1
Pouch-cutaneous fistula	1	1	2	–	–	–	–	–	–
Pouchitis	0	3	3	2	3	5	6	5	11
Pouch failure	1	1	2	–	1	1	–	1	1

Note. Lap. – laparoscopic.

* There was conversion to laparotomy in this case.

Pouch-anastomosis leak and small bowel obstruction were observed in the same patient.

compared with 13 (27.7 %) patients in the open surgery group, however, the difference was not statistically significant (Fisher exact test value is 0.0579 at $p < 0.05$). In both groups, a pouch design did not cause any difference in the number of patients diagnosed with early complications.

Late postoperative complications occurred in 15 (17.4 %) patients, including 3 (7.7 %) patients in the laparoscopic group and 12 (25.5 %) patients in the open surgery group. All complications were surgically related. The difference in the number of patients with late complications was statistically significant between the groups ($p = 0.0444$).

The total number of early and late mucosectomy complications was significantly higher, 12 (75.0 %) vs. 10 (26.0 %) ($p = 0.0018$) vs. 9 (29.0 %) ($p = 0.0048$), in patients managed with a handsewn S pouch-anal anastomosis than in patients treated with a J-pouch-anal anastomosis or with a double-stapled J-ileal pouch-anal anastomosis.

Pouch failure occurred in 4 patients within a two-year follow-up: in 2 patients after mucosectomy followed by the S-ileal pouch-anal anastomosis, in 1 patient after the open J-pouch-anal anastomosis and in 1 patient after the double-stapled J-ileal pouch-anal anastomosis. In all 4 cases, there were noted some complications related to pouch surgery, including severe anal incontinence (2 patients), presacral sinus (1 patient), and pouch-cutaneous perineal fistula, combined with severe pouchitis (1 patient). There was no statistically significant difference between the groups in terms of a pouch design or anastomosis technique application. In one case, the pouch was removed and terminal ileostomy was done (the patient was suffering from anal

incontinence and severe perineal skin irritation). In three cases, the diverting ileostomy was applied.

Pouchitis was seen in 19 (22.1 %) patients. No relationship between pouch design and pouchitis incidence was found. The main parameters of ileal pouch functioning are presented in Table 3.

Good functional outcomes were observed in 44 (51.0 %) patients. There was no statistically significant difference between laparoscopic (54.0 %) and open surgery (49.0 %) groups of patients ($p = 0.6611$). In terms of pouch-anal construction, there was no statistically significant difference in functional outcomes between the groups: good functional outcomes were seen in 7 (44.0 %) patients after mucosectomy with a handsewn S-ileal pouch-anal anastomosis, in 22 (56.0 %) patients after mucosectomy with a handsewn J-ileal pouch-anal anastomosis, and in 15 (48.0 %) patients after a double-stapled J-ileal pouch-anal anastomosis ($p = 0.6784$). However, a strong negative correlation was found between the ileal pouch threshold volume and the number of bowel movements per 24 hours (Fig. 2).

The threshold volume was increasing significantly during the first six months after ileostomy closure from 120 ± 22 to 235 ± 26 ml ($p < 0.01$) and then it did not change in a twelve-month period. The threshold volume remained almost the same in all groups of patients and did not depend on a pouch design and a method of anastomosis. In terms of a pouch design, the only statistically significant difference was found in the residual volume. It was significantly larger ($p = 0.0219$) in the S-pouch group of patients.

The seepage episodes were observed in 30 (34.8 %) patients. The resting anal sphincter pressure was the only measured parameter which

Table 3. **Functional outcomes of restorative proctocolectomy in 86 patients within 6 months after surgery**

Index	ME+HS sIPAA (n = 16)		ME+HS jIPAA (n = 39)		DS jIPAA (n = 31)	
	Lap. (n = 5)	Open (n = 11)	Lap. (n = 22)	Open (n = 17)	Lap. (n = 12)	Open (n = 19)
BM per 24 hrs (median, range)	8 (5–11)	9 (5–12)	6 (3–9)	5 (4–11)	6 (4–12)	6 (4–13)
Urgency	0	2	2	1	1	2
Seepage						
night	2	1	3	5	2	4
day and night	1	2	3	2	2	3
RP, mm Hg	32 ± 8	36 ± 6	41 ± 8	40 ± 7	38 ± 5	43 ± 9
SP, mm Hg	120 ± 13	118 ± 15	128 ± 14	130 ± 16	135 ± 12	130 ± 12
Threshold volume, ml	165 ± 19	169 ± 17	179 ± 18	182 ± 17	187 ± 16	180 ± 18
Residual volume, ml	83 ± 12	78 ± 10	58 ± 9	60 ± 11	52 ± 9	55 ± 11

Note. Lap. — laparoscopic; BM — bowel movements; RP — resting anal sphincter pressure; SP — maximum squeeze anal sphincter pressure.

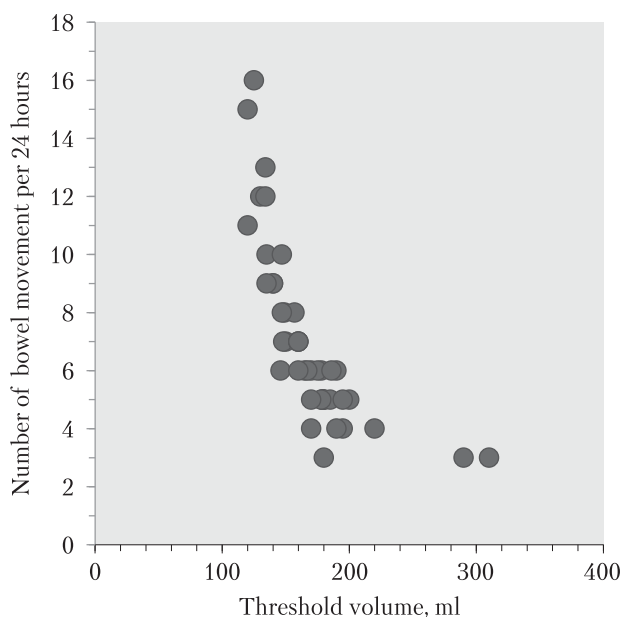


Figure 2. **The correlation between the ileal pouch threshold volume and the frequency of bowel movements** ($r = -0.7347$; $p < 0.0001$)

correlated with the number of day and night seepage episodes ($r = -0.74$; $p < 0.0001$).

In all patients with good functional outcomes, the resting anal pressure was ≥ 30 mm Hg.

The maximum squeeze anal pressure was increasing significantly within six (125 ± 13 mm Hg) and twelve (140 ± 18 mm Hg) months after ileostomy closure. There was no statistically significant difference between the groups. A weak negative correlation ($r = -0.034$; $p < 0.0001$) was found between squeeze anal pressure and the number of urgency episodes.

Discussion

A well-known statement that a good pouch function depends mostly on the patient's sphincter function, pouch volume and compliance [2, 26] appears to be true. The current study proves that neorectal function must be assessed based on anal continence, the ability to control defecation and the number of bowel movements a day. Anal continence depends on the preservation of the anal sphincter function. The damage to the internal anal sphincter may be caused by the disease, age-related alterations, or by a surgeon during mucosectomy. Some authors assert that mucosectomy with a handsewn anastomosis results in poorer continence [4, 5, 10, 12, 13, 21]. Such a tendency was observed in the current study; however, the difference was not statistically significant.

The number of bowel movements depends on pouch capacity and pouch emptying ability [2].

The current study revealed that the pouch threshold volume is the most significant physiological parameter for the assessment of the pouch function. It has a strong negative correlation with the number of bowel movements. Another important stipulation is that the threshold volume was increasing during the first six months after pouch creation and then remained at the same level for years. In the published data, such terms as pouch capacity, pouch functional volume, and pouch distention ability have some differences in their interpretation. It might be explained by the difference in the values concerning a pouch threshold volume and a pouch functional volume described in several studies. Nonetheless, the importance of these parameters for functional results is highly supported [1, 19, 27, 35]. The surgical construction of an ileal pouch must be aimed at achieving an adequately large threshold volume and adequately small residual volume of the pouch at the same time. The S-pouch construction was suggested to be good enough for this task. But it appeared to be technically demanding [7]. And it was associated with a higher morbidity rate [23]. The study affirmed higher morbidity in the S-pouch group. Moreover, the increased residual volume was registered in the S-pouch group. Perhaps, the triplicated design of the S-pouch with a long efferent limb was a possible cause of reduced pouch emptying ability in comparison to the J-pouch. However, the motor characteristics of any pouch reproduce the motility pattern of the small bowel [19, 34]. So, further research should be designed to select patients for different types of neorectal construction based on their small bowel physiology, although pouch physiology remains, to some extent, unexplained [35].

Pouch failure ranges from 5 to 18%, depending upon the length of follow-up [9, 22]. In the biggest data presented by the Fazio group eight years ago [6], pouch failure occurred in 197 (5.5%) patients out of 3707 patients. In the current study, pouch failure was observed in 4 (4.7%) cases and it was caused by surgery-related complications. In the most recent systematic review, which included 30 studies comprising 22,978 patients [9], the pouch failure rate was 7.8% and 10.3% after a median follow-up of ≥ 5 and ≥ 10 years following IPAA, respectively, which means that pouch failure and pouch-related complication rates did not exhibit an improvement over the results from previously published data. It was proved that pouch failure correlated with pelvic sepsis and pouch-related fistula but not with the leaks that completely healed. So, the authors suggest the treatment strategy to prevent acute leaks from becoming chronic leaks [24].

Pouchitis is the most common complication of IPAA but its pathogenesis is still being studied. Current hypotheses suggest that the development of pouchitis might be caused by recurrence of UC in the colon-like ileal reservoir, dysbiosis of ileal pouch microbiota, short chain fatty acid deprivation, mucosal ischemia, genetic susceptibility, and immune dysregulation [32]. Pouchitis can also be influenced by surgical factors, including handsewn anastomosis, anastomosis placement from pectinate line, S-pouch construction [20]. In the current study, pouchitis was seen in 22.1 % of patients. It was not associated with surgical factors or a pouch design. Recent systematic review and meta-analysis [33] support the conclusion that prevalence of pouchitis is much higher in patients with UC than in patients with familial adenomatous polyposis after the same surgical procedures. Does it mean that pouchitis is a disease-specific complication?

The laparoscopic technique for reconstructive proctocolectomy has been widely and extensively used in the last decade. A 90-day postoperative morbidity by decade was 38.3 % vs 50.0 % vs 48.0 % ($p < 0.0001$), but late morbidity decreased from 74.2 % through 67.1 % to 30.0 % ($p < 0.0001$) [31].

The comparison of the laparoscopic and open surgery groups demonstrated no statistically significant difference in terms of long-term and functional outcomes. Reasonable benefits of the laparoscopic approach are found in less surgical morbidity, quick bowel function recovery, and in more favorable conditions to provide second-stage restorative surgery (less adhesion formation in the abdominal cavity). The studies using diagnostic laparoscopy at the time of ileostomy closure [11] as well as the current study confirmed less adhesion formation with a minimally invasive approach. Further advantages of laparoscopic approach rely on robotic surgery, which greatly enhances surgical performance deep in the pelvis during proctectomy and construction of an anastomosis [18].

Conclusions

An important indication for an ileal pouch-anal anastomosis is patient continence. The anal sphincter rest pressure should be ≥ 30 mm Hg.

The ileal pouch capacity may range between 150–250 ml within six months after surgery to obtain good pouch function.

Any pouch design (S or J) ensures the same functional outcomes and has the same risk of pouchitis. In the current study, postoperative surgical complications were more frequently associated with a S-shape construction. In terms of functional outcomes,

there was no statistically significant difference between the groups after transanal mucosectomy followed by a handsewn pouch-anal anastomosis and a double-stapled pouch-anal anastomosis. Laparoscopy and open surgery result in the same morbidity rate and functional outcomes. However, the second-stage surgery was much easier to perform after the application of laparoscopic approach due to less adhesion formation.

ACKNOWLEDGEMENTS

Sincere gratitude to Yuliy Baltaytis, to all my colleagues, nurses, and residents in Kyiv City Hospital No18 for their help in surgery, patients' care, and data collecting. Special thanks to William Norwood for his assistance in laparoscopic training since 1995.

DECLARATION OF INTERESTS

The author declares no conflicts of interest.

REFERENCES

- Bengtsson J, Börjesson L, Lundstam U, Oresland T. Long-term function and manovolumetric characteristics after ileal pouch-anal anastomosis for ulcerative colitis. *Br J Surg*. 2007 Mar;94(3):327-32. doi: 10.1002/bjs.5484. PMID: 17225209.
- Chang S, Shen B, Remzi F. When Not to Pouch: Important Considerations for Patient Selection for Ileal Pouch-Anal Anastomosis. *Gastroenterol Hepatol (N Y)*. 2017;13:466-475.
- Cirocchi R, Morelli U, Arezzo A, et al. Double-stapled anastomosis versus mucosectomy and handsewn anastomosis in ileal pouch-anal anastomosis for ulcerative colitis or familial adenomatous polyposis. *Cochrane Database of Systematic Reviews*. 2019. <https://www.cochranelibrary.com/cdsr/doi/10.1002/14651858.CD011089.pub2/full>.
- Dafnis G. Functional Outcome and Quality of Life after Ileal Pouch-Anal Anastomosis within a Defined Population in Sweden. *Dig Dis*. 2019;37(1):1-10. doi: 10.1159/000491921. Epub 2018 Oct 5. PMID: 30293078
- De Buck van Overstraeten A, Mark-Christensen A, Wasmann KA, et al. Transanal Versus Transabdominal Minimally Invasive (Completion) Proctectomy With Ileal Pouch-anal Anastomosis in Ulcerative Colitis: A Comparative Study. *Ann Surg*. 2017; 266:878.
- Fazio VW, Kiran RP, Remzi FH, et al. Ileal pouch anal anastomosis: analysis of outcome and quality of life in 3707 patients. *Ann Surg*. 2013;257:679-685.
- Fearnhead NS, Lee MJ, Acheson AG, Worley G, Faiz OD, Brown SR. Variation in practice of pouch surgery in England using SWORD data to cut to the chase and justify centralization. *Colorectal Dis*. 2018;20:597-605.
- Heald RJ, Allen DR. Stapled ileo-anal anastomosis: a technique to avoid mucosal proctectomy in the ileal pouch operation. *Journal of British Surgery*. 1986;73:7:571-572.
- Heuthorst L, Wasmann K, Reijntjes M, et al. Ileal Pouch-anal Anastomosis Complications and Pouch Failure. *Annals of Surgery*. 2021 June; 2(2). doi: 10.1097/AS9.0000000000000074.
- Holder-Murray J, Fichera A. Anal transition zone in the surgical management of ulcerative colitis. *World J Gastroenterol*. 2009; 15:769.
- Hull TL, Joyce MR, Geisler DP, Coffey JC. Adhesions after laparoscopic and open ileal pouch-anal anastomosis surgery for ulcerative colitis. *Br J Surg*. 2012;99:270-275.
- Ishii H, Kawai K, Hata K, et al. Comparison of Functional Outcomes of Patients Who Underwent Hand-Sewn or Stapled Ileal Pouch-Anal Anastomosis for Ulcerative Colitis. *Int Surg*. 2015 Jul;100(7-8):1169-76. doi: 10.9738/INTSURG-D-15-00012.1. PMID: 26595489.
- Jonker JE, Hofker HS, Trzpis M, Broens PMA. Fecal continence outcomes are associated with the type, height, and stage procedure of ileal pouch-anal anastomosis. *Int J Colorectal Dis*. 2020 Sep;35(9):1749-1757. doi: 10.1007/s00384-020-03626-7. Epub 2020 May 30. PMID: 32474709; PMCID: PMC7415023.

14. Kmiot WA, Keighley MRB. Totally stapled abdominal restorative proctocolectomy. *Br J Surg*. 1989 Sep;76(9):961-964. <https://doi.org/10.1002/bjs.1800760931>.
15. Kucher MD, Bilianskyi IS, Kryvoruk MI, Tkachenko FH, Stelmakh AI. Laparoscopic Proctocolectomy for Ulcerative Colitis and Crohn's Disease of the Large Intestine: Short-Term and Long-Term Outcomes of 53 Cases. *Galician Medical Journal*, 2016; 23(3). <https://doi.org/10.21802/gmj.2016.3.25>.
16. Lask, A., Biebl, M., Ditttrich, L. et al. Safety of transanal ileal pouch-anal anastomosis for ulcerative colitis: a retrospective observational cohort study. *Patient Saf Surg*. 2021;15:31. <https://doi.org/10.1186/s13037-021-00306-5>.
17. Lightner AL, Grass F, McKenna NP, et al. Short-term postoperative outcomes following robotic versus laparoscopic ileal pouch-anal anastomosis are equivalent. *Tech Coloproctol* 2019; 23:259.
18. Lightner AL, Kelley SR, Larson DW. Robotic Platform for an IPAA. *Dis Colon Rectum* 2018; 61:869.
19. Lightner AL, Mathis KL, Dozois EJ, et al. Results at Up to 30 Years After Ileal Pouch-Anal Anastomosis for Chronic Ulcerative Colitis. *Inflamm Bowel Dis*. 2017; 23:781.
20. Lipman JM, Kiran RP, Shen B, Remzi F, Fazio VW. Perioperative factors during ileal pouch-anal anastomosis predict pouchitis. *Dis Colon Rectum*. 2011;54:311.
21. Litzendorf ME, Stucchi AF, Wishnia S, et al. Completion mucosectomy for retained rectal mucosa following restorative proctocolectomy with double-stapled ileal pouch-anal anastomosis. *J Gastrointest Surg*. 2010; 14:562.
22. Mark-Christensen A, Erichsen R, Brandsborg S, et al. Pouch failures following ileal pouch-anal anastomosis for ulcerative colitis. *Colorectal Dis*. 2018; 20:44-52. <https://doi.org/10.1111/codi.13802>.
23. Mukewar S, Wu X, Lopez R, Bo S. Comparison of long-term outcomes of S and J pouches and continent ileostomies in ulcerative colitis patients with restorative proctocolectomy-experience in subspecialty pouch center. *Journal of Crohn's and Colitis*. 2014 Oct; 8(10):1227-1236, <https://doi.org/10.1016/j.crohns.2014.02.019>.
24. Ng KS, Gonsalves SJ, Sagar PM. Ileal-anal pouches: A review of its history, indications, and complications. *World J Gastroenterol*. 2019 Aug 21;25(31):4320-4342. doi: 10.3748/wjg.v25.i31.4320. PMID: 31496616; PMCID: PMC6710180.
25. Ng SC, Shi HY, Hamidi N, et al. Worldwide incidence and prevalence of inflammatory bowel disease in the 21st century: a systematic review of population-based studies. *Lancet*. 2018;390(10114):2769-78. [https://doi.org/10.1016/S0140-6736\(17\)32448-0](https://doi.org/10.1016/S0140-6736(17)32448-0).
26. Nicholls R.J. Pezim M.E. Restorative proctocolectomy with ileal reservoir for ulcerative colitis and familial adenomatous polyposis: a comparison of three reservoir designs. *Br J Surg* 1985;72:470-474.
27. Oh SH, Yoon YS, Lee JL, et al. Postoperative changes of manometry after restorative proctocolectomy in Korean ulcerative colitis patients. *World J Gastroenterol*. 2017 Aug 21;23(31):5780-5786. doi: 10.3748/wjg.v23.i31.5780. PMID: 28883704; PMCID: PMC5569293.
28. Parks AG, Nicholls RJ. Proctocolectomy without ileostomy for ulcerative colitis. *Br Med J*. 1978; 2:85.
29. Parragi L, Fournier N, Zeitz J, et al; Swiss IBD Cohort Study Group. Colectomy Rates in Ulcerative Colitis are Low and Decreasing: 10-year Follow-up Data From the Swiss IBD Cohort Study. *J Crohns Colitis*. 2018 Jun 28;12(7):811-818. doi: 10.1093/ecco-jcc/jjy040. PMID: 29617750.
30. Peters WR. Laparoscopic total proctocolectomy with creation of ileostomy for ulcerative colitis: report of two cases. *J Laparosc Surg*. 1992 Jun;2(3):175-8. doi: 10.1089/lps.1992.2.175. PMID: 1535812.
31. Remzi FH, Lavryk OA, Ashburn JH, et al. Restorative proctocolectomy: an example of how surgery evolves in response to paradigm shifts in care. *Colorectal Dis* 2017;19:1003-1012.
32. Schieffer KM, Williams ED, Yochum GS, Koltun WA. Review article: the pathogenesis of pouchitis. *Aliment Pharmacol Ther*. 2016 Oct;44(8):817-35. doi: 10.1111/apt.13780. Epub 2016 Aug 24. PMID: 27554912; PMCID: PMC5785099.
33. Sriranganathan D, Kilic Y, Quraishi MN, Segal JP. Prevalence of pouchitis in both Ulcerative Colitis and Familial Adenomatous Polyposis: a systematic review and meta-analysis. *Colorectal Disease: the Official Journal of the Association of Coloproctology of Great Britain and Ireland*. 2021 <https://doi.org/10.1111/codi.15995>.
34. Stryker SJ, Kelly KA, Phillips SF, Dozois RR, Beart RW Jr. Anal and neorectal function after ileal pouch-anal anastomosis. *Ann Surg*. 1986 Jan;203(1):55-61.
35. Sunde ML, Ricanek P, Øresland T, et al. Determinants of optimal bowel function in ileal pouch-anal anastomosis-physiological differences contributing to pouch function, *Scandinavian Journal of Gastroenterology*. 2018; 53:1, 8-14. doi: 10.1080/00365521.2017.1390601.
36. Utsunomiya J, Iwama T, Imajo M, et al. Total colectomy, mucosal proctectomy, and ileoanal anastomosis. *Dis Colon Rectum*. 1980; 23:459-466.

Перспективний аналіз післяопераційних і функціональних результатів у 86 хворих на неспецифічний виразковий коліт, які перенесли тотальну проктоколектомію з тонкокишковим резервуарно-анальним анастомозом

М. Кучер

Національний медичний університет імені О. О. Богомольця, Київ

Тотальна проктоколектомія з формуванням резервуару з клубової кишки і резервуарно-анального анастомозу — є операцією вибору для переважної більшості хворих на неспецифічний виразковий коліт. Розбіжності в рекомендаціях існують, головним чином, у виборі дизайну резервуару і способу його анастомозування з анальним каналом. Продовжується дискусія і щодо переваг у використанні лапароскопічних технологій для таких втручань.

Мета — проаналізувати безпосередні, віддалені і функціональні результати тотальної проктоколектомії в залежності від способу формування неоректуму (три варіанти конструкції резервуару) і від методу оперування (лапароскопічний чи відкритий).

Матеріали та методи. Тотальна проктоколектомія зі створенням неоректуму у один або два етапи була виконана у 86 хворих на неспецифічний виразковий коліт. Використовувалися дві конфігурації тонкокишкових резервуарів: S-подібної форми (16 пацієнтів) і J-подібної форми (70 пацієнтів). Формування резервуарно-анального анастомозу відбувалося теж у два способи: ручним накладанням окремих вузлових швів трансанально на рівні зубчастої лінії після мукозектомії (45 пацієнтів) і бістеплерним механічним швом на 1,5 см вище рівня зубчастої лінії (31 пацієнт). Операції виконувалися лапароскопічним способом у 39 пацієнтів, відкритим — у 47. Аналізувалися безпосередні, віддалені, а також функціональні результати операції.

Результати. Післяопераційної летальності не було. Ранні післяопераційні ускладнення траплялися частіше у відкритій групі (27,7%) аніж у лапароскопічній (10,3%), проте різниця виявилася статистично не значущою (точний критерій Фішера — 0,0579; $p < 0,05$). Неспроможність резервуару мала місце у чотирьох випадках. Черевна порожнина була практично вільною від злук на момент виконання відновного етапу втручання після виконання тотальної колектомії лапароскопічним способом у 86,4% хворих. Частота ранніх і віддалених післяопераційних ускладнень після формування S-подібних резервуарів була достовірно більшою, аніж після формування J-подібних резервуарів ($p = 0,0018$). Серед характеристик неоректуму виявлено чітку кореляцію з функціональними результатами для двох показників: порогового об'єму резервуару і числом випорожнень за добу ($r = -0,7347$; $p < 0,0001$), а також тонічного зусилля анального сфінктера і частотою епізодів нетримання вдень і вночі ($r = -0,74$; $p < 0,0001$). Епізоди нетримання мали місце у 30 (34,8%) пацієнтів.

Висновки. Найважливішими чинниками вдалого функціонування неоректуму виявилися: тонічне зусилля анального сфінктера — не менше 30 мм рт.ст. і пороговий об'єм резервуару — у межах 150—250 мл. Резервуари J- чи S- подібної будови позначилися схожими функціональними результатами, проте післяопераційні ускладнення траплялися частіше серед пацієнтів з резервуарами S-подібної форми. Статистично достовірної різниці щодо післяопераційних ускладнень і функціональних результатів між групами хворих, оперованих лапароскопічно і відкритим способом, не виявлено, проте виконання наступного, відновного, етапу хірургічного лікування після лапароскопічної проктоколектомії було значно легшим, з огляду на мінімальний злуковий процес.

Ключові слова: неспецифічний виразковий коліт, лапароскопічна відновна проктоколектомія, тонкокишковий резервуар, функціональні результати.

Автори

✉ Кучер Микола Дмитрович: nickkucher45@yahoo.com

М. Д. Кучер, д. мед. н., проф., професор кафедри хірургії № 1, <https://orcid.org/0000-0001-8820-2923>

FOR CITATION

■ Kucher M. Prospective analysis of surgical and functional outcomes after total proctocolectomy with ileal pouch-anal anastomosis in 86 patients with ulcerative colitis. General Surgery (Ukraine). 2022;1:19-27. <http://doi.org/10.30978/GS-2022-1-19>.