

UDC: 616.24-006.04-018:577.218
[https://doi.org/10.32345/USMYJ.1\(128\).2022.6-18](https://doi.org/10.32345/USMYJ.1(128).2022.6-18)

Received: January 09, 2022

Accepted: February 19, 2022

Correlation between expression of immunohistochemical markers and morphology in lung neuroendocrine neoplasms

Chytaieva Halyna¹, Shkurupii Bohdana¹, Zakhartseva Liubov^{1,2}

¹ Department of Pathological Anatomy, Bogomolets National Medical University, Kyiv, Ukraine

² Department of Pathology of Kyiv City Oncological Center, Kyiv, Ukraine

Address for correspondence:

Chytaieva Halyna

E-mail: h.chytaieva@gmail.com

Abstract: lung neuroendocrine neoplasms embrace rather heterogeneous and rare malignancies which are usually characterized by nonspecific, “blurred” clinical signs thus complicating correct diagnosis or seriously delays it. Pulmonary neuroendocrine neoplasms accurate diagnostics and classification need to be improved. Histological examination should be supplemented by immunohistochemical tests to verify the neuroendocrine component, assess proliferative index of tumor cells, and confirm its bronchopulmonary origin. Immunohistochemistry is especially important in case of small or crushed biopsies, which account more than 50% of all specimens in lungs neuroendocrine neoplasms. Modern classification of lung neuroendocrine neoplasms and their grading are based on morphological criteria. Immunohistochemical markers expression is quite variable in different histological subtypes of bronchopulmonary neuroendocrine neoplasms, often data are descriptive, and correlation with morphology is studied insufficiently. The aim of this study was to define any significant correlation between different immunohistochemical markers expression, necrosis, proliferative index (Ki-67 ratio), and tumor grade in broncho-pulmonary neuroendocrine neoplasms. Histological blocks of lung neuroendocrine neoplasms from 113 unique patients (36 resections and 77 biopsies (54.5% of biopsies appeared to be small or crushed) were used in this study. The sample comprised 91 male and 22 female patients; the mean age was 59.2, CI 95% (56.9–61.4) years (from 19 to 77 years). Histological examination (including neuroendocrine morphology, necrosis, and grade) was provided in all cases. Also, immunohistochemistry, using Chr A, Syn, CD56, TTF-1, CK7, and Ki-67 before chemotherapy was performed. All morphological and immunohistochemical data were assessed by two different independent pathologists without the access to patient’s clinical data. All the observations were classified based on 2021 WHO Thoracic Tumors Classification. The sample was censored. We used nonparametric statistics (Spearman’s rank correlation) for this study. It was found that Chr A expression strongly ($p < 0.05$) correlated with immunohistochemical markers of primary lung malignancies (TTF-1 and CK7) that are mainly expressed in highly and moderately differentiated neuroendocrine neoplasms. Also, positive expression for TTF-1 and CK7 correlated with each other ($p < 0.01$). There was a strong negative correlation ($p < 0.05$) between Chr A staining and necrosis presence and its severity; between Chr A expression and tumor cells proliferation (Ki-67 ratio) ($p < 0.01$); and between Chr A labeling and tumor grade ($p < 0.01$). The correlation of immunohistochemical markers expression with necrosis,

Ki-67 ratio and tumor grade was significant only for Chr A. All other tested options, for other markers were not statistically significant. It was defined that decrease or loss of Chr A expression reliably indicates tumors progression. Chr A expression can be used as an additional tool for grading of lung neuroendocrine neoplasms.

Key words: neuroendocrine tumors, histology, immunohistochemistry, lung neoplasms, Chromogranin A.

Introduction

Neuroendocrine neoplasms (NENs) are a heterogeneous group of malignancies that arise from neuroendocrine (NE) cells and mostly commonly originate from gastrointestinal tract and lungs. Despite rarity (0.5–2% of all malignancies occurring in adults), the incidence rates of NENs in last 3 decades continue to increase worldwide, mainly because of greater awareness of the disease and increased accuracy of the diagnostics (Broder et al., 2018; Hotland, Kaltsas, & de Herder, 2019; Naheed, Holden, & Pelosi, 2019; Oronsky et al., 2017; Singh et al., 2017).

Bronchopulmonary NENs account approximately one-quarter to one third of all primary lung tumors (Broder et al., 2018; Hendifar, Marchevsky, & Tuli, 2017; Hung, 2019; Pericleous et al., 2018).

Although lung NENs share morphological, immunohistochemical (IHC), and ultrastructural features, they are currently classified into four histological variants: typical carcinoid (TC), atypical carcinoid (AC), large cell neuroendocrine carcinoma (LCNEC), and small cell lung carcinoma (SCLC) — ranging from quite indolent lesions (neuroendocrine tumors (NETs)) to extremely aggressive neuroendocrine carcinomas (NECs) with very poor prognosis (Borczuk, 2020; Gkolfinopoulos, Tsapakidis, & Kountourakis, 2017; La Rosa & Uccella, 2021; Pelosi et al., 2017; Wang et al., 2019). TC is 1% of all thoracic malignancies and about 9% of all lung NENs, AC accounts 0.1% and 1%, LCNEC — 4.8% and 15%, and SCLC — 13.9% and 75% respectively (Melosky, 2017; Naheed et al., 2019).

Many patients with lung NENs are asymptomatic at the time of diagnosis, or present with a few “blurred”, nonspecific symptoms that in more than 60% of cases mimic respiratory conditions (asthma or chronic obstructive pulmonary disease), thus complicating correct diagnosis or seri-

ously delays it. Moreover, more than 95% of lung NENs are nonfunctional and don't show hormonal symptoms, and consequently their diagnostics may be accidental or related to mass effect of tumor or metastatic lesion (Basuroy, Bouvier, & Srirajaskanthan, 2018; Hendifar et al., 2017).

A great fraction of well-differentiated NETs behaves as low-grade cancers. Malignant potential is characteristic for all lungs NENs. Even for TC, which cause metastatic lesions in 10% of cases; the chance of distant spread at AC is estimated 20%, and the risk of metastasis is much higher at LCNEC — about 50% and at LCNEC — 70% (Melosky, 2017; Rindi & Inzani, 2020).

Key features for accurate broncho-pulmonary NENs diagnostics are characteristic organoid growth pattern (rosettes, trabeculae, ribbons, festoons, lobular nests, palisading); mitotic rate and necrosis that plays an important role in lung NENs grading and prognosis (Inzani, Petrone, & Rindi, 2017; Pelosi et al., 2017; Sugimoto et al., 2020). (see **fig. 1**).

As morphological features are overlapping for NETs and NECs, the IHC confirmation is mandatory for lung NENs diagnosis. Moreover, some high-grade NENs cannot be detected by H&E examination, especially in small and crushed biopsies, and requires ICH. Also, biomarkers may help to exclude histologic mimics (poorly differentiated squamous cell carcinoma, small round cell tumor, hematologic malignancies, etc.), especially when facing with NECs. Briefly, IHC is used to characterize the aggressiveness of lung NENs by assessing the proliferation index (Ki-67), as well as NE differentiation (NE markers expression others than NSE — the best antibody panel here is Chr A, Syn, and CD56) and to find out NENs primary location (using TTF-1 and CK7) (Gkolfinopoulos et al., 2017; Inzani et al., 2017; Kriegsmann et al., 2021; Kyriakopoulos, Mayroei, & Alexandraki, 2018; La Rosa &

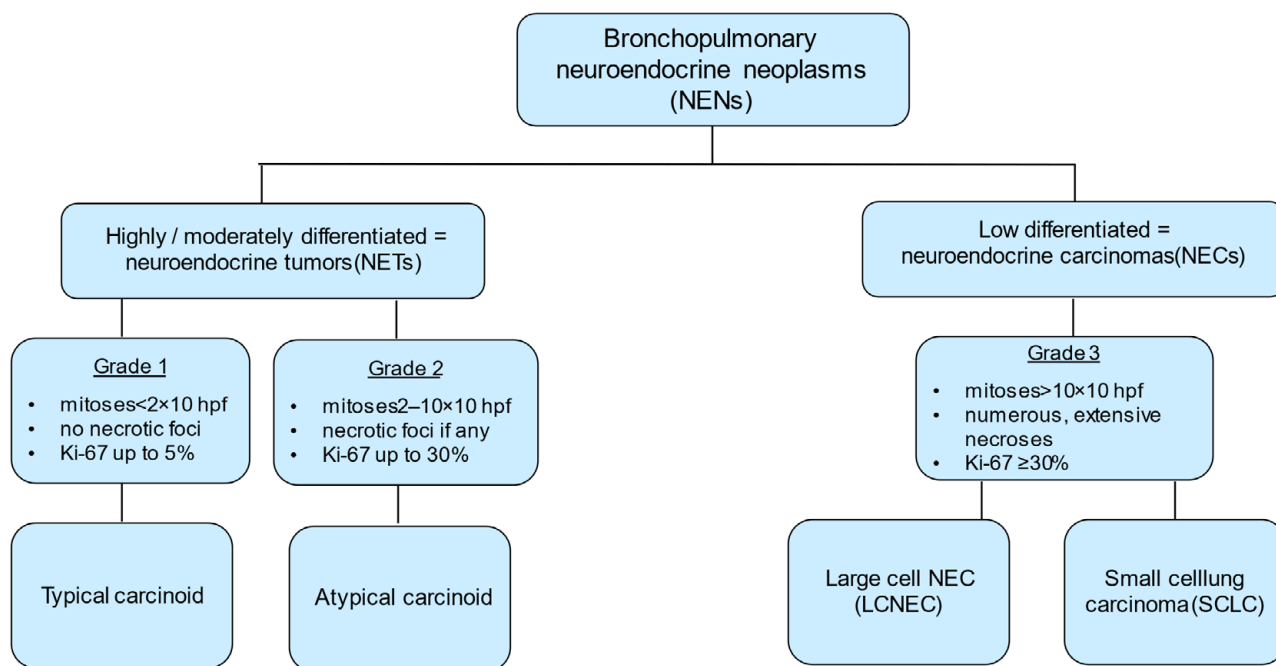


Fig. 1. Main diagnostic characteristics of lung NENs (Melosky, 2017; Naheed et al., 2017; IARC, 2021).

Uccella, 2021; Pelosi et al., 2017; Yatabe et al., 2019).

Ki-67 is often required by oncologists for grading assessment / prognosis and for therapy planning. In pulmonary NENs the main diagnostic role of Ki-67 is to distinguish carcinoids from high-grade NECs, especially in small / crushed biopsies, when the amount of tissue is limited. Also, Ki-67 is regarded as more accurate measure of cell proliferation in comparison to mitotic count, as it represents the larger portion of the cell cycle (from mid-G1 through S and G2 phases) and can “catch” proliferating cells that do not show mitotic figures (Garg, Bal, & Singh, 2019; Hung, 2019; Marchevsky, Hendifar, & Walts, 2018; Naheed et al., 2019). Ki-67 is required for grading assessment (as grade is considered the dominant driver of prognosis in patients with lung NENs) (Jackson et al., 2020).

Syn and Chr A are true markers of NE differentiation, with the former considered more sensitive and the latter more specific. Syn is associated with synaptic-like vesicles, while Chr A — with dense core and chromaffin granules (Bellizzi, 2020). The expression of NE markers is well known to be variable among different histological subtypes of lung NENs. Usually, more Chr A

can be detected in carcinoids and LCNECs than in SCLCs where it is presented in much fewer cases. The same trend is also seen with Syn. On the contrary, CD56 is the most sensitive for the diagnosis of high-grade NECs, although 5–10% of SCLCs can be negative for all three NE markers. About 20% of low-grade NECs are positive only for one NE marker. The use of IHC panel of NE markers allows to detect any amount of positive membrane staining of any of these markers in tumor samples with NE morphological features (Di Giacinto et al., 2018; Gkolfinopoulos et al., 2017; Sadrzadeh & Kline, 2017; Yatabe et al., 2019).

CK7 and TTF-1 help to distinguish lung and gastrointestinal NENs. These markers are moderately sensitive but highly specific for diagnosing of primary pulmonary NENs (Cai, Banner, & Odze, 2001). TTF-1 is a critical single marker for primary lung cancer, and 63–75% of adenocarcinomas are TTF-1-positive, some of them show NE component (if it is $\geq 30\%$ — the neoplasm is considered NEN). TTF-1 is a useful marker of pulmonary origin in TCs and ACs, but only positive in about 50% of cases, and the staining is commonly focal and rather weak. CK7 is widely used to distinguish lung tumors, including

carcinoids from colon cancer (up to 70% of primary bronchopulmonary malignancies show positive CK7 staining, while most colon tumors are CK7-negative) (Cadioli, Rossi, & Colby, 2014; Pelosi, Scarpa, & Sonzogni, 2016; Umakanthan, Chalapathi Rao, & Mohammed, 2021; Yatabe et al., 2019).

At lung NENs morphological examination should be confirmed by IHC tests. Much attention is paid to the expression of IHC markers, however, there is little and contradictory data on how it correlates with the key diagnostic points of lung NENs: with necrosis, proliferative activity, and tumor grade.

Aim

The aim of the study is to define level of correlation between different IHC markers expression, necrosis, proliferative index (Ki-67 ratio), and tumor grade in broncho-pulmonary NENs.

Methods

Retrospective and prospective study was conducted. We used FFPE blocks of lung NENs from 113 unique patients who have been treated in Kiev City Clinical Oncological Center in 2010–2020. There were 36 resections and 77 biopsies; 42 (54.5%) biopsies appeared to be small or crushed. Histological examination (including characteristic NE morphology, necrosis, and grade) was provided in all cases.

We used standard histological technique. Tissue samples were placed in a formalin 10% solution for at least 24 hours. Then specimens were dehydrated in a series of alcohol solutions of increasing concentration as a prerequisite for subsequent embedding in paraffin blocks. 5 µm slides were made from each block, dewaxed and stained with haematoxylin and eosin. The slides were examined with standard light microscopy. In the current study, we used microscope Carl Zeiss® Primo Star with computed photo fixation.

Also, IHC, using Chr A, Syn, CD56, TTF-1, CK7, and Ki-67 before chemotherapy was performed. All morphological and IHC data were assessed by two different independent pathologists without the access to patient's clinical data. All the observations were classified based on 2021 WHO Thoracic Tumors Classification (IARC, 2021).

The study was approved by the Commission on Bioethical examination of Bogomolets Na-

tional Medical University (protocol #118, 18 Jan 2019).

To determine IHC markers' expression, we used monoclonal antibody anti-Ki-67, clone MIB-1 (Dako, USA); monoclonal antibody anti-Chr A, clone SP12 (Invitrogen, Thermo Fisher Scientific, USA); monoclonal antibody anti-Syn, clone DAK-SYNAP (Dako, Denmark); monoclonal mouse anti-human CD56, clone 123C3 (Dako, Denmark); monoclonal mouse anti-TTF-1 clone 8G7G3/1 (Dako, Denmark); monoclonal antibody anti-human CK7, clone OV-TL 12/30 (Dako, Denmark).

Chr A and Syn were used in all cases. If the NE labeling was doubtful or negative, additional CD56 marker was applied (in 18 (15.9%) specimens).

TTF-1 and CK7 were used to confirm the lung origin of the NENs, especially in cases with unknown primary tumor site.

Ki-67 index was evaluated as a percentage of tumor cells showing positive nuclear labeling. For each sample, 5 microscopic fields at ×200 magnification were selected, and 100 tumor cells in each field were counted to assess the staining intensity and percentage of positive cells. Ki-67 up to 5% considered Grade 1, 5–30% — Grade 2, and >30% — Grade 3 (IARC, 2021).

All other IHC markers (TTF-1, CK7, Chr A, Syn, CD56) were detected by membranous / cytoplasmic staining. It was a qualitative reaction from negative to weak (1+) or strong (2+), but any staining considered positive.

All calculations were made using Microsoft Excel. Statistical analysis was performed using the Program EZR 1,35 (R statistical software version 3.4.3, R Foundation for Statistical Computing, Vienna, Austria).

The sample was censored. We used nonparametric statistics for this study. Spearman's rank correlation was applied to reveal links between IHC markers expression, necrosis, proliferative index (Ki-67), and tumor grade (Gur'yanov et al., 2018).

Results

Our study comprised 91 male and 22 female patients; male / female ratio was 4.1:1. The mean age in the sample was 59.2, CI 95% (56.9–61.4) years. Youngest patient — a young woman aged

Variables		Lung NENs (113 observations)			
		NETs		NECs	
		Grade 1	Grade 2	Grade 3	
		TC	AC	LCNEC	SCLC
Cases		9 (8.0%)	40 (35.4%)	20 (17.7%)	44 (38.9%)
Male / female		6 / 3	29 / 11	17 / 3	39 / 5
Patients age, years		56.8 CI 95% (46.1–67.5)	53.4 CI 95% (48.8–58.1)	62.7 CI 95% (59.7–65.8)	63.2 CI 95% (60.7–65.7)
Necrosis, cases	no	7 (77.8%)	15 (37.5%)	3 (15.0%)	8 (18.2%)
	focal	2 (22.2%)	9 (22.5%)	8 (40.0%)	11 (25.0%)
	extensive	—	16 (20.4%)	9 (45.0%)	25 (56.8%)
Ki-67, %		4.1 CI 95% (3.3–4.9)	15.8 CI 95% (14.1–17.4)	54.4 CI 95% (45.5–63.2)	63.4 CI 95% (58.5–68.2)
IHC markers positive expression	TTF-1	7 (77.8%)	21 (52.5%)	9 (45.0%)	19 (43.2%)
	CK7	5 (55.6%)	27 (67.5%)	14 (70.0%)	24 (54.5%)
	Chr A	9 (100.0%)	34 (85.0%)	13 (65.0%)	27 (61.4%)
	Syn	8 (88.9%)	31 (77.5%)	15 (75.0%)	32 (72.7%)

Table 1. Main characteristics of the sample.

19 years diagnosed with AC, the eldest patient — male, aged 77 years, with SCLC. At TC group patient's age ranged from 30 to 74 years, at AC — from 19 to 76 years, at LCNEC — from 48 to 73 years and ant SCLC — from 38 to 77 years. In group of AC there were 9 patients under 40 years, and 4 (44%) of them were female. Main variables of the sample are given in the **table 1**.

The differentiation of lung NENs was a step-wise process on a constellation of histological and IHC traits alongside the evaluation of proliferative activity and necrosis extent.

Most cases were showing characteristic NE architecture — organoid “nests”, trabeculae, and rosettes and all were positive for one or two NE markers.

Only in a few samples of TC small necrotic foci were detected. In the NENs tissue of the 2 and 3 grade more foci of necrosis were seen, and their area extended.

In the current study Ki-67 indicator ranged from 2 to 5% in TC (Grade 1), from 6 to 25% in AC (Grade 2), and from 30 to 100% in LCNEC, and from 30 to 95% — in SCLC that corresponded to Grade 3. And Ki-67 ratio run high significantly as the degree of tumor cells differentiation decreased.

56 (49.6%) specimens in the sample showed positive TTF-1 staining: in 21 (18.6%) cases the labeling was weak, in 35 (31.0%) — strong or moderate. 70 (61.9%) samples were CK7-positive: in 12 (10.6%) of them the staining was weak, in 58 (51.3%) — moderate to strong.

Chr A expression was detected in 83 (73.5%) cases, Syn — in 86 (76.1%). Low Chr A expression was observed in 19 (16.8%) specimens, Syn — in 14 (12.4%). Moderate or pronounced expression of Chr A was seen in 64 (56.6%) cases, of Syn — in 72 (63.7%). 24 (37.5%) low-differentiated malignancies were Chr A-negative, 17 (26.56%) — Syn-negative; 7 (10.9%) NECs were negative for these both NE markers. Chr A expression decreased and disappeared rather quickly while tumor progressing, but some high-grade NECs still showed Syn staining.

Biomarker CD56 was used if staining for Chr A and Syn was negative or dubious (especially in crushed biopsies) — in 18 (15.9%) specimens. CD56 appeared to be positive in all these cases, while in 7 (38.9%) of them neither Chr A no Syn expression was detected (6 SCLC / 1 LCNEC).

Typical morphology and immunoprofile of the lung NENs are given on **fig. 2** and **3**.

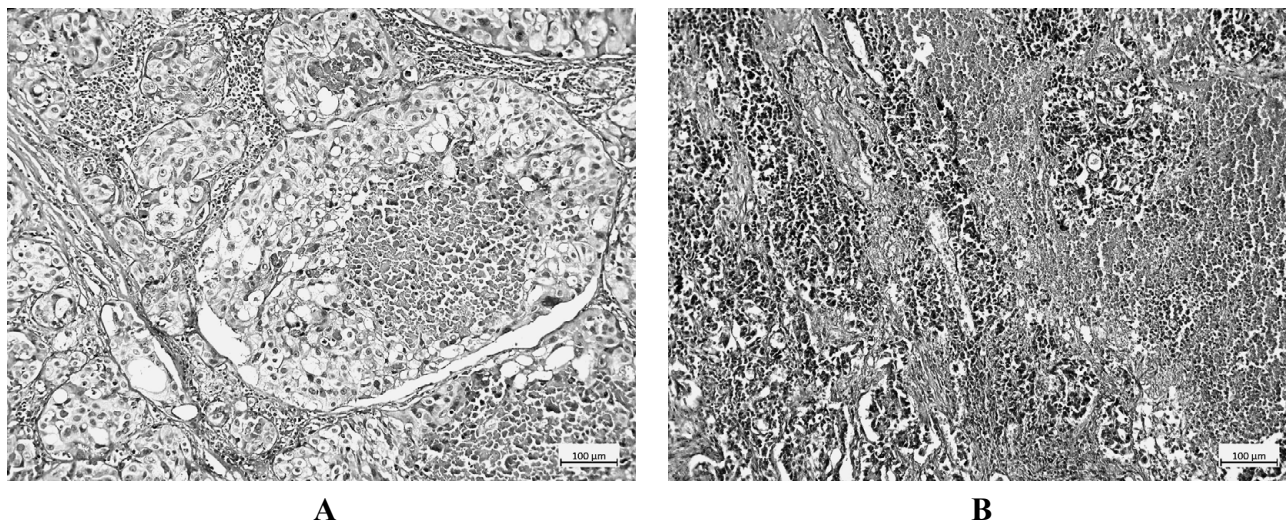


Fig. 2. Micropreparation. High grade NECs (grade 3). Note the characteristic organoid pattern of growth and numerous foci of necrosis. A — LCNEC, metastasis in the lymph node, H&E staining, $\times 200$. “Nests” of epithelioid cells with large irregular nuclei, and abundant eosinophilic cytoplasm. A few mitotic figures and necrosis are seen in the center of some of the tumor “nests”. B — SCLC, H&E staining, $\times 200$. “Nests” and “ribbons” of small cells with irregular hyperchromatic nuclei and scant cytoplasm. Extent foci of necrosis.

We observed a strong correlation between Chr A expression and some other ICH markers, including Ki-67, and necrosis presence and severity, and tumor grade.

Chr A positive reaction correlated with ICH markers of primary lung malignancies that are mainly expressed in highly and moderately differentiated lung NENs. The strong correlation between Chr A expression and positive staining for TTF-1 and CK7 was revealed (Spearman's rank correlation, $\rho=0.287$, $p=0.00852$ and $\rho=0.254$, $p=0.00147$ respectively). Also, positive expression for TTF-1 and CK7 correlated with each other (Spearman's rank correlation, $\rho=0.501$, $p=0.0000352$).

There was a strong negative correlation between positive staining for Chr A and necrosis presence and its extent (Spearman's rank correlation, $\rho=-0.228$, $p=0.0193$ and $\rho=-0.366$, $p=0.000121$ respectively).

Also, we detected a strong negative correlation between Chr A expression and tumor cells proliferation (Ki-67 ratio) (Spearman's rank correlation, $\rho=-0.363$, $p=0.0000896$).

A strong negative correlation was observed between Chr A expression and tumor grade (Spearman's rank correlation, $\rho=-0.356$, $p=0.000128$).

All other tested options, for other ICH markers were not statistically significant.

Discussion

Lung NENs are rare (less than 1% of all newly diagnosed malignancies) and heterogeneous tumors. Diagnosis of lung NENs rate has increased significantly over the past few decades. The lung is the second most common site for NENs after the digestive tract. Bronchopulmonary NENs account for approximately 22–27% of all NENs and up to 20–25% of all primary lung malignancies in adults. Lung NENs are divided into 4 histological subtypes from low-grade NETs (TC and AC) to high-grade NECs (LCNEC and SCLC), that require different management strategies. In general, NECs have aggressive behavior, while the course of NETs might be more indolent with higher survival rates, but bronchial carcinoids are also malignant and have the potential to metastasize. Most of the lung NENs are nonfunctional, and associated symptoms are single and nonspecific or even absent until more advanced stages which can result in wrong or delayed diagnosis. About 40% of cases are metastatic at the presentation which worsens the prognosis significantly; the 5-year survival rate for stage IV disease is less than 5%. The issues

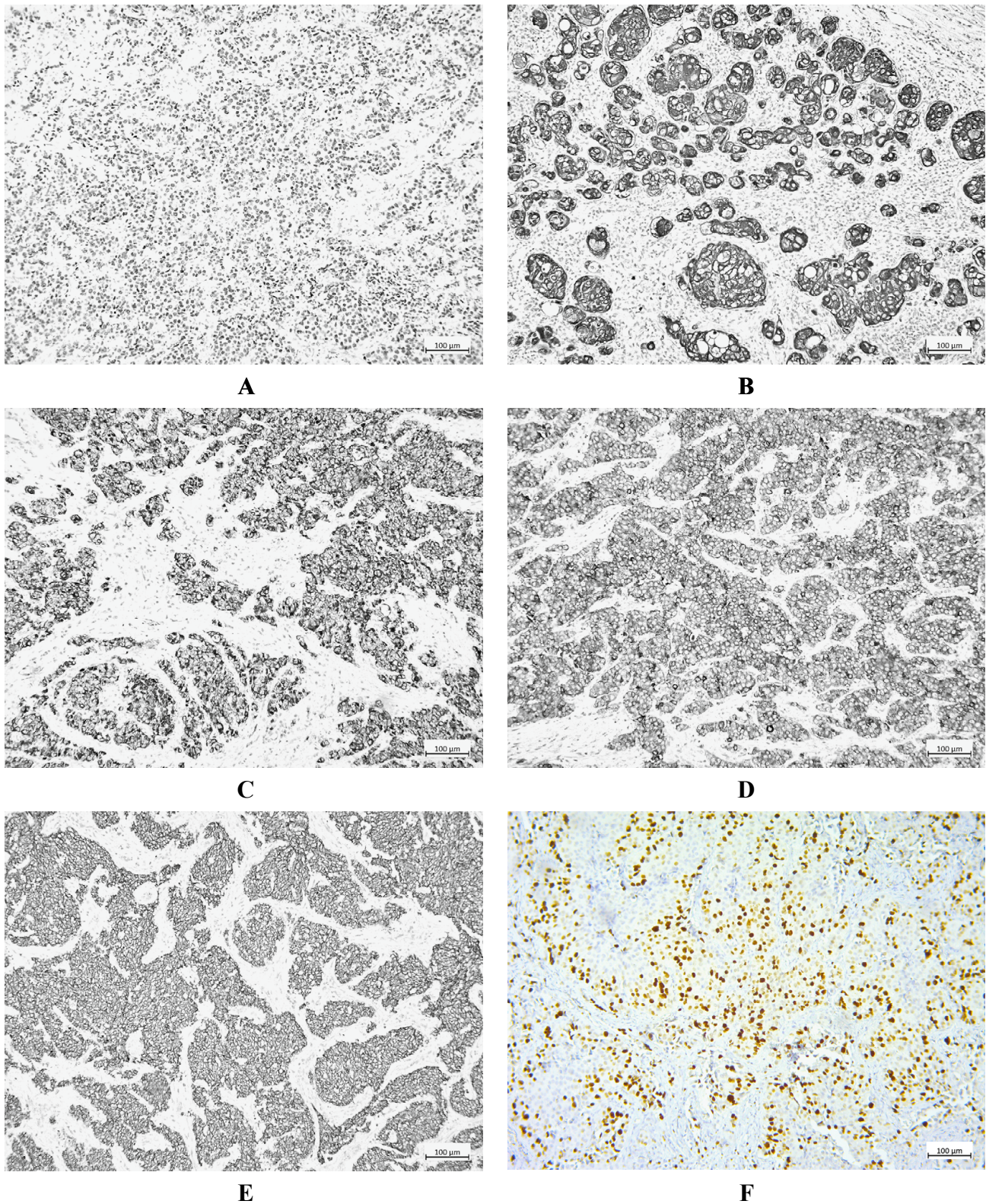


Fig. 3. Micropreparation. Strong staining for characteristic IHC markers in lung NENs. A — AC (grade 2), TTF-1 positive staining (2+). ×200. B — AC (grade 2), CK7 positive staining (2+). ×200. C — AC (grade 2), Chr A positive staining (2+). ×200. D — AC (grade 2), Syn positive staining (2+) ×200. E — SCLC (grade 3), CD56 positive staining (2+) ×200. F — LCNEC (grade 3), Ki-67=55%. ×200.

of timely and correct diagnosis remain relevant. And one of the most important issues is the differentiation between low- and high-grade lung NENs. For a while there were no clear criteria for pulmonary NENs grading. ICH is obligatory for modern diagnostic algorithm for lung NENs. It is mainly used to characterize the aggressiveness of NENs by assessing proliferative index Ki-67, as well as NE differentiation (Chr A, Syn, CD56 markers). However, literature data on the expression of different markers are often contradictory, and many aspects require further study.

Broncho-pulmonary NENs are currently classified in four main categories, including highly differentiated TC, moderately differentiated AC, and low differentiated LCNEC and SCLC.

It is considered that AC account about 1% of all broncho-pulmonary NENs and SCLC accounts up to 75%. But in the current study the ratio of lung NENs subtypes differs from generally accepted because of AC and SCLC. While the proportion of TC and LCNEC corresponded to literature data (8% and 17.7% respectively), AC was diagnosed in 35.4% cases, SCLC — in 38.9%. Maybe there two reasons for this. Most studies are conducted on small number of samples because of pathology rarity, and sometimes their results are rather contradictory. Moreover, for a long time there were no clear guidance on lung NENs subtyping, and researchers used different approaches (based on mitotic rate, Ki-67 ratio with different cutoffs, and even applied modified classification for gastrointestinal NENs).

Necrosis considered an obligatory feature for lung NENs classification, and the number and extent of necrotic foci rise with a decrease in tumors differentiation level. This statement was also confirmed by the results of our study. But in 19 (29.7%) specimens of lung NECs (11 SCLC / 8 LCNEC) only small foci of necrosis were found. Probably because 14 (73.7%) of 19 samples were biopsies, and 8 (57.6%) of them appeared to be small or crushed. 11 (17.2%) samples of poorly differentiated lung NENs (8 SCLC / 3 LCNEC) didn't show any necrosis; 7 (63.7%) of these 11 specimens were biopsies, rather small or extensively crushed.

Morphology represents the first cornerstone for the differential diagnosis between NETs and

NECs. Combination of morphological features and Ki-67 proliferative index improves the ability of this distinction, which has important clinical implications.

Ki-67 is required to estimate tumor grade, especially in small biopsies with crush artifacts impairing the morphological examination. For a while Ki-67 was not a diagnostic criteria for lung NENs grading, especially for distinguishing TC from AC, because of certain overlapping between different histological subtypes. But Ki-67 is much more reliable and convenient to use than mitotic rate, and less time-consuming. Ki-67 considered the ICH “golden standard” in oncopathomorphology. The Ki-67 cut-offs for lung NENs grading have changed several times which caused differences in their classification and distribution in different studies. According to the latest guidelines, Ki-67 up to 5% considered grade 1 (TC), up to 30% (AC), and $\geq 30\%$ — grade 3 (LCNEC and SCLC). But SCLC usually show the highest Ki-67 rates. Likewise, in our study mean Ki-67 index in LCNECs was 54.4% (CI 95% (45.5–63.2)), in SCLCs — 63.4% (CI 95% (58.5–68.2)). Ki-67 ratio exceeded 50% in 46 (71.9%) NECs (35 SCLC / 11 LCNEC), 75% — in 13 (20.3%) NECs (9 SCLC / 4 LCNEC), in 5 (7.8%) samples Ki-67 reached 90–100% (3 SCLC / 2 LCNEC). Primary high-grade lung NENs, diagnosed on small biopsies, showing classic LCNEC or SCLC morphology, and extremely high Ki-67 index, often are characterized by very aggressive clinical behavior.

During the process of malignant transformation, tumor cells retain some of the functional characteristics which are specific to their sight of origin and can be easily identified by certain ICH markers expression.

Positive staining for TTF-1 and CK7 helps to distinguish pulmonary from gastrointestinal NENs. Different subtypes of lung NENs are variably stained by TTF-1 and CK7. TTF-1 expression was more specific for TC and AC, however, CK7 staining was more stable in low-differentiated malignancies. In the current study 28 (57.1%) NETs were positive for TTF-1 and 32 (65.3%) — for CK7. While only 28 (43.8%) NECs showed positive TTF-1 staining, CK7 expression was observed in 38 (59.4%) samples.

The combination of NE morphological features and positive staining for at least one NE marker was suggestive of the diagnosis of the lung NEN.

It was noticed that 10–20% of lung NECs are positive with one NE marker. In the current study there were 7 (10.9%) of such specimens. But in most cases LCNEC and SCLC were positive for two NE markers.

The staining of each NE marker varies among the histological subtypes of lung NENs and decreases in low-differentiated NECs. In the current study Chr A expression decreased and disappeared rather quickly with tumor progressing, while many high-grade NECs still show positive Syn and CD56 staining. CD56 was a reliable mark to confirm a diagnosis in dedifferentiated lung NECs that lost their ability to express other NE markers. CD56 expression was seen in 18 specimens, and 7 (38.9%) of them (6 SCLC / 1 LCNEC) were negative for Chr A and Syn. It is most likely that CD56 may be considered an indicator of SCLC rather than general NE marker.

According to the results of our study, the correlation of ICH markers expression with necrosis, Ki-67 ratio and tumor grade was significant only for Chr A (Spearman's rank correlation). All other tested options, for other biomarkers were not statistically significant.

The strong positive correlation ($p < 0.01$) was seen for Chr A and TTF-1, also between Chr A and CK7. Most highly and moderately differentiated lung NENs showed strong or medium TTF-1 expression. As the tumors' differentiation decreased, these markers expression diminished or disappeared. However, CK7 values remained relatively stable even in poorly differentiated NECs.

Strong negative correlation ($p < 0.05$) was revealed between Chr A expression and key points (maybe better use the word features?), used for lung NENs classification. Chr A expression strongly correlated with necrosis presence and extent, with Ki-67 ratio, and with tumor grade. Numerous and extent necroses, high Ki-67 index, and high grade are for poorly differentiated lung NENs, so, many of these malignancies appear to be Chr A-negative. If pulmonary NEN doesn't

express Chr A, it may testify in favor of a tumor progressing.

Conclusion

Lung NENs is a heterogeneous group of high- and low-grade malignancies arising from NE cells and classified into four histological subtypes, namely TC, AC, LCNEC and SCLC. Despite the rarity, bronchopulmonary NENs are rising in incidence over few past decades (which may be related to improvements in imaging and pathological diagnostic techniques) and make up about 20% of all lung malignancies with a large prevalence of NECs. Pulmonary NENs diagnosed based on organoid morphology, mitotic count, necrosis features and presence of NE markers. ICH staining is the commonly used specialized technique that notably improves diagnostic accuracy at lung NENs. But sometimes there is a lack of concordance of ICH markers and morphological criteria for bronchopulmonary NENs diagnosis and grading. Thus, there is a need to study correlations between biomarkers expression and key morphological features (tumor cells proliferation, necrosis, and grade) in lung NENs, and to identify statistically robust markers.

In the current study the strong positive correlation between Chr A expression and markers of primary lung origin of the tumor (TTF-1 and CK7) was found. All these three markers are mainly expressed in highly and moderately differentiated pulmonary NENs (especially Chr A and TTF-1).

Also, strong negative correlation was seen between Chr A expression and necrosis, proliferative index (Ki-67), and tumor grade.

Decrease or loss of Chr A expression reliably indicates tumor progression. Chr A expression can be used as an additional tool for lung NENs grading.

Limitation of the current study: retrospective analysis, and relatively small sample range; distribution of lung NENs subtypes differs from the generally accepted.

Further prospective studies on larger samples are needed to overcome the mentioned limitations and to determine the clinical value of Chr A expression.

Financing

The current study was performed as part of research work “Development of histological and molecular-biological criteria for differential diagnosis of tumors and precancerous changes in organs and their prognostic value” (state registration #0119U101131).

Conflict of interests

The authors have no conflict of interest to declare.

Consent to publication

The authors have read and approved the final version of the manuscript. Authors agreed to publish this manuscript.

ORCID ID and AUTHORS CONTRIBUTION

[0000-0001-9171-9237](https://orcid.org/0000-0001-9171-9237) (A,B,C,D) Chytaieva Halyna
[0000-0001-6169-5190](https://orcid.org/0000-0001-6169-5190) (B,E) Shkurupii Bohdana
[0000-0001-6838-9970](https://orcid.org/0000-0001-6838-9970) (A,E,F) Zakhartseva Liubov

A – Research concept and design, B – Collection and/or assembly of data, C – Data analysis and interpretation, D – Writing the article, E – Critical revision of the article, F – Final approval of article

REFERENCES

- Basuroy R., Bouvier C., & Srirajaskanthan R. (2018). Delays and routes to diagnosis of neuroendocrine tumours. *BMC Cancer*, 18(1): 1122. <https://doi.org/10.1186/s12885-018-5057-3>
- Bellizzi A.M. (2020). Immunohistochemistry in the diagnosis and classification of neuroendocrine neoplasms: what can brown do for you? *Human Pathology*, 96: 8–33. <https://doi.org/10.1016/j.humpath.2019.12.02>
- Borzuk A.C. (2020). Pulmonary neuroendocrine tumors. *Surgical Pathology Clinics*, 13(1): 35–55. <https://doi.org/10.1016/j.path.2019.10.002>
- Broder M.S., Cai B., Chang E., & Neary M.P. (2018). Incidence and prevalence of neuroendocrine tumors of the lung: analysis of a US commercial insurance claim database. *BMC Pulmonary Medicine*, 18(1): 135. <https://doi.org/10.1186/s12890-018-0678-5>
- Cadioli A., Rossi G., & Colby T.V. (2014). Lung cancer histologic and immunohistochemical heterogeneity in the era of molecular therapies: analysis of 172 consecutive surgically resected, entirely sampled pulmonary carcinomas. *The American Journal of Surgical Pathology*, 38(4): 502–509. <https://doi.org/10.1097/PAS.0000000000000154>
- Cai Y.C., Banner B., & Odze R.D. (2001). Cytokeratin 7 and 20 and thyroid transcription factor 1 can help distinguish pulmonary from gastrointestinal carcinoid and pancreatic endocrine tumors. *Human Pathology*, 32(10): 1087–1093. <https://doi.org/10.1053/hupa.2001.28245>
- Di Giacinto P., Rota F., Rizza L., Campana D., Isidori A., Lania A., ... Baldelli R. (2018). Chromogranin A: from laboratory to clinical aspects of patients with neuroendocrine tumors. *International Journal of Endocrinology*, 2018:8126087. <https://doi.org/10.1155/2018/8126087>
- Garg R., Bal A., & Singh H. (2019). Proliferation marker (Ki67) in sub-categorization of neuroendocrine tumors of the lung. *Turk. Patoloji Derg*, 35(1): 15–20. <https://doi.org/10.5146/tjpath.2018.01436>
- Gkolfinopoulos S., Tsapakidis K., & Kountourakis P. (2017). Chromogranin A as a valid marker in oncology: Clinical application or false hopes? *World Journal of Methodology*, 7(1): 9–15. <https://doi.org/10.5662/wjm.v7.i1.9>
- Gur'yanov V.G., Lyakh Yu.E., & Parii V.D. (2018). Posibnik z biostatistiki. Analiz rezul'tativ medichnikh doslidzhen' u paketi EZR (R-STATISTICS) / Navchal'nii posibnik. [in Ukr.]. Handbook on biostatistics. Analysis of the results of medical research in the EZR package (R-STATISTICS). Kyiv: Vistka, 206 p.
- Hendifar A.E., Marchevsky A.M., Tuli R. (2017). Neuroendocrine tumors of the lung: current challenges and advances in the diagnosis and management of well-differentiated disease. *Journal of Thoracic Oncology*, 12(3): 425–436. <https://doi.org/10.1016/j.jtho.2016.11.2222>
- Hoffland J., Kaltsas G., de Herder W.W. (2019). Advances in the diagnosis and management of well-differentiated neuroendocrine neoplasms. *Endocrine Reviews*, 41(2): 371–403. <https://doi.org/10.1210/endrev/bnz004>
- Hung Y.P. Neuroendocrine tumors of the lung: updates and diagnostic pitfalls. (2019). *Surgical Pathology Clinics*, 12(4): 1055–1071 <https://doi.org/10.1016/j.path.2019.08.012>
- Inzani F., Petrone G., & Rindi G. (2017). Cyto-histology in NET: what is necessary today and what is future? *Reviews in Endocrine and Metabolic Disorders*, 18(4): 381–391. <https://doi.org/10.1007/s1154-017-9428-x>

Jackson A.C., Rosenthal A., Cattoni M., Bograd A.J., Farivar A.S., Aye R.W., ... Louie B.E. (2020). A staging system for neuroendocrine tumors of the lung needs to incorporate histological grade. *The Annals of Thoracic Surgery*, 109(4): 1009–1018. <https://doi.org/10.1016/j.athoracsur.2019.09.053>

Kriegsmann K., Zgorzelski C., Muley T., Christopoulos P., Thomas M., Winter H., ... Kriegsmann M. (2021). Role of synaptophysin, chromogranin and CD56 in adenocarcinoma and squamous cell carcinoma of the lung lacking morphological features of neuroendocrine differentiation: a retrospective large-scale study on 1170 tissue samples. *BMC Cancer*, 21(1): 486. <https://doi.org/10.1186/s12885-021-08140-9>

Kyriakopoulos G., Mavroei V., & Alexandraki K.I. (2018). Histopathological, immunohistochemical, genetic and molecular markers of neuroendocrine neoplasms. *Annals of Translational Medicine*, 6(12): 252. <https://doi.org/10.21037/atm.2018.06.27>

La Rosa S., Uccella S. (2021). Classification of neuroendocrine neoplasms: lights and shadows. *Reviews in Endocrine and Metabolic Disorders*, 22(3): 527–538. <https://doi.org/10.1007/s11154-020-09612-2>

Marchevsky A.M., Hendifar A., Walts A.E. (2018). The use of Ki-67 labeling index to grade pulmonary well-differentiated neuroendocrine neoplasms: current best evidence. *Modern Pathology*, 31(10): 1523–1531. <https://doi.org/10.1038/s41379-018-0076-9>

Melosky B. (2017). Low grade neuroendocrine tumors of the lung. *Frontiers in Oncology*, 7: 119. <https://doi.org/10.3389/fonc.2017.00119>

Naheed S., Holden C., & Pelosi G. (2019). The utility of Ki-67 as a prognostic biomarker in pulmonary neuroendocrine tumors: protocol for a systematic review and meta-analysis. *BMJ Open*, 9(8): e031531. <https://doi.org/10.1136/bmjopen-2019-031531>

Oronsky B., Ma P.C., Morgensztern D., & Carter C.A. (2017). Nothing but NET: a review of neuroendocrine tumors and carcinomas. *Neoplasia*, 19(12): 991–1002. <https://doi.org/10.1016/j.neo.2017.09.002>

Pelosi G., Scarpa A., & Sonzogni A. (2016). The impact of immunohistochemistry on the classification of lung tumors. *Expert Review of Respiratory Medicine*, 2016; 10 (10): 1105–1121. <https://doi.org/10.1080/17476348.2017.1235975>

Pelosi G., Sonzogni A., Harari S., Albini A., Bresaola E., Marchio C., ... Papotti M. (2017). Classification of pulmonary neuroendocrine tumors: new insights. *Translational Lung Cancer Research*, 6 (5): 513–529. <https://doi.org/10.21037/tlcr.2017.09.04>

Pericleous M., Karpathakis A., Toumpanakis C., Lumgair H., Reiner J., Marelli L., ... Caplin M.E. (2018). Well-differentiated bronchial neuroendocrine tumors: Clinical management and outcomes in 105 patients. *The Clinical Respiratory Journal*, 12(3): 904–914. <https://doi.org/10.1111/crj.12603>

Rindi G., Inzani F. (2020). Neuroendocrine neoplasms update: toward universal nomenclature. *Endocrine-related Cancer*, 27(6): R211–R218. <https://doi.org/10.1530/ERC-20-0036>

Sadrzadeh H., & Kline G. (Eds.) (2017). *Endocrine biomarkers: clinical aspects and laboratory determinations*. Elsevier. <https://doi.org/10.1016/C2014-0-03865-8>

Singh S., Granberg D., Wolin E., Warner R., Sissons M., Kolarova T., ... Leyden J. (2017). Patient-reported burden of a neuroendocrine tumor (NET) diagnosis: results from the First Global Survey of Patients with METs. *Journal of Global Oncology*. *Oncol.*, 3 (1): 43–53. <https://doi.org/10.1200/JGO.2015.002980>

Sugimoto A., Umemura S., Miyoshi T., Nakai T., Kuroe T., Nosaki K., ... Ishii G. (2021). High proportion of tumor necrosis predicts poor survival in surgically resected high-grade neuroendocrine carcinoma of the lung. *Lung Cancer*, 157: 1–8. <https://doi.org/10.1016/j.lungcan.2021.05.018>

Thoracic Tumors. WHO Classification of Tumors (2021). 5th ed. P.127–192. ISBN-13: 978-9283245063.

Umakanthan S., Chalapathi Rao A.V., Mohammed W. (2021). Role of immunohistochemistry markers in neoplastic lung lesions. *Journal of Cancer Research and Therapeutics*, 17(6): 1382–1388. https://doi.org/10.4103/jcrt.JCRT_187_19

Wang H., Sun L., Bao H., Wang A., Zhang P., Wu X., ... Lu M. (2019). Genomic dissection of gastrointestinal and lung neuroendocrine neoplasm. *Clin. J. Cancer Res.*, 31(6): 918–929. <https://doi.org/10.21147/j.jssn.1000-6904.2019.06.08>

Yatabe Y., Dacic S., Boreczuk A.C., Warth A., Russell P.A., Lantuejoul S., ... Moreira A.L. (2019). Best practices recommendations for diagnostic immunohistochemistry in lung cancer. *Journal of Thoracic Oncology*, 14(3): 377–407. <https://doi.org/10.1016/j.tho.2018.12.005>

Кореляція між експресією імуногістохімічних маркерів та морфологічними критеріями у нейроендокринних новоутвореннях легень

Читаєва Галина¹, Шкурупій Богдана¹, Захарцева Любов^{1,2}

¹ Кафедра патологічної анатомії, Національний медичний університет імені О.О. Богомольця, м. Київ, Україна

² Відділення патологічної анатомії Київського міського онкологічного центру, м. Київ, Україна

Address for correspondence:

Chytaieva Halyna

E-mail: h.chytaieva@gmail.com

Анотація: нейроендокринні новоутворення легень включають досить гетерогенні та рідкісні пухлини, для яких зазвичай характерні неспецифічні, «стерті» клінічні прояви, що ускладнює встановлення правильного діагнозу або спричиняє суттєву його затримку. Коректна діагностика та класифікація нейроендокринних новоутворень легень потребують вдосконалення. Гістологічне дослідження має бути доповнене імуногістохімічними тестами з метою верифікації нейроендокринного компонента, оцінки проліферативного індексу клітин пухлини, та підтвердження її бронхо-легеневого походження. Імуногістохімічне дослідження є особливо важливим у випадку малих або крап-біопсій, які складають понад 50% усіх зразків при нейроендокринних новоутвореннях легень. Сучасна класифікація нейроендокринних новоутворень легень та визначення ступеня їх диференціювання здійснюються за морфологічними критеріями. Експресія імуногістохімічних маркерів є досить варіабельною у різних гістологічних підтипах бронхо-легеневих нейроендокринних новоутворень, часто дані є описовими, їх кореляція з морфологічними ознаками вивчена недостатньо. Метою даного дослідження було визначення статистично значущої кореляції між експресією різних імуногістохімічних маркерів та некрозом, проліферативним індексом (рівень Ki-67) і ступенем диференціювання бронхо-легеневих нейроендокринних новоутворень. В дослідженні використані гістологічні блоки нейроендокринних новоутворень легень 113 пацієнтів — матеріал 36 резекцій і 77 біопсій (54,5% біопсій виявилися малими або роздробленими). Вибірка складалася з 91 пацієнта чоловічої статі та 22 жіночої; вік хворих від 19 до 77 років, у середньому 59,2 року ДІ 95% (56,9–61,4). Гістологічне дослідження (включаючи визначення нейроендокринної морфології, некрозу, ступеня диференціювання пухлини) проведено в усіх випадках. Також проведено імуногістохімічне дослідження до призначення хворим хіміотерапії (з використанням маркерів Chr A, Syn, CD56, TTF-1, CK7 та Ki-67). Всі морфологічні та імуногістохімічні дані оцінювалися двома незалежними патологами без доступу до клінічних даних пацієнта. Всі спостереження класифіковані за WHO Thoracic Tumors Classification (2021 р.). Вибірка була цензурованою. У дослідженні використані методи непараметричної статистики (рангова кореляція Спірмена). Виявлений сильний кореляційний зв'язок ($p < 0.05$) між експресією Chr A та імуногістохімічних маркерів первинних пухлин легень (TTF-1 і CK7), які переважно відзначають у високо та помірно диференційованих нейроендокринних новоутвореннях. Також виявлена позитивна кореляція між експресією маркерів TTF-1 і CK7 ($p < 0.01$). Визначений сильний негативний кореляційний зв'язок ($p < 0.05$) між реакцією на Chr A та наявністю і вираженістю вогнищ некрозу; між експресією Chr A і проліферацією пухлинних клітин (рівень Ki-67) ($p < 0.01$); а також між Chr A та ступенем диференціювання пухлини ($p < 0.01$). Кореляційний зв'язок між

експресією імуногістохімічних маркерів, некрозом, рівнем Ki-67 та ступенем диференціювання пухлини виявився статистично достовірним лише для Chr A. Решта перевірених комбінацій показників, для інших маркерів не були статистично значущими. Визначено, що зниження або втрата експресії Chr A є надійним свідченням пухлинної прогресії. Експресія Chr A може бути використана як додатковий інструмент для розподілу нейроендокринних новоутворень легень за ступенем злоякісності.

Ключові слова: нейроендокринні пухлини, гістологія, імуногістохімія, новоутворення легень, хромогранін А.



© 2022 by the authors; licensee USMYJ, Kyiv, Ukraine.

This article is an **open access** article distributed under the terms and conditions of the Creative Commons Attribution License (<http://creativecommons.org/licenses/by/4.0/>)