

Morphometric Study of Rat Sciatic Nerve Recovery after Three Nerve Repair Techniques: Epineural Suture, Polyethylene Glycol Hydrogel and Fibrin Sealant

Estudio Morfométrico de la Recuperación del Nervio Ciático de Rata después de Tres Técnicas de Reparación Nerviosa: Sutura Epineural, Hidrogel de Polietilenglicol y Sellante de Fibrina

Goncharuk Oleksii O.¹; Savosko Serhii I.²; Petriv Taras I.¹; Medvediev Volodymyr V.¹ & Tsymbaliuk Vitaly I.¹

GOCHARUK, O. O.; SAVOSKO, S. I.; PETRIV, T. I.; MEDVEDIEV, V. V. & TSYMBALIUK, V. I. Morphometric study of rat sciatic nerve recovery after three nerve repair techniques: Epineural suture, polyethylene glycol hydrogel and fibrin sealant. *Int. J. Morphol.*, 39(3):677-682, 2021.

SUMMARY: The effectiveness of microsurgical technique has a direct impact on the recovery of the injured peripheral nerve. The aim of our study was to investigate the result of sciatic nerve regeneration in rats after complete neurotomy and after nerve repair techniques including: 1) epineural suture; 2) polyethylene glycol hydrogel (PEG) (DuraSeal); 3) fibrin sealant (Tisseel). The cross-section of distal sciatic nerve was studied at 14th, 30th and 60th days after nerve repair. Morphometry of myelinated nerve fibers in the distal stump of the sciatic nerve was performed. A significant increase in the number of myelinated nerve fibers was found, especially between 14 and 30 days. The density of myelinated nerve fibers in the distal stump at day 60 was significantly higher after using nerve repair technique including PEG and fibrin versus epineural suture (29.2 % and 32.1 % versus 21.5 %, $P < 0.05$), and a higher level of remyelination of nerve fibers observed in the group with PEG. On day 60, complete elimination of PEG and fibrin sealant was not observed, encapsulation was found around the clusters of hydrogel. Thereby, three peripheral nerve repair techniques were equally effective, only with the use of PEG remyelination of nerve fibers was increasing.

KEY WORDS: Sciatic nerve; Regeneration; Epineural suture; Polyethylene glycol; Fibrin glue.

INTRODUCTION

Microsurgical repair of a damaged nerve is a problem of current interest, as nerve regeneration is slow, at a low rate, often not achieving sufficient muscle reinnervation and functional recovery. The critical area in the damaged nerve is the suture area, because if the connection of the nerve stumps is failed, it does not allow the regeneration of nerve fibers in the distal stump of the nerve to occur (Khalifeh *et al.*, 2019). Another critical factor is the method and strength of the connection of nerve stumps, number of stitches in case of autografting (Gaiovykh *et al.*, 2019).

The gold standard for peripheral nerve neuroraphy is the epineural suture. This is a relatively simple and non-alternative way of connecting nerve stumps if there is no major nerve defect (Kornfeld *et al.*, 2019), although other nerve coaptation techniques have been considered (Molotkovets *et al.*, 2020). Problems associated with the

inability of nerve to regenerate are the failure of the epineural suture and its rupture, which leads to repeated microsurgical operations. To avoid this disadvantage, the possibility of using additional adhesive sealants around the suture, such as hydrogels based on polyethylene glycol (PEG) and fibrin (fibrin glue, FG) (Sexton *et al.*, 2012) is considered.

PEG is a water-soluble polymer of ethylene oxide, a biocompatible semi-adhesive gel-like substance that can be used in tissue repair as a substrate for cell adhesion. PEG coatings were first developed to minimize the surface adhesion of plasma proteins to materials (Kim *et al.*, 2005), later PEG forms were improved to form a microenvironment for cells, surgical barriers, etc. (Puttaswamy *et al.*, 2018). A synthetic analogue of PEG hydrogel (DuraSeal) is increasingly used in neurosurgery (Lee *et al.*, 2013).

¹Department of Neurosurgery, Bogomolets National Medical University, Ukraine.

²Department of Histology & Embryology, Bogomolets National Medical University, Ukraine.

Autologous fibrin glue was originally the only available and easy to create tissue glue, but some technical circumstances of its preparation (centrifugation of blood components, addition of thrombin) prompted the development of a simpler form of use that would completely eliminate these disadvantages. Commercial fibrin gel has become the most commonly used gel in surgery, such as Tisseel (Isaacs *et al.*, 2008).

Unlike suture materials, hydrogels are less traumatic, but the strength of nerve connections, biodegradation, and elimination of gels remain unclear (Isaacs *et al.*). PEG and FG can equally connect the nerve stumps; they do not interfere with nerve regeneration and should not cause connective tissue development, as fixation of the nerve with paraneural tissues impairs the efficiency of recovery (Tse & Ko, 2012). In this paper, we consider the possibility of additional coaptation of damaged nerve stumps with polyethylene glycol (PEG) and fibrin glue (FG), counting on additional adhesion of the nerve sheath (epineurium) of the two stumps of the nerve.

The aim of this study was to evaluate the regeneration of sciatic nerve after microsurgical techniques including epineurial suture, PEG and FG.

MATERIAL AND METHOD

Experimental animals. The experiments were performed on white outbred male rats (250 ± 25 g, 5-6 months). Rats were divided into groups of 5 animals in the group: group 1 – control (intact rats), group 2 – sham-operated animals, where only approach to the sciatic nerve was done without nerve damage, group 3 – animals, where sciatic nerve was transected and then connected with an epineural suture “end-to-end” (4-6 epineural sutures with polyamide thread 10/0), group 4 – animals, where sciatic nerve was transected and then connected with polyethylene glycol hydrogel (PEG) (DuraSeal®, Covidien LLC, USA) and 2 “fixating” epineural sutures, group 5 – animals, where sciatic nerve was transected and then connected with fibrin glue (FG) (Tisseel) and 2 “fixating” epineural sutures.

DuraSeal® dural sealant system is composed of two solutions: 1) a polyethylene glycol (PEG) ester solution and 2) a trilycine amine solution (referred to as the blue and the clear precursors, respectively). Tisseel sealant system is composed of two solutions: 1) Human fibrinogen, Synthetic Aprotinin and 2) a Human thrombin, Calcium chloride dihydrate.

The surgery was performed under anesthesia (xylazine 15 mg / kg and ketamine 70 mg / kg, intraperitoneally). Firstly approach to the sciatic nerve was made, then the nerve was completely cut, after that specific operation depending on the group it was performed, and in the end suturing the wound in layers with monofilament polyamide thread 4/0 was done.

Bioethics. All experimental procedures were conducted according of current standards of bioethics (EU Directive 2010/63/EU “on the protection of animals used for scientific purposes” (1986), European Convention for the Protection of Vertebrate Animals Used for Experimental and Scientific Purposes (1986), Law of Ukraine of February 21, 2006 No. 3447-IV “About protection of animals against ill treatment” (2006)). The protocol of the study was approved by the bioethical commission of Bogomolets National Medical University (protocol 113).

Light Microscopy. Longitudinal cryo-sections were made from the suture area, the material was pre-fixed in 10 % phosphate buffered formalin. Slices stained by PicroSirius Red (0.5 g Direct Red 80 (Magnacol Ltd, UK) in 500 ml of saturated picric acid) dehydrated and placed in the medium (Merck, Germany).

Distal sciatic nerve was fixed in 2.5 % solution of glutaraldehyde in phosphate buffer with 1 % osmium tetrachloride, dehydrated in increasing concentrations of ethanol and acetone. The distal nerve samples we embedded in the Epone-Araldite mixture. To get the ultrathin slices, we applied an ultratome (Reihart). The semi-thin sections were stained with toluidine blue (Hayat, 2000), and then were studied under a light microscope (Olympus BX 51) for histological and morphometrical examination.

For morphometric examination, Carl Zeiss software (AxioVision SE64 Rel.4.9.1) and a camera attachment were used. Distal sciatic nerve samples for each rat were examined at high (1000x) magnification. The mean numerical density of the myelinated axons was estimated in photo (216x138 μm , average 0.03 mm^2), amount of sampling photo are 10-15 (2/3-3/4 of cross-section of nerve). The mean diameter (μm) of the myelinated axons was estimated by average of large and small diameters per individual fiber.

The statistical analysis was done by StatPlus version 7.0 (Microsoft). The data are expressed as mean \pm standard error of mean (SEM). The results were analyzed and compared using analysis of variance (one-way ANOVA) followed by Bonferroni's post hoc test. Differences were considered significant at $P < 0.05$.

RESULTS AND DISCUSSION

Nerve suture area. The sutures were surrounded by connective tissue and this has increased the focal thickness of the epineurium (Table I). Between days 14 and 60, nerve thickness, which was calculated on longitudinal histological sections, increased statistically (neuroma formation and epineurial connective tissue enlargement). PEG encapsulation (focal clusters of PEG from 90 to 1600 μm) was detected, and focal clusters of fibrin were smaller and multifocal (focal clusters of FG from 100 to 200 μm). In the PEG and FG group epineurial thickness increased by 60th day, but remained within the statistical error compared to the epineural suture group (ES-group) (Table I). There were no inflammatory leukocyte infiltration in areas with PEG and FG.

Fascicles changes. At the site of the suture, the integrity of the fascicles was changed, and regenerative neuroma was formed. In all studied samples, the distal stump of the nerve retained the fascicular structure. PEG and FG did not affect the change of nerve fascicles. The thickness of the distal stump of the nerve also did not change.

Regeneration of myelinated nerve fibers in distal stump. In the group of sham operated animals, no difference in density and diameter of myelinated nerve fibers was

detected both with control and in three periods of the experiment. On days 14, 30, and 60 after repair, thin regenerating myelinated nerve fibers were found in the distal stump of the sciatic nerve (Fig. 1). In the ES-group, the number of nerve fibers increased between 14 and 60 days (Table I). The diameter of the myelinated nerve fibers did not differ. At 60th day, the appearance of thick fibers was detected, but this did not affect the overall assessment (average diameter of most fibers was 4-6 μm , whereas in the control 8-10 μm).

In the group with PEG (PEG-group), the density of nerve fibers increased significantly compared with the ES-group at 30 and 60 days. The number of nerve fibers in distal stump significantly increased compared to day 14. The diameter of myelinated nerve fibers also increased, especially by day 30 (the appearance of fibers up to 16 μm in diameter, although 4-6 μm dominated), and the number of thin fibers further increased.

In the FG-group, the density of myelinated nerve fibers in distal stump significantly increased by 30 and 60 days, and the fiber diameter was significantly larger than in the epineural suture group by day 14 and was smaller by day 60 than in the PEG-group (most with a diameter of 4-6 μm at all periods; the fiber density did not differ relative to the PEG-group).

Table I. Morphometric data for rats sciatic nerve on 14, 30 and 60 day after neurotaphy.

Parameter	Day	Control	Shame-operated	Epineural suture	PEG	FG
Thickness of the nerve in sutured site (mm)	14		-	1534.1 \pm 222.6	1560.1 \pm 148.9	1598.9 \pm 179.3
	30	-		1943.7 \pm 63.1	1619.3 \pm 102.2	1542.2 \pm 133.3
	60			2260.8 \pm 165.2@	2261.5 \pm 101.9	1997.0 \pm 80.8
Thickness of the distal nerve (mm)	14		1122.8 \pm 53.3	986.9 \pm 68.4	1006.8 \pm 45.4	1001.4 \pm 52.1
	30	1139.7 \pm 96.8	1142.8 \pm 32.8	992.7 \pm 27.0	1017.8 \pm 87.1	1208.1 \pm 172.2
	60		1150.2 \pm 63.0	1024.1 \pm 85.2	1101.0 \pm 75.4	985.4 \pm 57.6
Number of fascicle	14		2.6 \pm 0.2	2.6 \pm 0.2	2.8 \pm 0.2	2.6 \pm 0.2
	30	2.8 \pm 0.3	3.0 \pm 0.3	2.8 \pm 0.2	2.4 \pm 0.2	3.0 \pm 0.3
	60		2.8 \pm 0.2	2.8 \pm 0.4	3.0 \pm 0.4	2.8 \pm 0.2
Number (fiber/test-zone)	14		202.8 \pm 12.06	25.29 \pm 1.77*	30.4 \pm 1.45*	31.7 \pm 1.47*
	30	200.0 \pm 13.14	197.4 \pm 10.71	38.5 \pm 2.40*	48.5 \pm 2.78*^	56.8 \pm 4.39*^
	60		199.5 \pm 10.76	43.15 \pm 2.04*	58.5 \pm 2.66*^@**	64.2 \pm 2.20*^**
Density (fiber/mm ²)	14		5643.4 \pm 209.4	720.6 \pm 48.5*	868.1 \pm 39.7*	905.4 \pm 40.2*
	30	5703.6 \pm 256.0	5734.4 \pm 211.4	1076.8 \pm 61.7*	1384.7 \pm 77.6*^@	1618.8 \pm 121.7*^@
	60		5445.7 \pm 177.3	1229.8 \pm 55.8* @	1675.9 \pm 72.8*^@	1829.8 \pm 60.1*^@
Diameter of myelinated nerve fiber (μm)	14		15.16 \pm 0.37	4.75 \pm 0.06	5.20 \pm 0.15^	5.54 \pm 0.18^
	30	15.28 \pm 0.36	15.81 \pm 0.35	4.82 \pm 0.05*	8.58 \pm 0.18*^	5.23 \pm 0.06*
	60		16.24 \pm 0.34	6.20 \pm 0.12*	6.50 \pm 0.12*	5.74 \pm 0.27*,***
Myelin thickness (μm)	14		3.71 \pm 0.13	0.74 \pm 0.02*	0.81 \pm 0.02*	0.82 \pm 0.02*
	30	3.74 \pm 0.12	3.72 \pm 0.18	0.98 \pm 0.10* @***	1.65 \pm 0.10* @	1.21 \pm 0.02* @***
	60		3.78 \pm 0.15	1.27 \pm 0.04* @**	1.34 \pm 0.04* @**	1.32 \pm 0.05* @

Data expressed as mean \pm SEM * P < 0.05 in comparison with the control and shame-operated group; ^ P < 0.05 in comparison with the ES; @ in comparison with 14day; ** in comparison with 1 m; *** P < 0.05 in comparison with the PEG.

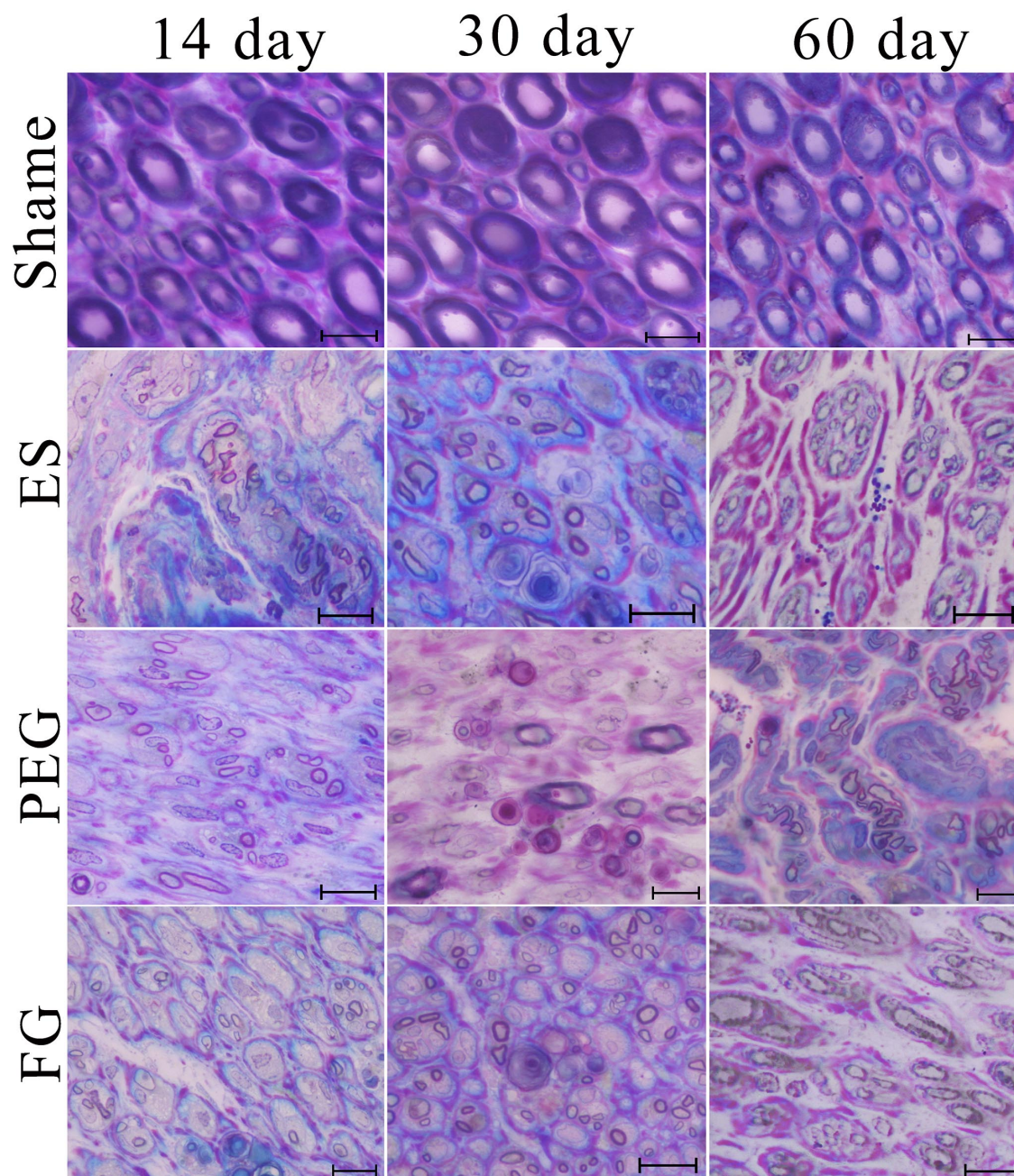


Fig. 1. Cross section of in distal sciatic nerve stained by M.A. Hayat method: SHAME – shame-operated; ES – epineurial suture; PEG – polyethylene glycol; FG – fibrin glue. Scale bar: 20µm.

Morphometric analysis showed a significantly higher number of myelinated nerve fibers in the distal stump of sciatic nerve in PEG- and FG-group versus ES-group at day 60 (29.2 % and 32.1 % versus 21.5 %, $P < 0.05$), and PEG contributed to the regeneration of larger fibers (with a thicker myelin sheath).

An increase in the thickness of the myelin sheath in nerve fibers was also revealed, when comparing 14 and

60 days in each group, the difference was 1.78, 1.65 and 1.65 times ($P < 0.05$). Regeneration of larger-diameter myelinated fibers of a larger diameter (higher than 5.2 µm) on day 30 in the PEG-group suggests an accelerated growth and remyelination of myelin fibers in this group.

In general, in the distal stump of the sciatic nerve there was a partial preservation of endoneural elements (endoneural tubes) in three nerve repair techniques, no

significant difference was found in the regeneration of nerve fibers, although PEG contributed to the regeneration of larger diameter myelinated fibers, indicating the acceleration of regeneration, similarly, the regeneration density increases after the application of FG.

There is interest in the development of surgical adhesives for gluing nerves, which would be non-toxic, biocompatible, had adhesion to epineurium and at the same time did not cause fibrotic changes and nerve fixation with paraneural tissues. The main purpose of their use is to reduce the trauma of the connecting nerve stumps. Substances in the form of glues and gels partially realize this task. This study compared nerve regeneration after neuroraphy with the use of 4-6 epineural sutures, and nerve repair techniques including 2 sutures with PEG and FG. The last two were still fixated with 2 sutures, because in our opinion the adhesive characteristics of PEG and FG are still insufficient for a strong connection of the nerve stumps. Similarly, other authors believe, in particular, the effect of combining PEG with spastin (Lin *et al.*, 2019) or PEG with suture (Ghergherehchi *et al.*, 2019) was better than PEG alone.

According to the results of the work, the coaptation of the transected sciatic nerve in 3 ways was equally sufficient for the formation of regenerative neuroma and regeneration of nerve fibers in the distal stump of the nerve. At day 60, focal PEG and FG remained, FG underwent greater elimination than PEG, and caused less connective tissue growth at the suture site. Importantly, the fascicular structure of the nerve and endoneural tubes in the distal stump of the nerve remained preserved, and no difference in the morphology of the distal nerve between the comparison groups was found. Preservation of endoneural tubes is important for nerve regeneration because regenerating nerve fibers have adhesion to collagen and endoneural fibroblasts, as well as to other extracellular matrix proteins. The absence of damaging effect on the nerve from PEG and FG, sufficient nerve fixation, and the acceleration of nerve fibers regeneration at day 60 after microsurgical nerve repair is an advantage over multiple nerve sutures.

Isaacs *et al.* also found no difference in nerve diameter, epineural changes, and perineural scarring between DuraSeal and fibrin, and in subsequent studies found no difference in the strength of the restored nerve after DuraSeal, Tisseel, and autologous fibrin. Sexton *et al.* in a model of a nerve graft found an increase in the number of nerve fibers by 15 % in the graft and distal nerve after the application of PEG. Lin *et al.* (2010) found no difference in nerve regeneration and

electrophysiological values after suture and PEG (DuraSeal), instead the latter gave better results compared to fibrin glue. But due to sutures and PEG, the thickness of the nerve has increased, which is absent or at a lesser extent develops after the application of fibrin glue. PEG had a higher adhesive capacity compared to FG, so in the latter occurred a diastase (gap). After PEG, myelinated fibers of a larger diameter were regenerating, as described in later articles (Lin *et al.*, 2019) and noted in our study. Moreover, there is evidence that acceleration of peripheral nerve regeneration after PEG administration prevents gastrocnemius muscle atrophy (Lin *et al.*, 2019).

In conclusion, adhesive sealants based on PEG and fibrin can be an alternative to sutures in restoring peripheral nerves, it reduces coaptation time and trauma, creates an environment of glue around the injured nerve.

GONCHARUK, O. O.; SAVOSKO, S. I.; PETRIV, T. I.; MEDVEDIEV, V. V. & TSYMBALIUK, V. I. Estudio morfológico de la recuperación del nervio ciático de rata después de tres técnicas de reparación nerviosa: sutura epineural, hidrogel de polietilenglicol y sellante de fibrina. *Int. J. Morphol.*, 39(3):677-682, 2021.

RESUMEN: La efectividad de la técnica microquirúrgica tiene un impacto directo en la recuperación del nervio periférico lesionado. El objetivo de nuestro estudio fue investigar el resultado de la regeneración del nervio ciático en ratas después de una neurotomía completa y después de técnicas de reparación nerviosa que incluyen: 1) sutura epineural; 2) hidrogel de polietilenglicol (PEG) (DuraSeal); 3) sellante de fibrina (Tisseel). La sección transversal del nervio ciático distal se estudió a los 14, 30 y 60 días después de la reparación del nervio. Se realizó la morfometría de fibras nerviosas mielinizadas en el muñón distal del nervio ciático. Se observó un aumento significativo en el número de fibras nerviosas mielinizadas, especialmente entre los 14 y 30 días. La densidad de las fibras nerviosas mielinizadas en el muñón distal en el día 60 fue significativamente mayor después de usar una técnica de reparación nerviosa que incluye PEG y fibrina en comparación con la sutura epineural (29,2 % y 32,1 % versus 21,5 %, $P < 0,05$), y un mayor nivel de remielinización del nervio. Fibras observadas en el grupo con PEG. El día 60, no se observó la eliminación completa de PEG y sellador de fibrina, se encontró encapsulación alrededor de los grupos de hidrogel. Por lo tanto, tres técnicas de reparación de nervios periféricos fueron igualmente efectivas, solo que aumentaba con el uso de la remielinización de fibras nerviosas con PEG.

PALABRAS CLAVE: Nervio ciático; Regeneración; Sutura epineural; Polietilenglicol; Cola de fibrina.

REFERENCES

- Gaiovych, I.; Savosko, S.; Labunets, I.; Utko, N.; Makarenko, A. & Chaikovsky, Y. Sciatic nerve regeneration after autografting and application of the bone marrow aspirate concentration. *Georgian Med. News*, (295):145-52, 2019.
- Ghergherehchi, C. L.; Mikes, M.; Sengelaub, D. R.; Jackson, D. M.; Smith, T.; Nguyen, J.; Shores, J. T. & Bittner, G. D. Polyethylene glycol (PEG) and other bioactive solutions with neurorrhaphy for rapid and dramatic repair of peripheral nerve lesions by PEG-fusion. *J. Neurosci. Methods*, 314:1-12, 2019.
- Hayat, M. A. *Principles and Techniques of Electron Microscopy: Biological Applications*. Cambridge, Cambridge University Press, 2000. pp.543.
- Isaacs, J. E.; McDaniel, C. O.; Owen, J. R. & Wayne, J. S. Comparative analysis of biomechanical performance of available "nerveglues". *J. Hand Surg. Am.*, 33(6):893-9, 2008.
- Khalifeh, J. M.; Dibble, C. F.; Dy, C. J. & Ray, W. Z. Cost-effectiveness analysis of combined dual motor nerve transfers versus alternative surgical and nonsurgical management strategies to restore shoulder function following upper brachial plexus injury. *Neurosurgery*, 84(2):362-77, 2019.
- Kim, P.; Kim, D. H.; Kim, B.; Choi, S. K.; Lee, S. H.; Khademhosseini, A.; Langer, R. & Suh, K. Y. Fabrication of nanostructures of polyethylene glycol for applications to protein adsorption and cell adhesion. *Nanotechnology*, 16(10):2420-6, 2005.
- Kornfeld, T.; Vogt, P. M. & Radtke, C. Nerve grafting for peripheral nerve injuries with extended defect sizes. *Wien Med. Wochenschr.*, 169(9-10):240-51, 2019.
- Lee, S. H.; Park, C. W.; Lee, S. G. & Kim, W. K. Postoperative cervical cord compression induced by hydrogel dural sealant (DuraSeal®). *Korean J. Spine*, 10(1):44-6, 2013.
- Lin, K. L.; Yang, D. Y.; Chu, I. M.; Cheng, F. C.; Chen, C. J.; Ho, S. P. & Pan, H. C. DuraSeal as a ligature in the anastomosis of rat sciatic nerve gap injury. *J. Surg. Res.*, 161(1):101-10, 2010.
- Lin, Y. F.; Xie, Z.; Zhou, J.; Chen, H. H.; Shao, W. W. & Lin, H. D. Effect of exogenous spastin combined with polyethylene glycol on sciatic nerve injury. *Neural Regen. Res.*, 14(7):1271-9, 2019.
- Molotkovets, V. Y.; Medvediev, V. V.; Korsak, A. V.; Chaikovsky, Y. B.; Marynsky, G. S. & Tsybaliuk, V. I. Restoration of the integrity of a transected peripheral nerve with the use of an electric welding technology. *Neurophysiology*, 52:31-42, 2020.
- Puttaswamy, S. V.; Bandla, A.; Fishlock, S. J.; Lee, S.; Lee, C. & McLaughlin, J. *Hydrogel as a Nerve Guide and Biocompatible Glue for Neural Applications*. Cork, 2018 IEEE 18th International Conference on Nanotechnology (IEEE-NANO), 2018. pp.1-4.
- Sexton, K. W.; Pollins, A. C.; Cardwell, N. L.; Del Corral, G. A.; Bittner, G. D.; Shack, R. B.; Nanney, L. B. & Thayer, W. P. Hydrophilic polymers enhance early functional outcomes after nerve autografting. *J. Surg. Res.*, 177(2):392-400, 2012.
- Tse, R. & Ko, J. H. Nerve glue for upper extremity reconstruction. *Hand Clin.*, 28(4):529-40, 2012.

Corresponding author:

Savosko Serhii I.

Associate professor, PhD,
department of histology and embryology
Bogomolets National Medical University
Kyiv
UKRAINE

E-mail: s.i.savosko@gmail.com

Received: 25-01-2021

Accepted: 21-02-2021