

UDC 618.36:577.218]:[616.98:578.834COVID19

[https://doi.org/10.52058/2786-4952-2026-3\(61\)-1730-1739](https://doi.org/10.52058/2786-4952-2026-3(61)-1730-1739)

Savchuk Tetiana Vasylivna MD, PhD, Associate Professor, Associate Professor, Associate Professor of the Department of Pathological Anatomy, Bogomolets National medical university, Kyiv, <https://orcid.org/0000-0002-7218-0253>

Leshchenko Ivan Viacheslavovych PhD; Department of Physiology, Bogomolets National medical university, Kyiv, <https://orcid.org/0000-0001-8239-256X>

QUANTITATIVE EVALUATION OF CD34 IMMUNOHISTOCHEMICAL EXPRESSION IN THE PLACENTA IN PREGNANT WOMEN WITH COVID-19

Abstract. Background. Coronavirus (SARS-CoV-2) is the causative agent of the novel viral disease COVID-19. SARS-CoV-2 affects organs whose cells demonstrate a high level of expression of angiotensin-converting enzyme 2 (ACE2). The action of SARS-CoV-2 leads to necrotic and apoptotic changes in the syncytiotrophoblast and in the endothelium of chorionic villous vessels despite protective mechanisms against vertical transmission, including decreased activity (co-expression) and concentration of angiotensin-converting enzyme type II (ACE2) in the placenta.

Objective. To quantitatively determine the expression of the immunohistochemical marker CD34 in the placenta in pregnant women with coronavirus disease (COVID-19).

Methods. A total of 456 placentas from pregnancies complicated by COVID-19 were examined. Group I (n = 422) included placentas from live births, and Group II (n = 34) included placentas from cases of antenatal fetal asphyxia. Depending on the duration of the post-COVID interval (the time between the diagnosis of COVID-19 in the mother and delivery), the following subgroups were formed: I.1 (n = 232) and II.1 (n = 12) with a post-COVID interval of 5–22 weeks; I.2 (n = 190) and II.2 (n = 22) with a post-COVID interval of 1–4 weeks. COVID-19 in pregnant women was confirmed by a positive polymerase chain reaction (PCR) test for SARS-CoV-2 RNA. For comparison, placentas obtained from physiological deliveries before the COVID-19 pandemic (n = 106) were studied. Immunohistochemical analysis using monoclonal antibodies against CD34 and statistical methods were applied.

Results and Conclusions. In the acute phase of coronavirus disease in pregnant women, necroptosis of arteriolar endothelium was detected in 92.6% of placentas from live births and in 100% of cases of antenatal fetal death. This was manifested by decreased expression of monoclonal antibodies against CD34 in the endothelium of

arterioles of chorionic villi. The percentage of CD34 expression in the endothelium of arterioles of chorionic villi in subgroups I.1, I.2, II.1, and II.2 was 20 (16; 22), 20 (13; 30), 18 (8; 22), and 10 (6; 14), respectively, compared with 46 (35; 58) in the comparison group ($p < 0.001$). The presence of placentitis, edema, and narrowing of vascular lumina represent manifestations of endothelial dysfunction, which was associated with decreased expression of the immunohistochemical marker CD34.

Keywords: placenta, COVID-19, SARS-CoV-2, chorionic villi, pathological anatomy, immunohistochemical marker CD34, endothelial dysfunction.

Савчук Тетяна Василівна канд. мед. наук, доцент, доцент кафедри патологічної анатомії НМУ імені О.О. Богомольця; Київ, <https://orcid.org/0000-0002-7218-0253>

Лещенко Іван В'ячеславович старший викладач кафедри фізіології НМУ імені О.О. Богомольця, Київ, <https://orcid.org/0000-0001-8239-256X>

КІЛЬКІСНЕ ВИЗНАЧЕННЯ ЕКСПРЕСІЇ ІМУНОГІСТОХІМІЧНОГО МАРКЕРА CD34 В ПЛАЦЕНТІ ПРИ КОРОНАВІРУСНІЙ ХВОРОБІ (COVID 19) У ВАГІТНОЇ

Анотація. Актуальність. Коронавірус (SARS-CoV-2) є збудником нової вірусної хвороби – COVID-19. Коронавірус SARS-CoV-2 вражає органи, клітини яких відрізняються високим рівнем експресії ангіотензинперетворюючого ферменту 2 (angiotensin-converting enzyme 2 – ACE2). Дія вірусу SARS-CoV-2 спричиняє некротичні та апотичні зміни синцитіотрофібласта та ендотелія судин ворсин хоріона, незважаючи на захисні механізми проти вертикальної передачі – зниження активності (коекспресії) та концентрації в плаценті протеїну ангіотензинперетворюючого ферменту II типу (ACE2).

Метою було кількісне визначення експресії імуногістохімічного маркера CD34 в плаценті при коронавірусній хворобі (COVID 19) у вагітної

Методи. Досліджували 456 плацент при COVID-19 у вагітної: I група (n=422) – плаценти при народженні живого плода та II група (n=34) – при антенатальній асфіксії.

В залежності від тривалості постковідного інтервалу (проміжок часу між діагностуванням COVID-19 у матері та пологами) були сформовані підгрупи: I.1 (n=232) та II.1 (n=12) – постковідний інтервал склав 5-22 тижні; I.2 (n=190) та II.2 (n=22) – 1-4 тижні. COVID-19 у вагітної підтверджено позитивним результатом полімеразної ланцюгової реакції (ПЛР) на наявність РНК вірусу SARS-CoV-2. Для порівняння даних досліджували плаценту (n=106) при фізіологічних пологах до епідемії COVID-19.

Використовували імуногістохімічний з використанням моноклональних антитіл проти CD34 та статистичні методи дослідження.

Результати та підсумок. В гострому періоді коронавірусної хвороби у вагітної некроптоз ендотелію артеріол виявлявся у 92,6% випадків в плаценті живонароджених та 100% спостережень при антенатальній загибелі плода, та проявлявся зниженням експресії моноклональних антитіл проти CD34 у ендотелії артеріол ворсин хоріона. Відсоток експресії моноклональних антитіл проти CD34 в ендотелії артеріол ворсин хоріона в підгрупах I.1, I.2, II.1 та II.2 склав 20 (16; 22), 20 (13; 30), 18 (8; 22) та 10 (6; 14) проти 46 (35; 58) у групі порівняння; $p < 0,001$. Наявність плацентиту, набряк, зменшення просвіту судин – прояви ендотеліальної дисфункції, що проявлялося зменшенням експресії імуногістохімічного маркера CD34.

Ключові слова: плацента, COVID-19, SARS-CoV-2, ворсини хоріона, патологічна анатомія, імуногістохімічний маркер CD34, ендотеліальна дисфункція.

Problem Statement. Coronavirus (SARS-CoV-2) is the causative agent of the novel viral disease COVID-19. SARS-CoV-2 affects organs whose cells exhibit a high level of expression of angiotensin-converting enzyme 2 (ACE2), including type I alveolocytes, cardiomyocytes, cholangiocytes, and the epithelium of the nasal cavity, oral cavity, stomach, and intestine, as well as syncytiotrophoblast cells of chorionic villi. Viral entry occurs with the participation of transmembrane protease serine 2 (TMPRSS2), which is required for activation of the spike (S) protein and cleavage of the ACE2 molecule [1,2]. In response to the death of infected cells (pyroptosis) [3], macrophages and neutrophils become activated, resulting in endothelial dysfunction, impaired rheological properties of blood, and platelet activation. These processes lead to microcirculatory disturbances and, consequently, activation of fibroblasts with the subsequent development of fibrosis. Clinically and morphologically, these processes manifest as disseminated intravascular coagulation (DIC), generalized microthrombosis, inflammation, arteriosclerosis, interstitial fibrosis, and multiple organ failure [4,5]. In pregnant women with COVID-19, these changes contribute to the development of placental dysfunction [6–9]. The action of SARS-CoV-2 induces necrotic and apoptotic changes in the syncytiotrophoblast and in the endothelium of chorionic villous vessels despite protective mechanisms against vertical transmission, including decreased activity (co-expression) and concentration of angiotensin-converting enzyme type 2 (ACE2) in the placenta [10]. These changes have been detected in placentas both in cases with PCR-negative tests in newborns and in cases of stillbirth. The immunohistochemical marker CD34 is expressed by intact endothelial cells [11].

Objective. To quantitatively determine the expression of the immunohistochemical marker CD34 in the placenta in pregnant women with coronavirus disease (COVID-19).

Materials and Methods. To achieve the objective, 456 placentas from pregnancies complicated by COVID-19 were examined. Group I (n = 422) included

placentas from live births, and Group II (n = 34) included placentas from cases of antenatal fetal asphyxia. The material was obtained in accordance with a cooperation agreement with the Department of Pathological Anatomy of the National Children's Specialized Hospital Okhmatdyt of the Ministry of Health of Ukraine during the period from 2020 to 2022. Depending on the duration of the post-COVID interval (the time between the diagnosis of COVID-19 in the mother and delivery), the following subgroups were formed: subgroups I.1 (n = 232) and II.1 (n = 12), with a post-COVID interval of 5–22 weeks; and subgroups I.2 (n = 190) and II.2 (n = 22), with a post-COVID interval of 1–4 weeks. COVID-19 in pregnant women was confirmed by a positive polymerase chain reaction (PCR) test for the presence of SARS-CoV-2 RNA. For comparison, placentas obtained from physiological deliveries before the COVID-19 pandemic (n = 106) were also studied. The immunohistochemical (IHC) method was applied using monoclonal antibodies against CD34 (Thermo Fisher Scientific, USA) in working dilutions to assess the condition of arteriolar endothelium. For quantitative determination of the expression of the immunohistochemical marker, qualitative pixel-by-pixel visualization of the studied structure (endothelium) was performed, based on differences in color intensity resulting from immunohistochemical staining. After fixation of placental tissue fragments in 10% neutral buffered formalin, the samples were processed through a graded series of alcohols, embedded in paraffin, and sectioned at a thickness of 4 μm . Following immunohistochemical staining, the sections were photographed using a digital camera mounted on a microscope. The obtained images were saved in JPEG format and uploaded to the ONLINE JPG TOOLS service (onlinejpgtools.com/find-dominant-jpg-colors). Using this tool, the percentage of the dominant pixel color in each image was determined, which was used as an indicator of the percentage expression of the immunohistochemical marker. (fig.1).

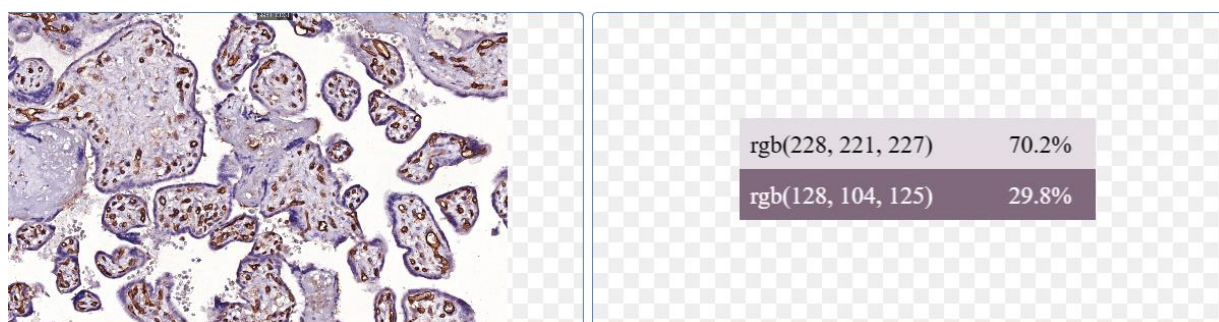


Fig. 1. Screenshot from ONLINE JPG TOOLS

On the left – the uploaded image, on the right – the colors used to determine their percentage in the image. A – microscopic section of the placenta from a mother with COVID-19 at 39 weeks of gestation. CD34 expression is observed in the nuclei of the endothelial cells of chorionic villi. The presence of brown (dark) color indicates positive expression in the endothelium. The percentage of this color in the image corresponds to the percentage of the structure being analyzed.

Presentation of Main Findings.

In the acute period of coronavirus disease in pregnant women, endothelial necroptosis of arterioles was observed in 92.6% of cases in the placentas of live-born infants and in 100% of cases in instances of antenatal fetal demise. This manifested as a decreased expression of monoclonal antibodies against CD34 in the endothelium of chorionic villous arterioles (Fig. 2.A–D; Table 1) compared to the control group (Fig. 2.E).

The percentage of expression of monoclonal antibodies against CD34 in the endothelium of chorionic villus arterioles in subgroups I.1, I.2, II.1 and II.2 was 20 (16; 22), 20 (13; 30), 18 (8; 22) and 10 (6; 14) versus 46 (35; 58) in the comparison group; $p < 0.001$ (Fig. 3).

Table 1

Pathomorphological changes in the placenta in COVID-19 in a pregnant woman

Parameters	COVID-19 (N=456)				Comparison group (n=106)	p	
	Live birth (group I) (N=422)		Antenatal asphyxia (group II) (N=34)				
	I.1 (n=232)	I.2 (n=190)	II.1 (n=12)	II.2 (n=22)			
Necrosis of the endothelium of arterioles; n (%) [95% CI];	6 (2,6) [0,9-5]	176 (92,6) [88,5-95,9] *	2 (16,7) [1,1-45,3]	100 [91,7-100]*	-	$p < 0,001$	
Percentage of expression of monoclonal antibodies against CD34 in the endothelium of chorionic villus arterioles; %	20 (16; 22)*	20 (13; 30)*	18 (8; 22)*	10 (6; 14)*	46 (35; 58)	$p < 0,001$	
Placentitis	Chorioamnionitis	213 (95,5) [93-98,1] *	190 (100) [99-100]*	3(25) [2-55]	22(100) [91,7-100]*	-	$P_{2-3} < 0,001$ $p_{3-4} < 0,001$
	Inter-villositis	17 (7,3) [4,3-11]	51 (26,8) [20,8-33,4]	0 [0,0-14,6]	22 (100) [91,7-100] *	-	$P_{2-3} < 0,001$ $P_{3-4} < 0,001$ $P_{1-4} < 0,001$
	Basal deciduitis	221 (95,3) [92,2%-99,6]	190 (100) [99-100]	8 (72,7) [40,1%-95,5]	22 (100) [91,7-100]	-	

Note: * $p < 0.01$ (Kruskal–Wallis test)

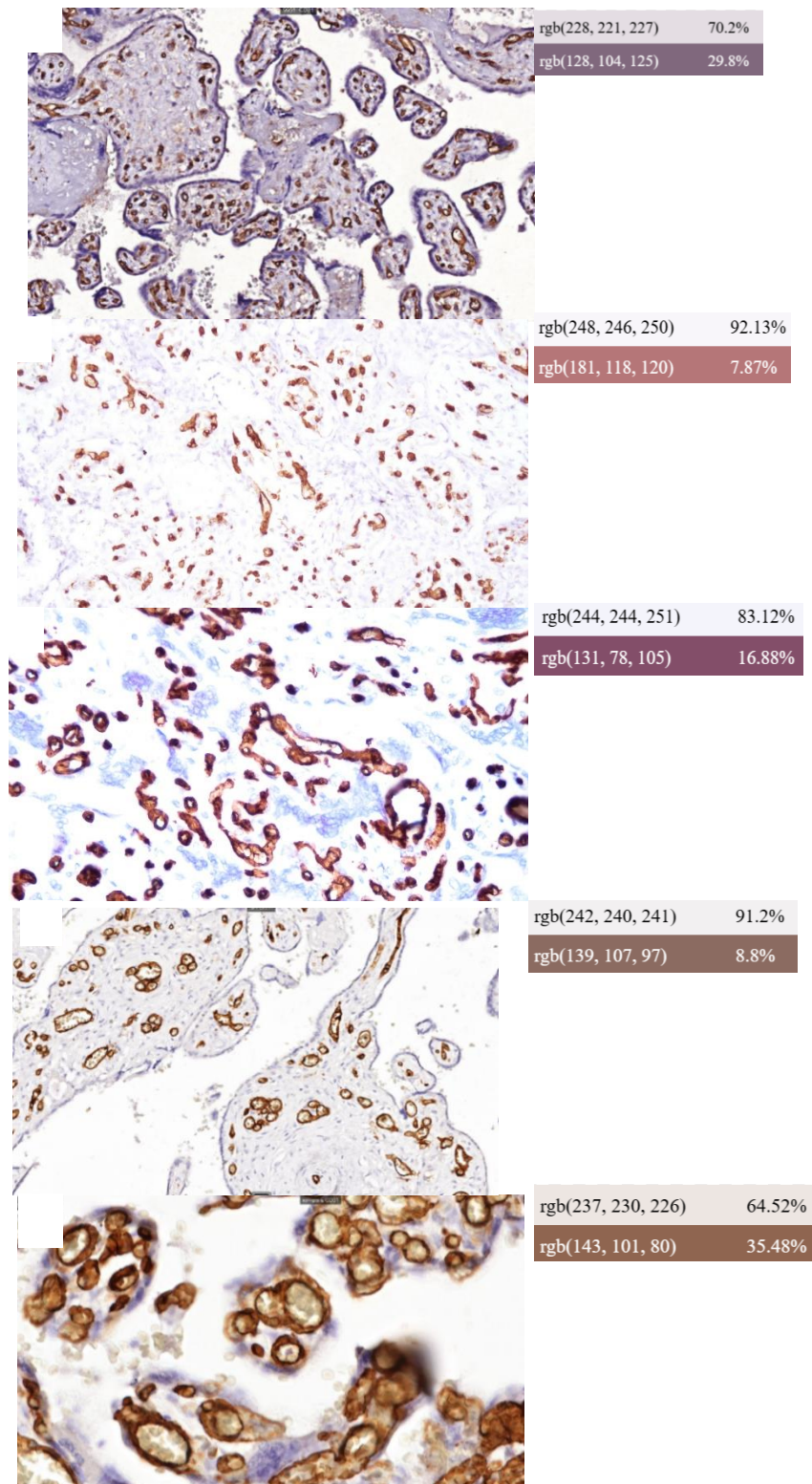


Fig. 2. Pathomorphological changes of placental vessels in COVID-19 during pregnancy, showing the percentage of CD34 monoclonal antibody expression in the endothelium of chorionic villous arterioles (brown shades) analyzed using ONLINE JPG TOOLS. A – Subgroup I.2; B – Subgroup II.2; C – Subgroup I.1; D – Subgroup II.1; E – Comparison group. ×200, expression of CD34 monoclonal antibodies in the endothelium of chorionic villous arterioles. ×200.

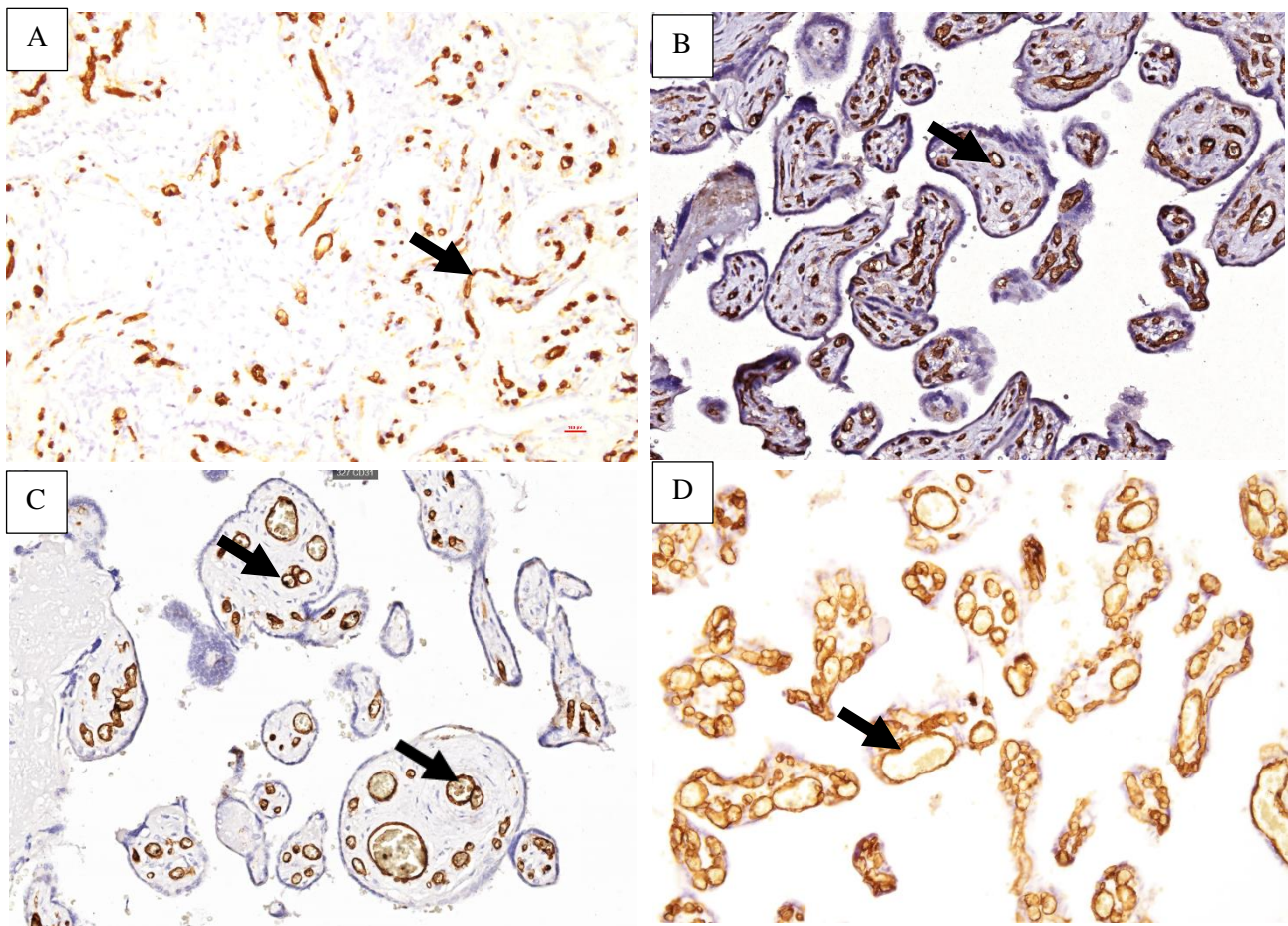


Fig. 3. Structural changes in the placenta in COVID-19 during pregnancy and in the control group. CD34 expression is shown in the nuclei of endothelial cells of chorionic villous vessels (arrows). A, B – Subgroups II.2 and I.2, respectively, showing endothelial necrosis and narrowed vascular lumens. C – Placenta of the control group, with CD34 expression observed in the endothelium of chorionic villous vessels (dark color along the vessel perimeter, arrows). Immunohistochemical staining using CD34 monoclonal antibodies, $\times 200$.

In COVID-19 during pregnancy, the lumens of chorionic villous vessels were reduced and exhibited edema. The vessels were located closer to the center of the villi, resulting in thickening of the vasculosyncytial membrane. With an increase in the post-COVID interval, the vessel lumens gradually recovered. In Subgroup II.1, despite lumen restoration, the number of vessels remained reduced, the vasculosyncytial membranes were thickened, stromal fibrosis was present, and revascularization of previously obliterated arteriolar lumens was observed (Fig. 2.B, arrows).

The main manifestation of COVID-19 in the placenta was the presence of placentitis, indicating endothelial dysfunction. Microscopic examination of all observations in the main groups revealed placentitis (Table 1). Chorioamnionitis and basal deciduitis were observed in the acute period of the disease in pregnant women in 100% of cases. Intervillositis was detected in 100% of cases during antenatal fetal asphyxia. Villitis in Subgroup II.2 was observed in 95.5% [82.1–100]. In live-born

infants (Subgroup I.2), intervillitis occurred in only 26.8%, and villitis in 22.6% [17–28.8].

With increasing duration of the post-COVID interval, the frequency of inflammation in the placental tissue decreased (Subgroup I.1) – intervillitis was observed in 7.3%. Chorioamnionitis in Subgroup I.1 was found in 95.5% of cases, and basal deciduitis in 95.3%; in Subgroup II.1 – 25% and 72.7%, respectively. The severity of inflammatory manifestations decreased in Subgroups I.1 and II.1.

The observed pathomorphological changes in the placenta led to a quantitative decrease in CD34 expression in the endothelium of chorionic villous arterioles.

Conclusions. In pregnant women with COVID-19, a reduction in the expression of the immunohistochemical marker CD34 in the placenta was observed, indicating endothelial dysfunction.

Author Contributions:

The author confirms their contribution to the work: concept and study design, data collection, analysis and interpretation of results, verification, reviewing, and editing – T. V. Savchuk.

The author confirms their contribution to the work: concept and study design, verification, reviewing, and editing – I. V. Leshchenko.

References:

1. Beyerstedt, S., Casaro, E. B., Rangel, É. B. (2021). COVID-19: angiotensin-converting enzyme 2 (ACE2) expression and tissue susceptibility to SARS-CoV-2 infection. *European Journal of Clinical Microbiology & Infectious Diseases*, 40(5). <https://doi.org/10.1007/s10096-020-04138-6> [in English].
2. Bryce, C., Grimes, Z., Pujadas, E., Ahuja, S., Beasley, M. B., Albrecht, R., & Petersen, B. (2021). Pathophysiology of SARS-CoV-2: the Mount Sinai COVID-19 autopsy experience. *Modern Pathology*, 1–12. <https://doi.org/10.1038/s41379-021-00793-y> [in English].
3. Deanfield, J.E., Halcox, J.P. & Rabelink, T.J. (2007). Endothelial Function and Dysfunction. *Circulation*, 115(10), 1285–1295. <https://doi.org/10.1161/circulationaha.106.652859> [in English].
4. Baergen, R. N., & Heller, D. S. (2020). Placental Pathology in Covid-19 Positive Mothers: Preliminary Findings. *Pediatric and Developmental Pathology*, 23(3), 177–180. <https://doi.org/10.1177/1093526620925569> [in English].
5. Savchuk, T. V., Leshchenko, I. V., Vaslovych, V. V., Chernenko, O. H., & Malysheva, T. A. (2025). Coronavirus disease 2019 (COVID-19) during pregnancy: Pathomorphological changes in the terminal villi of the placenta. *Polski merkuriusz lekarski: organ Polskiego Towarzystwa Lekarskiego*, 53(4), 485–494. <https://doi.org/10.36740/merkur202504108> [in English].
6. Giordano, G., Petrolini, C., Corradini, E., Campanini, N., Esposito, S., & Perrone, S. (2021). COVID-19 in pregnancy: placental pathological patterns and effect on perinatal outcome in five cases. *Diagnostic Pathology*, 16(1). <https://doi.org/10.1186/s13000-021-01148-6> [in English].
7. Corbetta-Rastelli, C. M., Altendahl, M., Gasper, C., Goldstein, J., Afshar, Y., & Gaw, S. L. (2023). Analysis of placental pathology after COVID-19 by timing and severity of infection. *American Journal of Obstetrics & Gynecology, Maternal-Fetal Medicine*, 5(7), 100981–100981. <https://doi.org/10.1016/j.ajogmf.2023.100981> [in English].
8. Kramar, S., Nebesna Z., Yakymchuk Yu., Boychuk, A., Shevchuk, O., Korda, M., & Vari, S. G. (2025). Changes in Placentas of Pregnant Women Infected with COVID-19. *International*

Journal of Molecular Sciences, 26(17), 8596–8596. <https://doi.org/10.3390/ijms26178596> [in English].

9. Savchuk, T.V. Patomorfologichni zmini placenti pri koronavirusnij hvorobi (COVID-19) u vagitnih u drugomu ta tret'omu trimestrah vagitnosti. *Medichni perspektivi*. [Pathomorphological changes of the placenta in coronavirus disease (COVID-19) in pregnant women in the second and third trimesters of pregnancy]. *Medichni Perspektivi*. 2024. №4 (29). С. 84–94. <https://doi.org/10.26641/2307-0404.2024.4.319224> [in Ukrainian].

10. Tian, X., Li, C., Huang, A., Xia, S., Lu, S., Shi, Z., & Ying, T. (2020). Potent binding of 2019 novel coronavirus spike protein by a SARS coronavirus-specific human monoclonal antibody. *Emerging Microbes & Infections*, 9(1), 382–385. <https://doi.org/10.1080/22221751.2020.1729069>

11. Savchuk, T. Patomorfologichni zmini placenti v gostrij period COVID-19 u vagitnih zhinok. *Skhidnoukraïns'kij medichnij zhurnal*. [Pathomorphological changes of the placenta in the acute period of COVID-19 in pregnant women]. *Eastern Ukrainian Medical Journal*. 2024. №2 (12). С. 323–334. [https://doi.org/10.21272/eumj.2024;12\(2\):323-334](https://doi.org/10.21272/eumj.2024;12(2):323-334) [in Ukrainian].

Література:

1. Beyerstedt, S., Casaro, E.B., Rangel, É.B. (2021). COVID-19: angiotensin-converting enzyme 2 (ACE2) expression and tissue susceptibility to SARS-CoV-2 infection. *European Journal of Clinical Microbiology & Infectious Diseases*, 40(5). <https://doi.org/10.1007/s10096-020-04138-6>.

2. Bryce, C., Grimes, Z., Pujadas, E., et all. Pathophysiology of SARS-CoV-2: the Mount Sinai COVID-19 autopsy experience. *Modern Pathology*. 2021; 1–12. <https://doi.org/10.1038/s41379-021-00793-y>

3. Deanfield, J.E., Halcox, J.P., Rabelink, T.J. (2007). Endothelial Function and Dysfunction. *Circulation*, 115(10), 1285–1295. <https://doi.org/10.1161/circulationaha.106.652859>

4. Baergen, R.N., & Heller, D.S. Placental Pathology in Covid-19 Positive Mothers: Preliminary Findings. *Pediatric and Developmental Pathology*. 2020. 23(3), 177–180. <https://doi.org/10.1177/1093526620925569>

5. Savchuk, T.V., Leshchenko, I.V., Vaslovysh, V.V., Chernenko, O. H., & Malysheva, T. A. Coronavirus disease 2019 (COVID-19) during pregnancy: Pathomorphological changes in the terminal villi of the placenta. *Polski merkuriusz lekarski: organ Polskiego Towarzystwa Lekarskiego*. 2025. 53(4), 485–494. <https://doi.org/10.36740/merkur202504108>

6. Giordano, G., Petrolini, C., Corradini, E., Campanini, N., Esposito, S., & Perrone, S. COVID-19 in pregnancy: placental pathological patterns and effect on perinatal outcome in five cases. *Diagnostic Pathology*, 2021. 16(1). <https://doi.org/10.1186/s13000-021-01148-6>

7. Corbetta-Rastelli, C. M., Altendahl, M., Gasper, C., Goldstein, J., Afshar, Y., & Gaw, S. L. Analysis of placental pathology after COVID-19 by timing and severity of infection. *American Journal of Obstetrics & Gynecology, Maternal-Fetal Medicine*. 2023. 5(7), 100981–100981. <https://doi.org/10.1016/j.ajogmf.2023.100981>

8. Kramar, S., Nebesna Z., Yakymchuk Yu., Boychuk, A., Shevchuk, O., Korda, M., & Vari, S. G. Changes in Placentas of Pregnant Women Infected with COVID-19. *International Journal of Molecular Sciences*. 2025. 26(17), 8596–8596. <https://doi.org/10.3390/ijms26178596>

9. Савчук, Т.В. Патоморфологічні зміни плаценти при коронавірусній хворобі (COVID-19) у вагітних у другому та третьому триместрах вагітності. *Медичні перспективи*. 2024. №4 (29). С. 84–94. <https://doi.org/10.26641/2307-0404.2024.4.319224>

10. Tian, X., Li, C., Huang, A., et all. Potent binding of 2019 novel coronavirus spike protein by a SARS coronavirus-specific human monoclonal antibody. *Emerging Microbes & Infections*. 2020. 9(1), 382–385. <https://doi.org/10.1080/22221751.2020.1729069>

11. Савчук, Т.В. Патоморфологічні зміни плаценти в гострий період COVID-19 у вагітної. *Східноукраїнський медичний журнал*. 2024. №2 (12). С. 323–334. [https://doi.org/10.21272/eumj.2024;12\(2\):323-334](https://doi.org/10.21272/eumj.2024;12(2):323-334)

Дата першого надходження статті до видання: 03.03.2026

Дата прийняття статті до друку після рецензування: 18.03.2026