

# Improvement of methods for prevention of postoperative hyposplenism in traumatic spleen injuries

I.V. Kolosovych, I.V. Hanol

*Bogomolets National Medical University, Kyiv; e-mail: ganoli@ukr.net*

*Splenectomy in patients with massive splenic injuries is associated with the risk of postoperative hyposplenism syndrome. The aim of the work was to improve methods for the prevention of postoperative hyposplenism in traumatic splenic injuries. At the first stage, it was found that the average length of the second-order splenic arteries is  $1.3 \pm 0.2$  cm, from which small vessels with a diameter of  $120.8 \pm 29.1$   $\mu$ m depart, which participate in the formation of arteriovenous complexes located under the capsule of the organ. At the second stage, methods for preventing postoperative hyposplenism in case of traumatic injuries of the organ of degrees III–V in patients of the main group were improved and implemented. It was established that the presence of spleen tissue with main blood flow ensures the stability of the organ's filtering function. At the same time, splenectomy was accompanied by serious disorders in the form of the appearance of destroyed and pathologically altered erythrocytes in the peripheral blood. Also, according to the results of sonographic examination, an increase in the area of the remaining spleen parenchyma was detected in the case of subtotal resection of the organ with the formation of parenchymal couplings around the second-order arteries by 21.4% after two months, and by 40.2% after a year. In the case of subtotal spleen resection with covering the cut plane with an adhesive hemostatic plate, the area increase after 2 months was 27.3%, after a year - 49.1%. The implementation of the developed methods for the prevention of postoperative hyposplenism in patients with traumatic spleen injury of III–V degree allows to reduce the frequency of complications in the early postoperative period in the case of isolated injury from 29.4% to 5.0% and in the long-term postoperative period from 30.0% to 2.9%.*

*Key words: spleen; injuries; splenectomy; physiology; hyposplenism; organ-saving surgery.*

## INTRODUCTION

The spleen contains 25% of the body's lymphoid mass, receives 350 liters of blood per day, purifies 4% of its circulating volume per minute, and plays an important role in the humoral and cellular defense mechanisms of the body. The structural elements of the red pulp of the spleen participate in blood filtration, removal of bacteria, damaged erythrocytes, and cellular debris, the white pulp of the spleen is represented by lymphoid tissue [1]. At the same time, along with the well-known functions of the spleen, in studies devoted to cellular technologies, the topic of regulating regenerative processes in damaged organs and tissues of various phenotypes using spleen tissue, which is characterized by not only immunogenetic but also morphogenetic functions, is widely discussed [2].

Treatment of traumatic injuries of the spleen remains one of the urgent problems of modern surgery, which is due to the high frequency of this pathology (15.5-30% of the total number of injuries of the abdominal organs), mortality (7-26%) and the risk of complications in the postoperative period (5-60%) [3]. The tactics and method of managing a patient with a spleen injury are determined by the degree of injury, the patient's condition during surgery, concomitant pathology and hemocoagulation disorders in massive blood loss [4]. Until now, the most common method of treating this pathology is surgical treatment, especially in cases of traumatic organ injuries of III–V degrees according to the classification of «The American Association for the Surgery of Trauma» [5]. However, known methods of surgical hemostasis

(gas-current and electro-thermocoagulation, the action of low temperatures) do not always meet the requirements of modern medicine, do not provide the required degree of reliability of stopping bleeding, and have side effects that complicate and prolong the rehabilitation period [6]. Under these circumstances, splenectomy is currently the most common surgical intervention for splenic trauma. However, this operation can cause severe complications, both in the early and late postoperative periods, arising from impaired immunological hemostasis and called postoperative hyposplenism [7]. One of the ways to prevent these complications is autotransplantation of spleen tissue, which has a number of disadvantages: slow regeneration of pulp structures, development of reticular tissue filled with erythrocytes (replacement of red pulp) with a deficiency of white pulp elements [8]. In addition, there is a high probability of graft rejection due to the lack of vascularization, the development of their necrosis, which increases the risk of purulent-septic and thromboembolic complications and postoperative hyposplenism in emergency surgery to 30% [9]. Therefore, the organ-preserving concept of surgical treatment of splenic injury, which is being worked out in experimental and clinical studies, is currently attracting special attention.

The aim of the study was to improve methods for preventing postoperative hyposplenism in traumatic spleen injuries.

## METHODS

The work was carried out in compliance with the existing international principles of the «Declaration of Helsinki of the World Medical Association on Ethical Principles of Scientific Medical Research Involving Human Subjects» (1964-2008), the «Convention of the Council of Europe on Human Rights and Biomedicine» (1997) and the current «Order of the Ministry of Health of Ukraine No. 960» dated September 23, 2009. The study was performed according to the original protocol, consisted of two stages

and was approved by the Bioethics Commission of Bogomolets National Medical University (Protocol No. 12/3 dated December 17, 2015). At the first stage, the peculiarities of the blood supply to the splenic hilum were studied on sectioned material. The spleen, together with the organs of the abdominal and thoracic cavities, and the retroperitoneal space, were isolated in one block using the generally accepted method of pathological dissection according to the Shor method. Subsequently, the spleen was dissected while preserving its hilum, fatty tissue, vessels, proximal ligaments, and their structures. Histological examination began with the excision of a macropreparation consisting of the spleen capsule, adipose tissue of its hilum at a distance from the point of entry of the splenic vessels into the spleen parenchyma, measuring 1×1.5 cm, followed by fixation with 10% neutral formalin and staining with hematoxylin and eosin. Preparation of preparations was carried out according to the standard method for 5-7 days, followed by examination with a conventional and electron microscope and morphometry of the detected vessels.

Given the results obtained, methods of treating traumatic injuries of the spleen of grades III–V and preventing postoperative hyposplenism were improved. The first technique, atypical resection of the spleen with covering the cut plane with an adhesive hemostatic plate, was used in cases of injuries of grades III–IV (removal of up to ½ of the organ). 17 patients were operated on using this technique. The second technique, which was used in traumatic injuries of the spleen of grades IV–V (removal of more than ¾ of the organ), consisted of subtotal resection of the spleen with excision of the parenchyma in the form of sleeves around the second-order arteries. 18 patients were operated on using this technique.

The second stage of the study analyzed the results of the examination and treatment of 68 patients with traumatic injuries of the spleen of grades III–V, who were treated in the clinic of the Department of Surgery No. 2

of Bogomolets National Medical University (based on the surgical department of the «Kyiv City Clinical Hospital No. 4», «Kyiv City Clinical Hospital No. 17») in the period from 2015 to 2023. Exclusion criteria were: severe concomitant diseases of the lungs, liver, kidneys; hematological diseases; use of anticoagulants, antiplatelet agents within three months before inclusion in the study; mental illnesses; patient refusal to participate in the study. Depending on the chosen treatment tactics, patients were divided into the main group ( $n = 35$ , advanced treatment methods were used) and the comparison group ( $n = 33$ , splenectomy was performed). When comparing patients in the study groups by age ( $42.7 \pm 4.1$  and  $44.3 \pm 5.9$  years,  $P = 0.19$ , respectively), gender (men 65.7% and 72.7%, women 34.3% and 27.3%,  $P = 0.53$ , respectively), cause of injury (blunt injury 74.3% and 75.8%, stab wound 25.7% and 24.2%,  $P = 0.88$ , respectively), nature of injury (isolated injuries 57.1% and 51.5%, multiple injuries 42.9% and 48.5%,  $P > 0.05$ , respectively), frequency of hemorrhagic shock (25.7% and 30.3%,  $P = 0.67$ , respectively) and sum of points according to the Charlson comorbidity index ( $0.8 \pm 0.6$  and  $0.9 \pm 0.7$ ,  $P = 0.52$ , respectively) no significant difference was obtained.

To assess the effectiveness of surgical tactics in the studied groups, changes in the filtering function of the spleen were analyzed in the early postoperative period (examination of the peripheral blood of patients to detect aging, damaged and pathologically altered erythrocytes (Pappenheim staining)), in the early and long-term (outpatient observation for one year) postoperative periods, sonographic examination of the abdominal organs was performed (assessment of the degree of regeneration of spleen tissue), and the frequency of complications and deaths was compared.

Statistical analysis was performed using Statistica 12 (Serial Number: STA999K347150-W) and MEDCALC® (open-access Internet resource, <https://www.medcalc.org/calc/>). Results are

presented as mean values and their standard deviation ( $M \pm SD$ ) in the case of parametric distribution and as median and quartile ( $Me (Q1; Q3)$ ) in the case of nonparametric data distribution. Differences in indicators between groups were determined using the t-test in the case of linear indicators and using the  $\chi^2$ -test in the case of categorical indicators.

## RESULTS

At the first stage of the study, it was established that the average length of second-order arteries is  $1.3 \pm 0.2$  cm, small branches depart from them, which participate in the formation of arteriovenous complexes located under the spleen capsule (Fig. 1).

Histological examination of the splenic hilum revealed additional small arterial-type vessels with a diameter of  $120.8 \pm 29.1 \mu m$ , which penetrate the capsule and supply blood to the corresponding areas of the parenchyma (Fig. 2).

At the second stage of work in the early postoperative period, when analyzing changes in the filtering function of the spleen in patients in the comparison group, an increase in the number of destroyed (fragmented) erythrocytes was noted (Fig. 3A) and the appearance of a large number

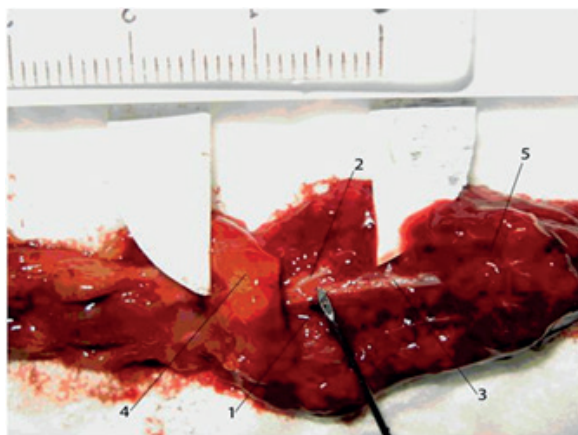


Fig. 1. Macroscopic preparation of the second-order arterial vessels of the spleen, where: 1 - the second-order artery itself; 2 - a small branch departing from the second-order artery; 3 - the place of dichotomous division of the artery into the third order; 4 - the splenic capsule; 5 - the splenic parenchyma




Fig. 2. Histological examination of the splenic hilum, vascular morphometry (hematoxylin-eosin staining, objective  $\times 10$ , eyepiece 23, Leica DM LS2 microscope, Canon Power Shot S50 camera, Program AE Photo Effect Mode off image management program): muscular artery, diameter is  $110.7 \mu\text{m}$

of acanthocytes, target-like cells, stomatocytes, erythrocytes with different sizes and hemoglobin content (Fig. 3B).

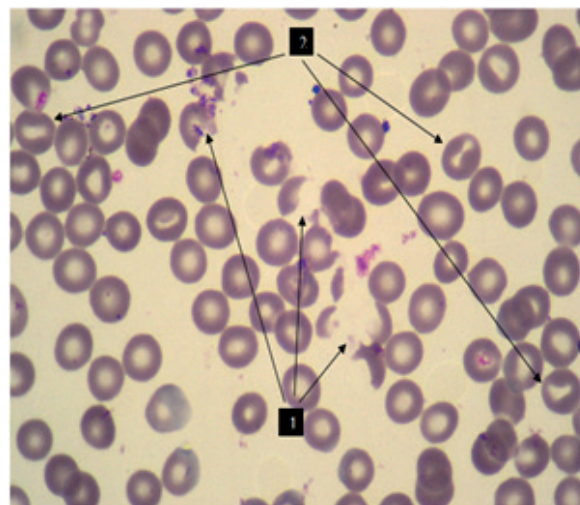
In patients of the main group, when using the method of subtotal spleen resection, the appearance of target-recognizing cells, acanthocytes and halocytes was also observed, however, their number was insignificant and did not exceed 3.0% (Fig. 4A), at the same time, fragmented, damaged erythrocytes were not detected in the studied blood preparations (Fig. 4B).

At the same time, in patients of the main group who underwent atypical spleen resection, destroyed and pathologically altered erythrocytes were not visualized, i.e., changes in the filtering function of the spleen were not observed.

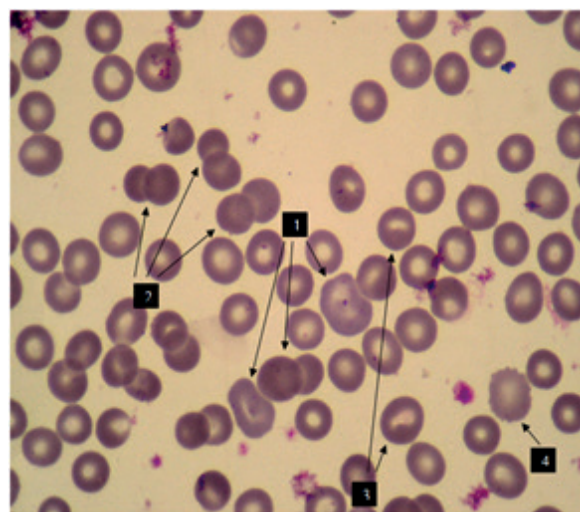
During sonographic examination of the abdominal organs of the main group of patients who underwent subtotal splenic resection in the early postoperative period, the dimensions of the spleen stump did not differ from the intraoperative ones. However, when examining the structure of the spleen tissue in this category of patients in the long postoperative period, a decrease in heterogeneity and an increase in the size of the remaining parenchyma were detected (Fig. 5A and 5B).

In patients who underwent atypical spleen resection, the area increase at the examination two months after the operation was 27.3% (20.5–34.1), and after a year – 49.1% (36.8–61.4) compared to the initial data.

The analysis of the frequency of complications in the studied groups in the early postoperative



A



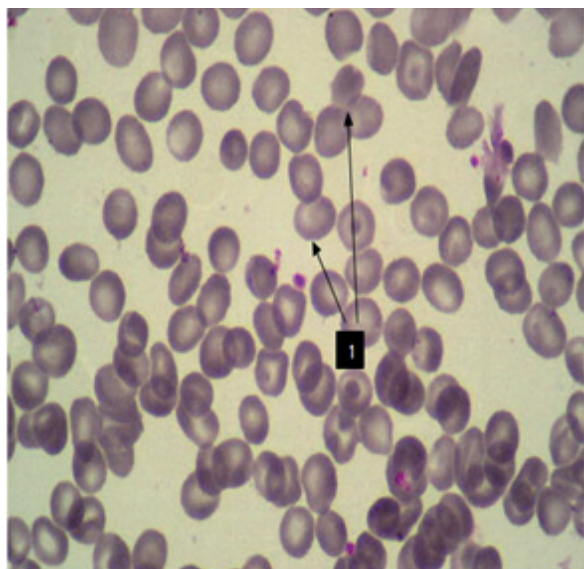
B

Fig. 3. Red blood cell examination in patients of the comparison group (Pappenheim staining, objective  $\times 10$ , eyepiece 20, Olympus CX 41 microscope), where A: 1 - anisocytosis, hypochromia of erythrocytes, a significant number of fragmented erythrocytes, 2 - a significant number of stomatocytes; B: 1 - pronounced anisocytosis, with the presence of giant erythrocytes, 2 - hyperchromia of erythrocytes, 3 - a significant number of stomatocytes, 4 - acanthocyte

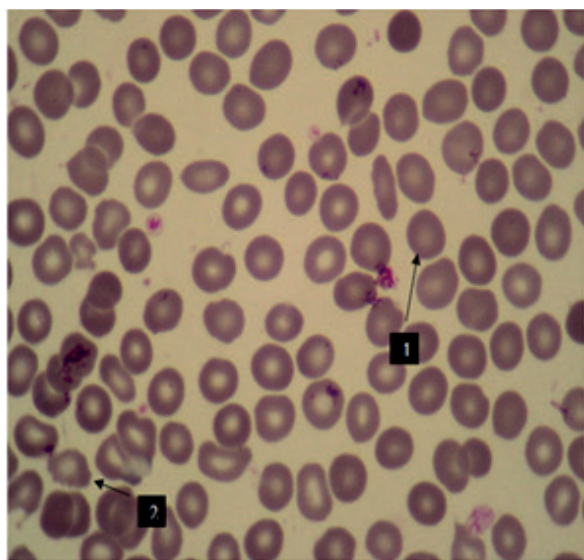
period was carried out taking into account the nature of traumatic injuries and was divided into patients with isolated and multiple injuries (Table).

When comparing the frequency of complications in the long-term period in the studied

groups, a significant difference was obtained in the total number of complications (the main group - in 2.9% (1/35), the comparison group - in 30.0% (9/30) patients,  $P = 0.002$ , respectively), while inflammatory diseases of the respiratory system were observed in 2.9% (1/35) patients in the main group and 20.0% (6/30) patients in the comparison group ( $P = 0.02$ ), and purulent skin diseases (3.3% (1/30) patients,  $P = 0.28$ , respectively), vegetative-vascular dystonia (3.3% (1/30) patients,  $P = 0.28$ , respectively) and allergic diseases (3.3% (1/30) patients,  $P = 0.28$ , respectively) only in patients in the comparison group.

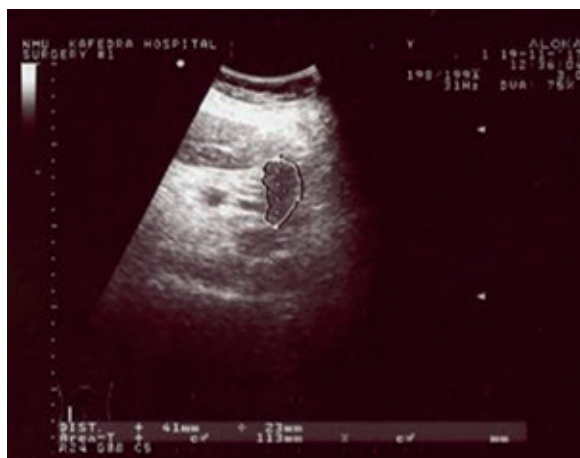

A

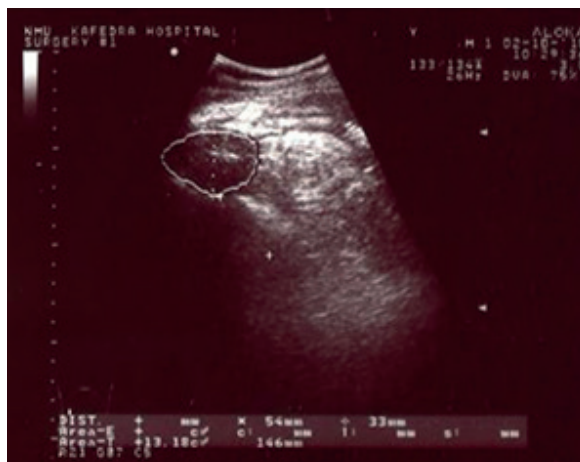

B

Fig. 4. Red blood cell examination in patients of the main group, method of subtotal splenectomy with formation of parenchymal couplings (Pappenheim staining, objective  $\times 10$ , eyepiece 20, Olympus CX 41 microscope), where A: 1 - single target-like cells; B: 1 - halocyte, 2 - acanthocyte



A



B

Fig. 5. Ultrasound scan of the remaining area of parenchyma after subtotal splenic resection: A - two months after surgical treatment; B - one year after surgical treatment

Nature of complications in the studied groups in the early postoperative period

Type of complication	Comparison group		Main group	
	Isolated injury (n = 17)	Multiple trauma (n = 16)	Isolated injury (n = 20)	Multiple trauma (n = 15)
Intra-abdominal bleeding	–	1(6,25%)	–	–
Inflammatory diseases of the respiratory system	2 (11,8%)	2(12,5%)	1(5%)	1 (6,7%)
Postoperative wound suppuration	2 (11,8%)	3 (18,8%)	–	1 (6,7%)
Portal vein thrombosis	1 (5,9%)	–	–	–
Total	5 (29,4%)	7 (37,5%)	1 (5%) *	2 (13,3%)

P < 0.05 when comparing to the comparison group.

It is also worth noting that there were no deaths among the patients in the main group, while in the comparison group the mortality was 9.1% (3/33) and was observed only in the early postoperative period in patients with multiple injuries. In these circumstances, the causes of death were: disseminated intravascular coagulation syndrome (1/33 (3.0%)) and bilateral polysegmental pneumonia (2/33 (6.1%)).

## DISCUSSION

The spleen is an organ that performs a number of important functions aimed at protecting the body. However, splenectomy remains the most common method of treating massive spleen injuries, the performance of which is associated with the risk of imbalance of humoral and cellular immunity, susceptibility to viral infections, respiratory diseases, and oncological pathology [10]. One of the ways to prevent these complications is autotransplantation of spleen tissue, but a number of studies indicate that preserving the parenchyma with the main blood flow is a more effective procedure [11]. Thus, the size of the capillary vessels that develop during heterotopic autotransplantation of spleen tissue and accompany organ regeneration is  $9.7 \pm 0.4 \mu\text{m}$  [12]. We have obtained histological data that confirm the point of view regarding the existence of arterial branches that depart from the second-order splenic arteries, penetrate the capsule and supply blood to the adjacent areas

of the parenchyma. The connecting link between these arteries is the arteriovenous vascular network, which is located under the capsule of the organ, while the average diameter of these arteries is  $120.8 \pm 29.1 \mu\text{m}$ . Taking into account the results obtained, methods of treating traumatic injuries of the spleen of stages III–V were improved, which are based on temporary ligation of the vessels of the splenic hilum with subsequent covering of the plane of the organ section with an adhesive hemostatic plate, or cutting out the parenchyma in the form of sleeves around the second-order arteries. The pathophysiological mechanism of prevention of postoperative hyposplenism when using the developed surgical techniques is to preserve the functioning part of the spleen with good blood supply (due to both red and white pulp). The proposed organ-preserving surgical interventions have undeniable advantages compared to the traditional method of autotransplantation, in which, in the case of restoration of local blood flow of the remaining organ stump, the spleen parenchyma regenerates exclusively due to elements similar to the red pulp, and there is no restoration of the white pulp.

Later, when studying changes in the filtration function of the spleen in the early postoperative period, it was found that the presence of even a small amount of parenchyma with main blood flow ensures the preservation of the filtering function of the organ, while its removal is accompanied by serious disorders, which

manifests itself in the form of the appearance of destroyed and pathologically altered erythrocytes in the peripheral blood in an amount exceeding the norm (more than 3.0%) [13]. Also, according to the results of the sonographic examination, an increase in the area of the remaining spleen parenchyma was detected in the case of using the method of subtotal resection of the organ after two months by 21.4% (16.5-26.6), after a year - by 40.2% (30.2-50.3) compared to the initial data and the method of atypical resection of the spleen - by 27.3% (20.5-34.1) and 49.1% (36.8-61.4), respectively. However, according to other studies, the restoration of the filtration function of the spleen in the case of autotransplantation of its tissue is observed only 30 days after the intervention, the regeneration of the parenchyma occurs slowly and is accompanied by the predominant development of reticular tissue [14]. In our opinion, the results obtained can be explained by the preservation of a larger amount of spleen tissue when using the proposed improved methods of surgical intervention compared to autotransplantation, less traumatization of the parenchyma, and as a result, more effective functioning of the spleen in the postoperative period.

At the same time, the analysis of the early and long-term postoperative periods revealed a dependence of the frequency of complications and deaths on both the type of surgical intervention used and the nature of the injuries. At the same time, the introduction of improved treatment methods made it possible to significantly reduce the frequency of complications in the early postoperative period in patients of the main group with isolated injuries by 24.4% ( $\chi^2 = 3.91$ , 95% CI 0.22-48.47,  $P = 0.04$ ), to outline a tendency to decrease in patients with multiple complications by 24.2% ( $P > 0.05$ ) and to reduce deaths by 9.1% ( $P = 0.07$ ). There was also a significant reduction in the incidence of complications in the late postoperative period by 27.1% ( $\chi^2 = 8.96$ , 95% CI 9.36-45.13,  $P = 0.002$ ).

Thus, improved methods of preventing

postoperative hyposplenism, which involve the use of organ-preserving surgical interventions with preservation of the main blood flow (the possibility of regeneration of the spleen parenchyma with the presence of elements of both red and white pulp), improve the course of the postoperative period and are superior in effectiveness to autotransplantation of spleen tissue in traumatic organ injuries.

## CONCLUSIONS

1. The average length of the second-order splenic arteries is  $1.3 \pm 0.2$  cm, from them depart small vessels with a diameter of  $120.8 \pm 29.1$   $\mu\text{m}$ , which participate in the formation of arteriovenous complexes located under the capsule.

2. The obtained data on the features of blood circulation in the spleen explain the possibilities of regeneration of its tissue due to elements of the white and red pulp while preserving the parenchyma in the hilar region.

3. The presence of spleen tissue with a main blood flow ensures the stability of the organ's filtering function, while splenectomy is accompanied by serious disorders, manifested in the appearance of destroyed and pathologically altered erythrocytes in the peripheral blood.

4. The implementation of the developed methods for the prevention of postoperative hyposplenism in patients with traumatic spleen injury of III-V degree allows a significant reduction in the frequency of complications in the early postoperative period in the case of isolated injury from 29.4% to 5.0% and in the long-term postoperative period from 30% to 2.9%.

*The work was performed in accordance with the plan of research work of the Department of Surgery No. 2 of Bogomolets National Medical University: «Development and implementation of methods of diagnosis and treatment of acute and chronic surgical pathology of abdominal organs». The authors did not receive additional financial support.*

*The authors of this study confirm that the research and publication of the results were not associated with any conflicts regarding commercial or financial relations, relations with organizations and/or individuals who may have been related to the study, and interrelations of co-authors of the article.*

**І.В. Колосович, І.В. Ганоль**

## **УДОСКОНАЛЕННЯ МЕТОДІВ ПРО- ФІЛАКТИКИ ПІСЛЯОПЕРАЦІЙНОГО ГІПОСПЛЕНІЗМУ ПРИ ТРАВМАТИЧНИХ УШКОДЖЕННЯХ СЕЛЕЗІНКИ**

*Національний медичний університет  
імені О.О. Богомольця, Київ; e-mail: ganoli@ukr.net*

Виконання спленектомії у пацієнтів з масивними ушкодженнями селезінки асоціюється з ризиком виникнення синдрому післяопераційного гіпоспленізму. Метою роботи було удосконалення методів профілактики післяопераційного гіпоспленізму при травматичних ушкодженнях селезінки. На першому етапі було виявлено, що середня довжина артерій селезінки другого порядку становить  $1,3 \pm 0,2$  см, від них відходять дрібні судини діаметром  $120,8 \pm 29,1$  мкм, які беруть участь в утворенні розташованих під капсулою органа артеріовенозних комплексів. На другому етапі були удосконалені та впроваджені способи профілактики післяопераційного гіпоспленізму у разі травматичних ушкоджень органа III–V ступенів у хворих основної групи. Встановлено, що наявність тканини селезінки з магістральним кровотоком забезпечує стабільність фільтруючої функції органа. Водночас спленектомія супроводжувалася серйозними порушеннями у вигляді появи в периферичній крові зруйнованих та патологічно змінених еритроцитів. Також за результатами сонографічного обстеження був виявлений приріст площі залишеної паренхіми селезінки у разі застосування субтотальної резекції органа з формуванням муфт паренхіми навколо артерій другого порядку через 2 міс на 21,4%, через рік – 40,2%. У разі застосування субтотальної резекції селезінки з укриванням площини зрізу клейовою гемостатичною пластиною приріст площі через 2 міс становив 27,3%, через рік – 49,1%. Впровадження розроблених способів профілактики післяопераційного гіпоспленізму у хворих на травматичне ушкодження селезінки III–V ступеня дає змогу знизити частоту розвитку ускладнень у ранньому післяопераційному періоді у разі ізольованої травми з 29,4 до 5,0% та у віддаленому післяопераційному періоді з 30,0 до 2,9%.

Ключові слова: селезінка; травми; спленектомія; фізіологія; гіпоспленізм; органозберігаюча хірургія.

## **REFERENCES**

1. Pavlovich SI, Grushka NG, Kondratska OA, Krasutska NO, Antonuyk VM, Meshko VV, Yanchiy RI. Histostructural changes in immunocompetent organs, liver, and lungs during experimental endotoxemia induced by lipopolysaccharide. *Fiziol Zh.* 2024; 70(5): 66-71. <https://doi.org/10.15407/fz70.05.066>
2. Ren M, Shang C, Zhong X, Guo R, Lao G, Wang X, Cheng H, Min J, Yan L, Shen J. Insulin-producing cells from embryonic stem cells rescues hyperglycemia via intra-spleen migration. *Sci Rep.* 2014 Dec 23;4:7586. doi: 10.1038/srep07586.
3. El-Matbouly M, Jabbour G, El-Menyar A, Peralta R, Abdelrahman H, Zarour A, Al-Hassani A, Al-Thani H. Blunt splenic trauma: Assessment, management and outcomes. *Surgeon.* 2016 Feb;14(1):52-8. doi: 10.1016/j.surge.2015.08.001.
4. Kolosovych IV, Hanol IV. Hemocoagulation factors of hemorrhagic complications in acute pancreatitis. *Fiziol Zh.* 2022, 68(1): 56-61. <https://doi.org/10.15407/fz68.01.056>
5. Abdel-Aziz H, Murray C, Roberts D, Capron G, Starr F, Bokhari F, Brigode W. The American association for the surgery of trauma organ injury scale for spleen does not equally predict interventions in penetrating and blunt trauma. *Am Surg.* 2023 Dec;89(12):5782-5. doi: 10.1177/00031348231175495.
6. Jesani H, Jesani L, Rangaraj A, Rasheed A. Splenic trauma, the way forward in reducing splenectomy: our 15-year experience. *Ann R Coll Surg Engl.* 2020 Apr;102(4):263-70. doi: 10.1308/rcsann.2019.0164.
7. Siu M, Levin D, Christiansen R, Kelly E, Alouidor R, Kamine TH. Prophylactic splenectomy and hyposplenism in spaceflight. *Aerosp Med Hum Perform.* 2022 Dec 1;93(12):877-81. doi: 10.3357/AMHP.6079.2022.
8. Di Carlo I, Toro A. Splenic autotransplantation is always valid after splenectomy. *J Invest Surg.* 2017 Dec;30(6):401-2. doi: 10.1080/08941939.2016.1268656.
9. Kolosovych IV, Hanol IV, Uzun H. Clinical-experimental justification of the method of prevention and treatment of appendicular pylephlebitis. *Fiziol Zh.* 2024, 70(3): 33-41. <https://doi.org/10.15407/fz70.03.033>
10. Kristinsson SY, Gridley G, Hoover RN, Check D, Landgren O. Long-term risks after splenectomy among 8,149 cancer-free American veterans: a cohort study with up to 27 years follow-up. *Haematologica.* 2014 Feb;99(2):392-8. doi: 10.3324/haematol.2013.092460.
11. Toro A, Parrinello NL, Schembari E, Mannino M, Corsale G, Triolo A, Palermo F, Romano A, Di Raimondo F, Di Carlo I. Single segment of spleen autotransplantation, after splenectomy for trauma, can restore splenic functions. *World J Emerg Surg.* 2020 Mar 4;15(1):17. doi: 10.1186/s13017-020-00299-z.
12. Holdsworth RJ. Regeneration of the spleen and splenic autotransplantation. *Br J Surg.* 1991 Mar;78(3):270-8. doi: 10.1002/bjs.1800780305.

13. Miko I, Nemeth N, Peto K, Furka A, Toth L, Furka I. Changes of red blood cell aggregation parameters in a long-term follow-up of splenectomy, spleen-autotransplantation and partial or subtotal spleen resections in a canine model. Clin Hemorheol Microcirc. 2017; 67(1):91-100. doi: 10.3233/CH-170264
14. Elchaninov A, Vishnyakova P, Lokhonina A, Kiseleva V, Menyailo E, Antonova M, Mamedov A, Arutyunyan I, Bolshakova G, Goldshtein D, Bao X, Fatkhudinov T, Sukhikh G. Spleen regeneration after subcutaneous heterotopic autotransplantation in a mouse model. Biol Res. 2023 Mar 29;56(1):15. doi: 10.1186/s40659-023-00427-4.

*Received 28.01.2025*