

Chin augmentation with custom-made implants for microgenia treatment: a two-year follow-up

I. G. Donets¹, O. V. Panchuk¹, K. V. Galperin²

¹ Liko-med clinic, Kyiv

² Bogomolets National Medical University, Kyiv

✉ Orest Panchuk: orestpv@gmail.com

I. G. Donets, Plastic surgeon, <http://orcid.org/0000-0001-6440-1442>

O. V. Panchuk, PhD, Plastic surgeon, <http://orcid.org/0000-0001-6962-6851>

K. V. Galperin, Senior assistant, <http://orcid.org/0000-0003-3227-0681>

OBJECTIVE — to determine the feasibility and effectiveness of using custom-made and 3D-printed mandibular implants in patients with microgenia, and to investigate their quality of life and satisfaction with aesthetic results during a two-year follow-up.

MATERIALS AND METHODS. 21 patients participated in the study, with 14 (66.7%) women and 7 (33.3%) men. The average age of patients was 23.4 ± 2.3 years. All patients had signs of microgenia. In our study, a CT scan of the skull without contrast enhancement served as the primary diagnostic tool. Polyetheretherketonen (PEEK) was the material of choice for the implants.

RESULTS. Among the early postoperative complications were alterations to the sensation of the skin overlying the lower lip, which was restored within 1–2 months, and bruising, which had a tendency to spread to the neck. None of the patients had impaired motor innervation of the lower lip. Hematoma and wound suppuration were not detected either. One or two years after surgery, none of the patients had any delayed complications, including implant displacement, bone resorption in the lower jaw, decreased motor activity of the facial muscles, or altered sensation affecting the lower lip. Aesthetic results were assessed after the one-year follow-up. In a sample of 21 patients, the aesthetic outcome was excellent in 18 (85.7%) patients and good in 3 (14.3%) patients. No patients had bad aesthetic outcomes.

CONCLUSIONS. The absence of delayed complications and the low risk of early complications, which in 71.4% of patients only present as a temporary alteration to the sensation affecting the lower lip, indicate the safety of the suggested method. In all patients after mentoplasty with custom-made implants, the physical and mental components of health improved statistically (with all values $p < 0.05$). Excellent aesthetic outcomes were observed in almost all patients (85.7%) after mentoplasty with custom-made implants.

KEYWORDS

mentoplasty, microgenia, chin plastic surgery.

ARTICLE • Received 2022-09-03 • Received in revised form 2022-09-08

© 2022 Authors. Published under the CC BY-ND 4.0 license

An underdeveloped chin, which symbolizes microgenia, creates an aesthetic problem, disrupting the balance and proportions of the face. In the literature, various methods of determining the degree of chin development deficiency and options for its increase are offered. The vast majority of authors focus on the choice of material and the method of operation rather than on the shape and size of the implant [4, 8, 11, 15].

The proportions of the ideal chin are described, the projection of which reaches the vertical plane lowered from the red border of the lower lip.

According to a popular preoperative assessment technique, the ideal chin profile is 1 mm to 3 mm from the vertical line extending from the red border of the lower lip. There is also no generally accepted classification of microgenia in the literature [12, 13, 18].

Microgeny correction methods using standard implants and osteoplastic operations have a high risk of developing complications. Among them, the main ones are: displacement of the implant (8%), bone resorption, which is observed already 19 months after the operation, nerve injury and

impaired sensory and motor functions in 3–12 %, infectious complications in 5–7 %, which leads to the removal of implants in 70–80 % of cases, capsular contracture of the implant in 1–4 %, aesthetic dissatisfaction with the result of the operation in 25–60 % of cases. The presence of a high risk of developing complications determines the search and development of new methods of treating microgenia [2, 7, 17].

In our practice, we consider chin bulge (chin curvature) as the main method of assessing the degree of microgenia. We perform this assessment based on a photograph of the patient in a lateral projection.

The placement of a chin implant has two primary effects on the appearance of the chin: it increases its projection and modifies its shape. The majority of publications focused on the calculation of the required projection as a basis for determining the size of the implant. However, the main limiting factor influencing the choice of implant size is the preoperative chin bulge or lack thereof. The total number of millimeters that can be added to different chin profiles is restricted. A fully convex chin allows an implant up to approximately 4 mm thick in the center, even if the chin is still far behind the vertical line from the red border of the lips. A thicker implant will increase the convexity of this chin beyond acceptable aesthetic prominence. On the other hand, a chin without convexity before surgery has a flat vertical or even a negative profile, which allows the use of increasingly thick implants that will improve the projection of the chin as well as increase its curvature to the maximum acceptable convexity. But standard implants do not take into account all the anatomical features of the shape and size of the lower jaw, the presence of asymmetries and protrusions on the bone surface. Also, they have a high risk of displacement and animation when talking, which is due to the lack of fixation of implants to firm structures [5, 6, 12, 19].

It is important to note that it is the thickness at the center of the implant (i.e., the projection of the implant) that has the largest impact on the outcome. The length and width of the implant have a negligible effect on the result. Most chin implant manufacturers do not take this information into consideration and produce «small» size implants that are smaller in all three dimensions (protrusion, height, and length), while «large» size implants are also larger in all dimensions.

Our practical experience in the treatment of microgenia is based on an individual approach to each patient. We develop the necessary shape and size of the implant, which allows us to meet the needs of each patient.

OBJECTIVE: to determine the feasibility and effectiveness of using custom-made and 3D-printed mandibular implants in patients with microgenia, and to investigate their quality of life and satisfaction with aesthetic results during a two-year follow-up.

Materials and methods

21 patients participated in the retrospective cohort study, with 14 (66.7 %) women and 7 (33.3 %) men. The average age of patients was 23.4 ± 2.3 years. Our study included patients with a severe form of underdevelopment of the lower jaw, which could not be corrected with the help of fillers and lipofilling. Patients were examined in the preoperative period according to the standards of the Ministry of Health of Ukraine.

In our study, a multispiral CT scan of the skull without contrast enhancement served as the primary diagnostic tool. It allowed for the evaluation of the severity of microgenia, assessment of the shape and size of facial bones, and creation of a 3D-model of the structure. This investigation enables visual assessment of the new implant: its shape and size. The projection of the new chin is coordinated with the patient, and after that, the implant is manufactured in the Imatech Medical laboratory. The 3D model allows the patient to visualize the future result, which is the best option for matching the shape and size of the future chin. Fig. 1 shows the modeling process of the chin implant model in different projections. Fig. 2 presents a collage of the skull model with and without the implant, illustrating how the shape and size of the bone influence the outcome.

Polyetheretherketonen (PEEK) was the material of choice for the implants, which is a semi-crystalline polymer resistant to high temperatures. All implants were produced by Imatech Medical. The implant itself is shown in Fig. 3, which demonstrates its final representation before sterilization. All materials and production processes for implants have been registered by the Ministry of Health of Ukraine and the relevant permits have been obtained.

The placement of the implants was carried out under general anesthesia. The procedure was done intraorally and, therefore, did not leave any noticeable scars on the face. After treating the surgical field with Octanisept, local anesthesia was applied to the oral mucosa and hydropreparation with a 0.9 % NaCl solution containing lidocaine 100 mg and adrenaline 1:400 ml was carried out. In the future, a supraperiosteal dissection was performed with the cutting off m. Mentalis. An autopsy was performed according to the size of the implants. The implant was placed and fixed with 2 titanium

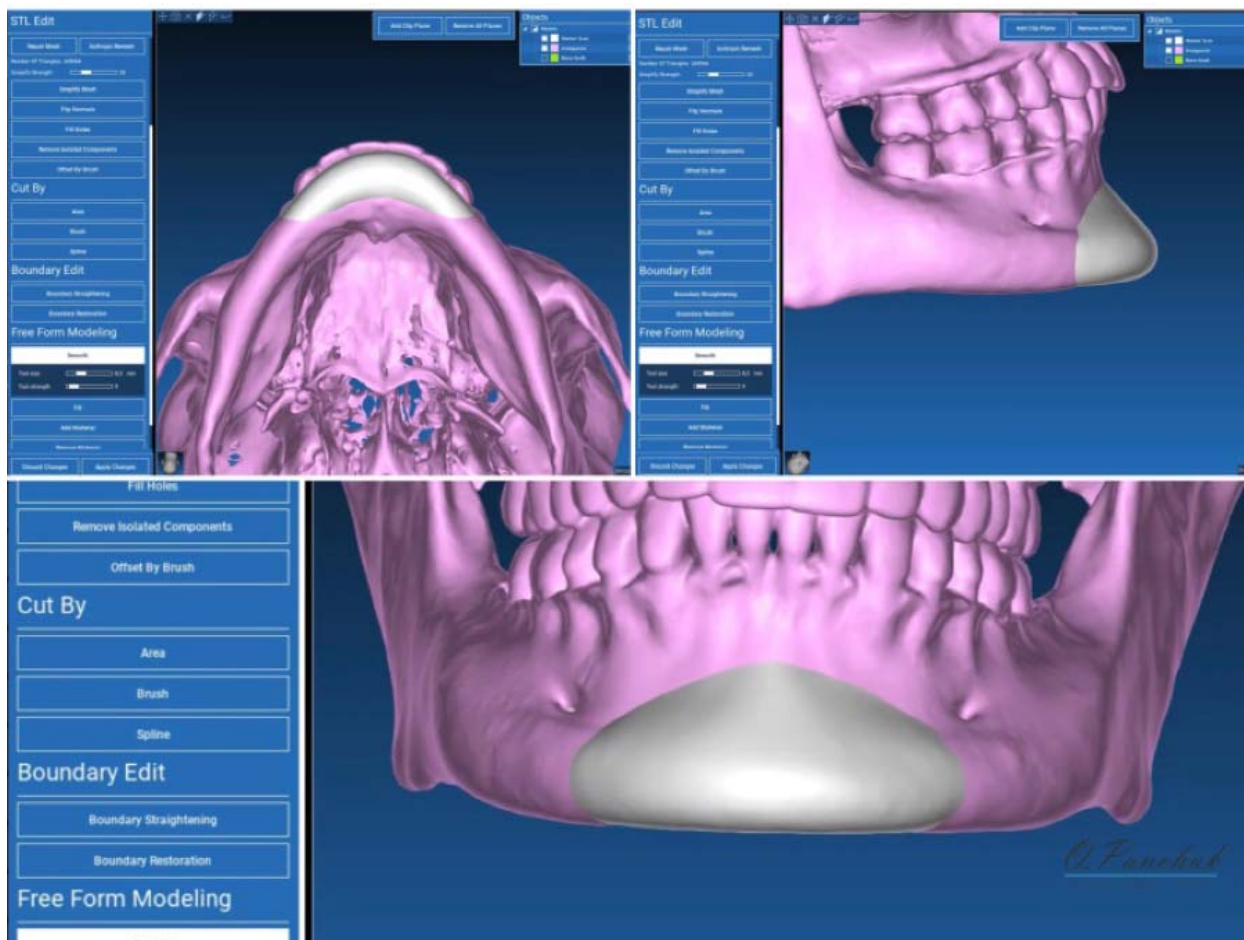


Figure 1. Chin implant model designed in different planes

screws in the lower jaw. Layer-by-layer suturing of the wound was performed with Vicryl 5–0 suture material and an aseptic bandage was applied. In the postoperative period, patients were bandaged, and the oral cavity was treated with antiseptics.

The international MOS-SF-36 questionnaire was used to assess the patients' quality of life after mentoplasty.

For an additional assessment of the aesthetic outcome, we developed and introduced our own questionnaire that was offered to all patients who underwent surgery. The questionnaire is presented in Fig. 4. It consists of three questions that are designed to gather data on the patient's age, the type of surgical intervention, and the patient's overall satisfaction with surgical outcomes. The survey was anonymous.

The aesthetic outcome was measured using a 3-point scale. The main criteria were the presence of postoperative complications in the early and remote periods and satisfaction with the aesthetic results. Patients were referred to the «poor» result category in the presence of serious postoperative complications (suppuration, deformations, impaired motor innervation of the lip, displacement

of the implant). If the patient was satisfied with the aesthetic outcome, but there were certain aesthetic or functional deficiencies, it was classified as a «good» result. The absence of complications and complete satisfaction with the aesthetic outcome were considered an «excellent» result.

Results and discussion

The average duration of the operation was 49.1 ± 4.6 minutes. The patients stayed in the hospital for one day. Regular examinations took place once every 3–4 days. After surgery, pronounced swelling was noted for 9–15 days. In the postoperative period, all patients underwent routine examinations after 1, 3, 6 months and 1 year. 16 patients had a repeat CT scan of the skull two years after surgery. Five patients underwent CT scans a year after surgery as their follow-up period still continues. The maximum period of observation lasted two years.

The photofixation was carried out immediately after the operation for demonstration of the obtained result to the patients, since later the swelling increased and the final surgical outcome was

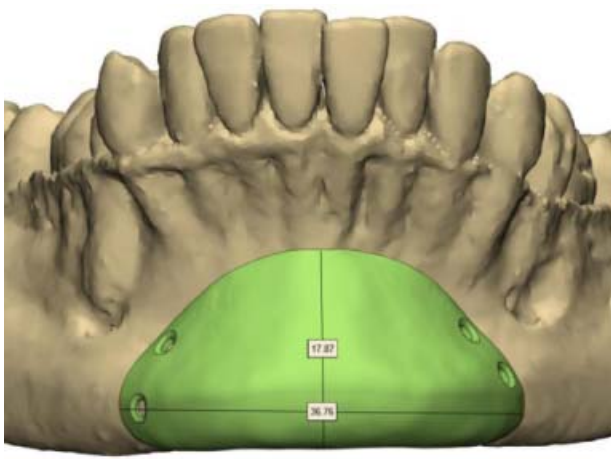
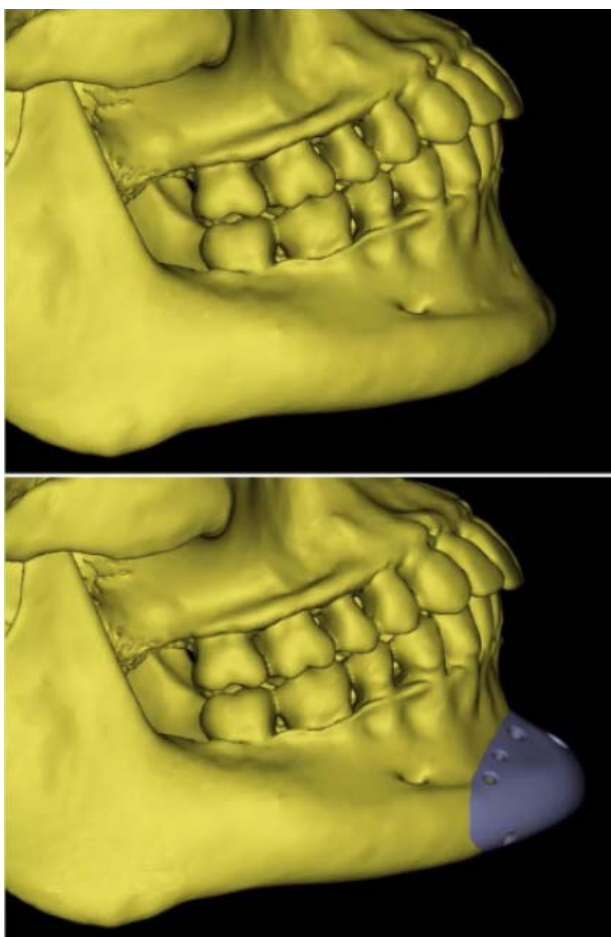


Figure 2. A 3D model of the skull showing the shape and size of the future chin



Figure 3. The final representation of the chin implant

QUESTIONNAIRE

to determine whether you are satisfied with the aesthetic result of the operation

1. How old are you?

2. Have you had mentoplasty performed using an individual implant?
 Yes No

3. Please rate your aesthetic result after the surgery?

Have you had serious postoperative complications (infection, deformities, impaired motor innervation of the lip, displacement of the implant)?	Bad	<input type="checkbox"/>
The aesthetic result suits me, but there are certain aesthetic or functional flaws!	Good	<input type="checkbox"/>
I am completely satisfied with the aesthetic result!	Perfect	<input type="checkbox"/>

Figure 4. Questionnaire form for conducting an anonymous survey of patients regarding their satisfaction with the aesthetic outcome

evaluated 2–3 months after surgery. Fig. 5 shows the patient in a lateral projection before and immediately after the operation.

When repeating a CT scan of the head in the remote period, we made a 3D model of the skull, which helped to visually assess the shape of the chin, the position of the implant, and the presence of other

complications. Fig. 6 shows the CT model of the patient's skull before surgery and one year after the placement of the custom-made mandibular implant.

Among the early postoperative complications were alterations to the sensation of the skin overlying the lower lip, which was restored within 1–2 months. None of the patients had impaired motor

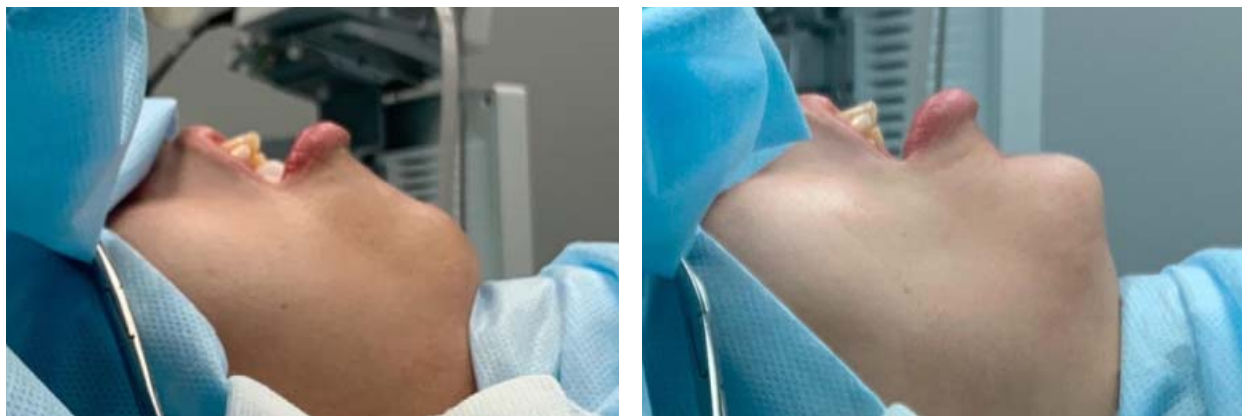

Figure 5. Photo of a lateral projection before and after the placement of the mandibular implant

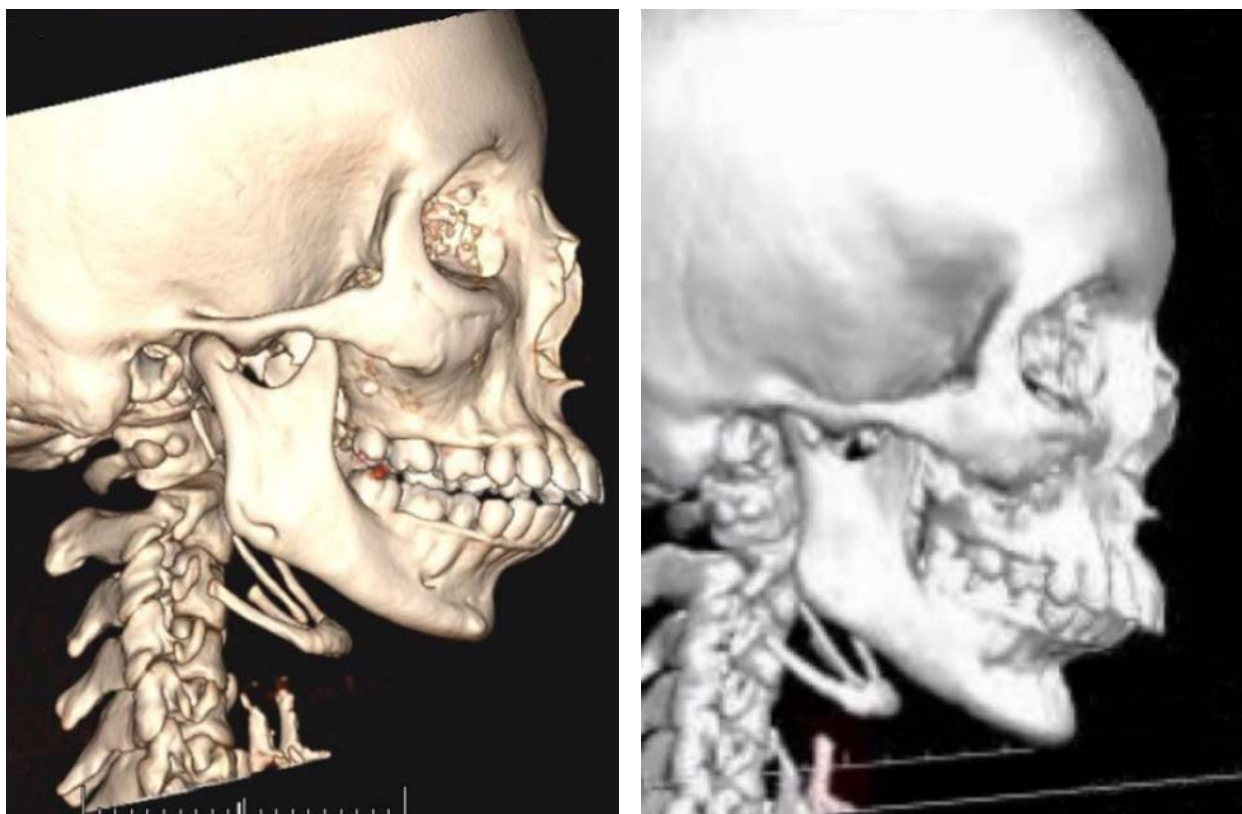


Figure 6. 3D CT model of the skull before and one year after surgery

innervation of the lower lip (0%). Hematoma and wound suppuration were not detected either (0%), which is presented in Table 1.

The patients' quality of life and the presence of implant-related complications were taken into account during the extended follow-up period. A CT-scan of the skull was performed one or two years after surgery. None of the patients had any delayed complications, including implant displacement, bone resorption in the lower jaw, decreased motor activity of the facial muscles, or altered sensation affecting the lower lip.

Table 1. Early complications that occurred in patients

Complication type	Complications
Seroma	0
Hematoma	0
Wound suppuration	0
Decreased motor activity of the facial muscles	0
Altered sensation affecting the lower lip	15 (71.4%)
Total number	15 (71.4%)

Table 2. Average indicators of patient quality of life in the study groups before and one year after surgery

Indicator	Before surgery	One year after surgery
Physical functioning	72.78 ± 7.28	89.44 ± 4.76*
Role physical	76.11 ± 5.51	82.45 ± 7.24**
Bodily pain	78.73 ± 5.41	82.54 ± 5.66**
General health	74.22 ± 5.91	76.37 ± 7.13**
Vitality	67.37 ± 9.57	80.39 ± 9.81**
Social functioning	66.31 ± 8.03	84.97 ± 8.27**
Role emotional	64.75 ± 13.60	79.98 ± 9.11**
Mental health	65.87 ± 10.92	78.6 ± 12.07**

Note. * p=0.001; ** p<0.001.

Fig. 7 shows a radiograph of the head of a patient who had a silicone implant 8 years ago. The red arrows show the area of bone resorption caused by the pressure and displacement of the silicone implant. The level of resorption reaches 6 mm at the maximum projection. Fig. 8 shows a 3D CT model of the patient's skull after the placement of a silicone implant. The displacement of its position, which creates an aesthetic defect, is noted.

Five and 10 years following the placement of the implants of this design, the study patients are scheduled to undergo routine CT scans of the head to monitor any potential bone resorption in the lower jaw and to evaluate implant displacement.

The MOS-SF-36 questionnaire findings for patient quality of life are shown in Table 2.

Before the operation, all patients expressed a desire to improve the shape and size of their chin because it created an inferiority complex and prevented them from feeling confident in social situations. It should be noted that they stated a progressive decrease in their ability to concentrate and, accordingly, to perform work as accurately as they could before. Their social discomfort was also manifested by the presence of nervousness, anxiety, and irritability.

One year after surgery, the average values of all indicators of quality of life increased significantly, as can be seen in consolidated Table 2. In general, a statistically significant improvement in all quality of life indicators is noted, which reflects the improvement of physical and mental components. Fig. 9 shows the patient before and one year after surgery. An increase in the projection of the chin and a change in the aesthetic shape and proportions of the face are noted. The patient gave written permission to use the photographs.

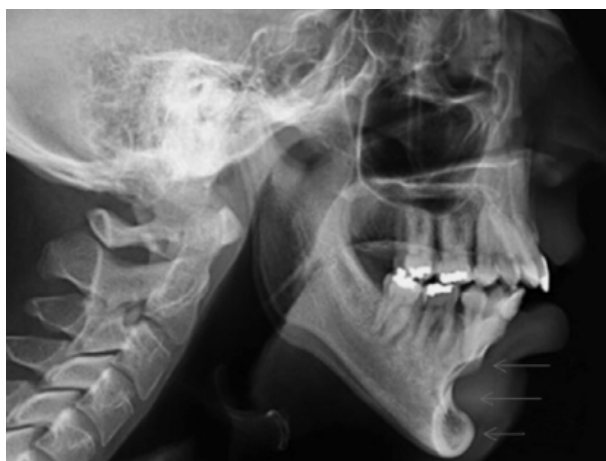

Figure 7. Lateral radiograph of the head in a patient with a silicone chin implant and severe bone resorption

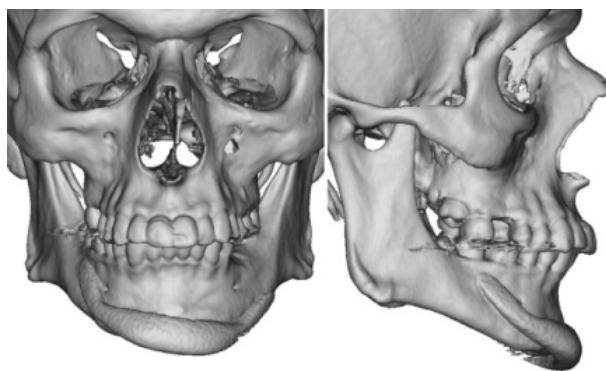


Figure 8. CT model of the skull of a patient with a silicone chin implant and its displacement

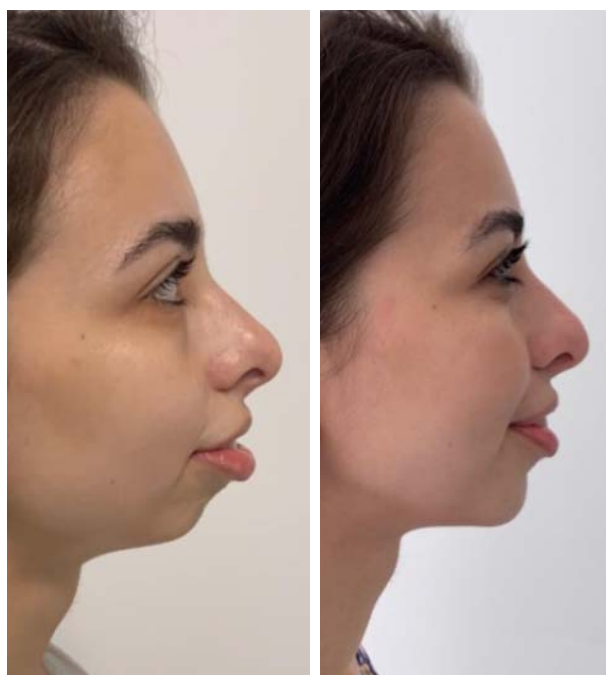

Figure 9. Photo before and one year after chin augmentation with a custom-made implant

Aesthetic results were assessed after the one-year follow-up. In a sample of 21 patients, the aesthetic outcome was excellent in 18 (85.7%) patients and good in 3 (14.3%) patients. No patients had bad aesthetic outcomes. Patients with a good result noted insufficient chin projection and wanted to increase it by several millimeters.

Bone resorption is a common complication associated with chin implants [14].

This complication arises due to a number of factors. In our opinion, this type of complication can be related to implant displacement towards the alveolar edge of the lower jaw, where the bone is thinner and under constant pressure. The literature review, radiographs, and CT images demonstrate that bone resorption most often occurs when the implant is displaced from the mandibular tubercle. According to our findings, no study reported mandibular bone resorption after augmentation mentoplasty when the implant was clearly positioned on the mandibular tubercle.

The use of 3D printing technology for manufacturing custom-made implants has rapidly developed in many fields of medicine, including plastic surgery [9, 10, 16].

For aesthetic surgery, 3D-printed custom-made implants are an ideal solution for correcting defects or deformities of the facial skull. However, biocompatible materials for 3D printing are not easily available and are expensive. Thus, we have combined and improved the way we use 3D imaging and printing technology to improve the results of chin augmentation surgery.

Chin augmentation using an alloplastic implant is the main method of correcting the contour of the lower jaw [1].

The traditional method of chin augmentation requires choosing a standard silicone implant from the available manufacturer's catalog and placing it under the periosteum. However, factory-made silicone implants are usually limited in size and often shift or rotate around the axis of the implant, which deforms the contour of the chin [1, 3].

The ideal chin implant should be designed with the internal and external surfaces in mind. If the inner surface exactly corresponds to the contour and shape of the lower jaw, then displacement and rotation do not occur even without additional fixation with a screw, which is seen in Fig. 10. It shows the manufactured implant of the lower jaw, its front and back surfaces. The printed model of the patient's lower jaw reflects all the protrusions and irregularities of the chin for which the implant was designed. The jaw model clearly shows asymmetry and irregularities that would not allow for the placement of a standard silicone implant. Therefore, forming the surface

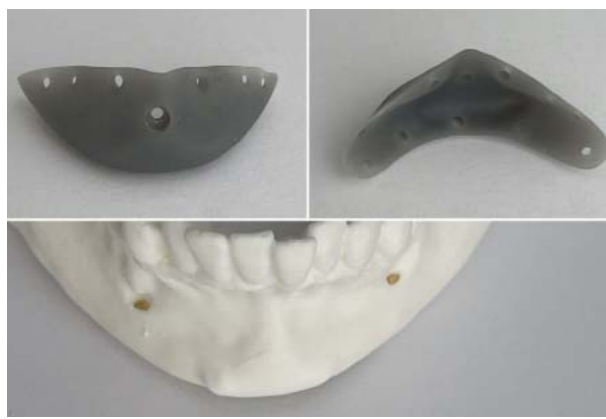

Figure 10. **Prototype implant and printed mandibular model showing uneven jaw surface**

of the implant with the help of a 3D image allows you to accurately produce the necessary contour.

To place a chin implant, either a skin incision in the submental area or an incision in the mucous membrane of the oral cavity is used. The skin incision on the chin provides quick access to the mandibular bone surface and allows easy lateral dissection to prevent nerve injury and minimize damage to the m. mentalis [21]. However, there will be a visible scar, which sometimes causes discomfort or even the development of depressive states in patients and affects the aesthetic result. The incision made in the oral mucosa does not leave a visible scar. In our practice, a mucosal incision is used to place implants. The main advantage of this incision type is the absence of external scars, and additionally, the 3D model shows the exact position of the mental opening, which helps to prevent nerve damage and to make an implant that takes into account all these anatomical features [20].

The long-term effects of treatment beyond 2 years have not been researched. The results of this study are based on a two-year follow-up, which is a short period for this type of surgery. However, it should be noted that no delayed complications or implant displacement were detected one or two years after surgery.

Conclusions

Chin plastic surgery using custom-made implants is a safe method of mentoplasty that ensures good aesthetic results that are predicted and agreed with the patient.

The absence of delayed complications and the low risk of early complications, which in 71.4% of patients only present as a temporary alteration to the sensation affecting the lower lip, indicate the safety of the suggested method.

In all patients after mentoplasty with custom-made implants, the physical and mental components of health improved statistically (with all values $p < 0.05$), which indicates the effectiveness of this type of surgery in achieving a desirable appearance and reducing psychological difficulties.

According to the questionnaire findings, excellent aesthetic outcomes were observed in almost all patients (85.7%) after mentoplasty with custom-made implants.

Thus, patients who had their chin implants individually designed and fitted, taking into account their main requirements, have better indicators of quality of life and satisfaction with the aesthetic outcome.

DECLARATION OF INTERESTS

The authors declare no conflicts of interest.

Funding. The authors did not receive any additional financial support.

ETHICS APPROVAL AND WRITTEN

INFORMED CONSENTS STATEMENTS

All procedures performed in the study and involving human participants were carried out in accordance with the ethical standards of the institutional and/or national research committee, 1964 Helsinki declaration and its later amendments or comparable ethical standards. Written informed consent was obtained from all individual participants included in the study.

AUTHORS CONTRIBUTIONS

Concept and design of the study: I. G. Donets, O. V. Panchuk. Literature review and discussion of the results: I. G. Donets, O. V. Panchuk, K. V. Galperin. Materials and research methods; carrying out research: O. V. Panchuk.

REFERENCES

1. Atef M, Mounir M, Shawky M, Mounir S, Gibaly A. Polyetheretherketone patient-specific implants (PPSI) for the reconstruction of two different mandibular contour deformities. *Oral Maxillofac Surg*. 2022 Jun;26(2):299-309.
2. Avelar KL, Sa CD, Esses DF, Becker OE, Soares EC, de Oliveira RB. Unusual complication after genioplasty. *J Craniofac Surg*. 2014;25(2):180-2.
3. Chang JB, Small KH, Choi M, Karp NS. Three-dimensional surface imaging in plastic surgery: foundation, practical applications, and beyond. *Plast Reconstr Surg*. 2015;135(5):1295-1304.
4. Goldsmith D, Horowitz A, Orentlicher G. Facial skeletal augmentation using custom facial implants. *Atlas Oral and Maxillofac Surg Clin N Am*. 2012;20:119-34.
5. Greenberg AM. Cone beam computed tomography scanning and diagnosis for dental implants. *Oral Maxillofac Surg Clin North Am*. 2015;27(2):185-202.
6. Greenberg AM, Eppley B. Facial implant cosmetic augmentation using digital technologies. In: Greenberg, A. (eds) *Digital Technologies in Craniomaxillofacial Surgery*. Springer, New York, NY; 2018.
7. Hwang K, Lee WJ, Song YB, Chung IH. Vulnerability of the inferior alveolar nerve and mental nerve during genioplasty: an anatomic study. *J Craniofac Surg*. 2005;16(1):10-4.
8. Iyengar RJ, Gabrick K, Bruckman K, Steinbacher DM. Fat grafting in orthognathic surgery. *J Craniofac Surg*. 2019;30(3):639-43.
9. Kamali P, Dean D, Skoracki R, et al. The current role of three-dimensional printing in plastic surgery. *Plast Reconstr Surg*. 2016;137(3):1045-55.
10. Kim GB, Lee S, Kim H et al. Three-dimensional printing: basic principles and applications in medicine and radiology. *Korean J Radiol*. 2016;17(2):182-97.
11. Newberry CI, Mobley SR. Chin augmentation using silastic implants. *Facial Plast Surg*. 2019;35(02):149-57.
12. Nocini R, D'Agostino A, Trevisiol L, Favero V. Mandibular recontouring with polyetheretherketone (PEEK) patient-specific implants. *BMJ Case Rep*. 2022 Apr 12;15(4):e248826.
13. Jones BM, Vesely MJ. Osseous genioplasty in facial aesthetic surgery—a personal perspective reviewing 54 patients. *J Plast Reconstr Aesthet Surg*. 2006;59:1177-87.
14. Peled IJ, Wexler MR, Ticher S, et al. Mandibular resorption from silicone chin implants in children. *J Oral Maxillofac Surg*. 1986;44:346.
15. Rohrich RJ, Sannic K, Afroz PN. Autologous fat grafting to the chin: a useful adjunct in complete aesthetic facial rejuvenation. *Plast Reconstr Surg*. 2018;142(4):921-5.
16. Rose AS, Webster CE, Harrysson OL, Formeister EJ, Rawal RB, Iseli CE. Pre-operative simulation of pediatric mastoid surgery with 3D-printed temporal bone models. *Int J Pediatr Otorhinolaryngol*. 2015;79(5):740-4.
17. Sciaraffia CE, Ahumada MF, Parada FJ, Gonzalez E, Prado A. Bone Resorption after Use of Silicone Chin Implants, Long-term Follow-up Study with Lateral Chin Radiography. *Plast Reconstr Surg Glob Open*. 2018 Jul 9;6(7):e1850.
18. Spira M, Yuksel E. Genioplasty. *Semin Plast Surg*. 2003;17:145-55. Jones BM, Vesely MJ.
19. Steinbacher D. *Aesthetic orthognathic surgery and rhinoplasty*. Hoboken: Wiley; 2019. P. 289-329.
20. Ortiz-Díaz C, Echevarría E, Guerrero LM, Rivas-Tumanyan S, Elias A. Bone remodeling under screw-fixed chin implants in patients with microgenia: a cross-sectional study. *Am J Cosm Surg*. 2021;38:75-85.
21. White JB, Dufresne CR. Management and avoidance of complications in chin augmentation. *Aesthet Surg J*. 2011;31(6):634-42.

Збільшення підборіддя індивідуально виготовленими імплантатами для лікування мікрогенії у 2-річному спостереженні

Є. Г. Донець¹, О. В. Панчук¹, К. В. Гальперин²

¹ Клініка «Ліко-мед», Київ

² Національний медичний університет імені О. О. Богомольця, Київ

Мета — визначити можливість та ефективність використання індивідуально підібраних та виготовлених імплантатів нижньої щелепи у пацієнтів з мікрогенією, дослідити якість їх життя та задоволеність естетичним результатом у дворічному спостереженні.

Матеріали та методи. Дослідження проведено у 21 пацієнта, з них 14 (66,7%) жінок та 7 (33,3%) чоловіків. Середній вік хворих становив $(23,4 \pm 2,3)$ року. У всіх пацієнтів спостерігалися ознаки мікрогенії. Основним діагностичним методом була комп'ютерна томографія черепа без контрастування. Обраним матеріалом для імплантатів був полієфірефіркетон (PEEK).

Результати. Із ускладнень у ранній післяопераційний період зареєстровано порушення чутливості шкіри нижньої губи, яке зникло протягом 1–2 міс, синці, які мали тенденцію до поширення на шию. Порушення рухової іннервації нижньої губи, гематоми та нагноєння рани не виявлено в жодного пацієнта. Із пізніх ускладнень (через 1–2 роки) у жодного пацієнта не спостерігали зміщення імплантату, резорбції кісткової тканини нижньої щелепи, порушення рухової активності м'язів обличчя та чутливості нижньої губи.

Естетичний результат оцінювали через 1 рік після операції. Відмінний результат зафіксовано у 18 (85,7%) випадках, добрий — у 3 (14,3%). У жодного пацієнта не було поганого результату.

Висновки. Низький ризик розвитку ранніх ускладнень (лише тимчасове порушення чутливості нижньої губи в 71,4% випадків) і відсутність пізніх ускладнень свідчать про безпечність запропонованої методики. У всіх пацієнтів після ментопластики індивідуальними імплантатами статистично поліпшилися фізичний та психічний компоненти якості життя (в усіх випадках $p < 0,05$). Естетичний результат був відмінним у більшості пацієнтів (85,7%).

Ключові слова: ментопластика, мікрогенія, пластика підборіддя.

FOR CITATION

■ Donets IG, Panchuk OV, Galperin KV. Chin augmentation with custom-made implants for microgenia treatment: a two-year follow-up. General Surgery (Ukraine). 2022;2:20-28. <http://doi.org/10.30978/GS-2022-2-20>.