

# An algorithm for the diagnosis of sacrococcygeal pilonidal disease in resource-limited settings

D. Dubenko, Y. Susak

Bogomolets National Medical University, Kyiv

✉ Dmytro Dubenko: [dubenko@nmu.ua](mailto:dubenko@nmu.ua)

D. Dubenko, <http://orcid.org/0000-0002-3016-0799>

Y. Susak, <http://orcid.org/0000-0002-5102-485X>

Pilonidal disease (PD) is a very common condition. In the countries of the global West, which have high per capita income and advanced health care systems, the average lifetime incidence is about 26 cases per 100,000 people. In the USA, about 70,000 new cases of the disease are registered annually. The full-scale aggression of the Russian Federation in February 2022 resulted in a drastic decline in access to high-quality health care in Ukraine, particularly affecting people living in temporarily occupied territories, communities with significant destruction, and internally displaced persons. Pilonidal disease substantially reduces patients' working capacity, diminishes their quality of life, and, in some cases, can result in severe complications that pose an immediate threat to their lives.

**OBJECTIVE** — to develop a standardised algorithm for diagnosing sacrococcygeal pilonidal sinus disease (PD) in resource-limited settings (combat zones, territories located in the close vicinity of the theatre of military operations where the population does not have full access to specialised health services; de-occupied territories, which are temporarily deprived of access to qualified medical personnel and appropriate technical resources).

A standardised algorithm for diagnosing PD has been developed. It consists of nine stages organised into consecutive blocks. Each stage is designed according to the «task-step-commentary» principle and includes detailed explanations for performing the diagnostic procedure.

**CONCLUSIONS.** Sacrococcygeal pilonidal sinus disease is a common condition that requires timely diagnosis and further management. In resource-limited settings, the creation of diagnostic algorithms is one of the important ways to improve access to health services.

## KEYWORDS

pilonidal disease, pilonidal abscess, weakly granulating wounds, diagnosis, algorithm, limited resources.

**ARTICLE** • Received 2023-10-28 • Received in revised form 2023-11-19

© 2023 Authors. Published under the CC BY-ND 4.0 license

Pilonidal disease (PD) is a very common condition [12]. In the countries of the global West, which have high per capita income and advanced health care systems, the average lifetime incidence is about 26 cases per 100,000 people [9]. In the USA, about 70,000 new cases of the disease are registered annually. [13]. Statistics show that the incidence increases between the second and third decades of life (60 % of registered cases occur between the ages of 18 and 30) [7]. Male gender is a statistically significant risk factor, as men are affected twice as frequently as women. Other risk factors include a high body mass index, excessive hair growth in specific body areas (primarily the back, gluteal, and sacrococcygeal areas), a deep intergluteal cleft (anatomical term «natal

cleft», which is defined as a groove that separates the two glutes from each other and extends downwards from the sacrum to the anal canal), belonging to certain ethnic groups with a high hair index, and inadequate basic perianal and general hygiene [4].

The full-scale aggression of the Russian Federation in February 2022 resulted in a drastic decline in access to high-quality health services in Ukraine, particularly affecting people living in temporarily occupied territories, communities with significant destruction, and internally displaced persons [5].

Pilonidal disease substantially reduces patients' working capacity, diminishes their quality of life, and, in some cases, can result in severe complications that pose an immediate threat to their lives.

Taking into account the statistically significant prevalence of pilonidal disease, the increasing impact of specific risk factors within the population, and the temporary poor access to medical resources for certain demographic groups, it is pertinent to develop a standardised algorithm for diagnosing this disease. This algorithm should not depend on the availability of PD specialists or diagnostic facilities as specified by regulatory guidelines.

**OBJECTIVE** – to develop a standardised algorithm for diagnosing sacrococcygeal pilonidal disease in resource-limited settings (combat zones, territories located in the close vicinity of the theatre of military operations where the population does not have full access to specialised health services; de-occupied territories, which are temporarily deprived of access to qualified medical personnel and appropriate technical resources).

### Diagnostic standards for sacrococcygeal pilonidal sinus disease

According to current recommendations [8], PD (regardless of its forms) is a clinically confirmed diagnosis. This statement is most applicable to the acute manifestation of PD, known as pilonidal abscess (PA). To establish a diagnosis of PD, the patient's typical complaints and the related history, as well as physical examination findings, are taken into account. However, sacrococcygeal PD must be carefully differentiated from purulent hidradenitis, local furunculosis, perianal manifestations of Crohn's disease, perianal fistulas and abscesses, and specific infectious lesions (syphilis, tuberculosis, and actinomycosis) [14].

The full-scale diagnostic process is most commonly performed in specialised facilities or surgical departments, where clinicians with substantial experience in the management of proctological diseases are available. However, additional imaging and instrumental investigations are frequently required for a reliable diagnosis of PD, establishing its form, and determining treatment strategies. MRI and ultrasound (including transrectal ultrasonography) are now the most effective diagnostic tools for PD [1].

In recent years, a number of studies have focused on the use of ultrasonography to assess PD. Surface ultrasound was proposed as an accurate method for diagnosing PA. However, it was found to be more effective in the differential diagnosis of PD and perianal fistulas [10]. Recent research findings have identified MRI as a valuable tool for investigating complicated PD cases, especially for differential diagnosis [6]. Preoperative MRI has been established as the standard for evaluating perianal fistulas based on the results of several multicentre studies [2, 3].

However, in resource-limited settings, it is not possible to conduct the entire spectrum of clinical and instrumental investigations outlined above. Furthermore, there is a shortage of doctors with the necessary specialisation and experience to provide these particular health services. As a result, we believe it is critical to develop simplified diagnostic algorithms that will allow for the timely diagnosis of PD and its further adequate treatment.

### Diagnostic algorithm for sacrococcygeal pilonidal sinus disease

The proposed algorithm is based on the typical clinical knowledge and skills possessed by a doctor, regardless of their primary specialisation. The implementation of the proposed algorithm requires minimal material and technical resources, including examination gloves, antiseptic solution, sterile dressing material, dye (methylene blue or diamond green), atraumatic probe or large-diameter elastic catheter, Mosquito forceps, or anatomical tweezers.

The algorithm consists of nine stages that are implemented in sequence. Each stage regulates the establishment and evaluation of factors that either support the diagnosis of PD or suggest the presence of other diseases that may share similar clinical and morphological characteristics with PD.

#### Stages of the algorithm

- 1 Probable diagnosis of PD
- 2 Differential diagnosis of PD
- 3 Clear establishment of anatomical landmarks
- 4 Examination of the patient in a standing position
- 5 Examination of the sacrococcygeal area in Bozeman's position (knee-elbow position)
- 6 Examination of the perianal area (anal triangle) in Bozeman's position (knee-elbow position)
- 7 Digital rectal examination of the patient in Bozeman's position (knee-elbow position)
- 8 Inspection and probing of fistula passages
- 9 Staining of fistula passages

Each stage consists of tasks and steps that must be completed throughout the evaluation of the patient. The article provides comments on typical physical findings and includes relevant illustrations.

#### Stage 1

**Task** | Determine the probability of PD

**Steps** | Assess the probability of PD, its form, stage, and severity

*Commentary:* At this stage, the patient's characteristic complaints (pain, discomfort, or a feeling of swelling in the sacrococcygeal area, discharge of purulent or serous consistency) are combined with

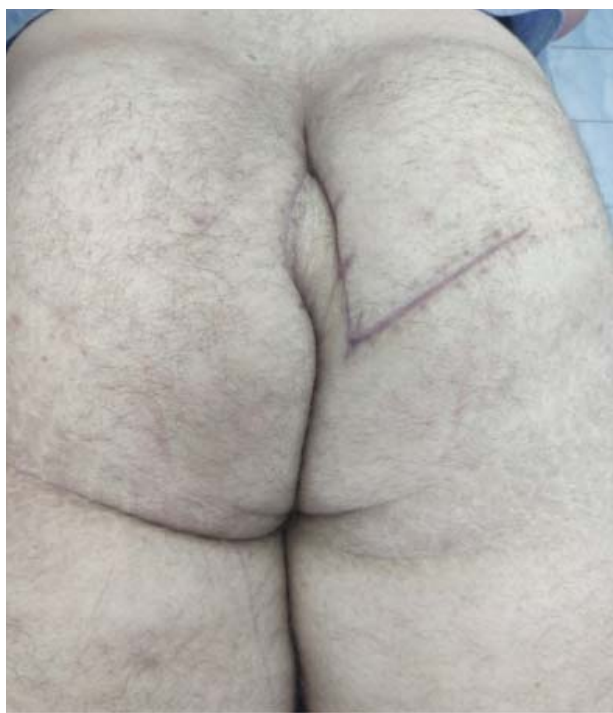

Figure 1. **Postoperative scars in the gluteal and sacrococcygeal areas (result of surgical treatment of a recurrent pilonidal cyst)**

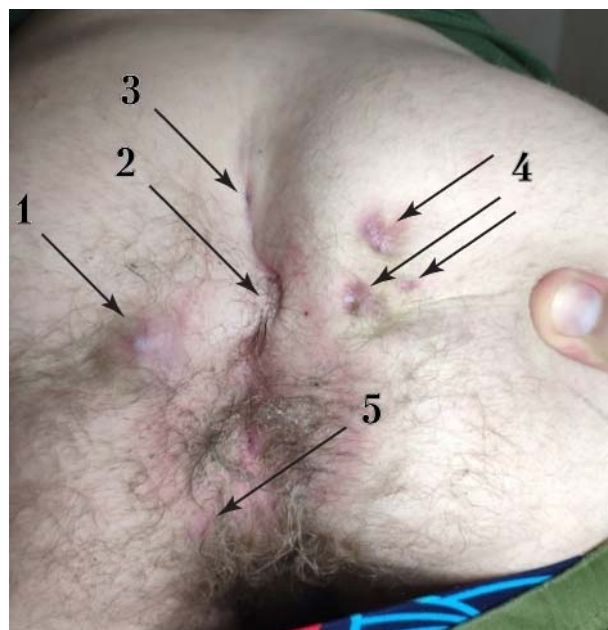


Figure 2. **Polymorphism of sacrococcygeal and perianal area lesions:** 1 — pararectal fistula; 2 — lateralized (secondary) pilonidal fistula opening within the intergluteal cleft; 3 — medial (primary) pilonidal fistula; 4 — lateralized (3) (secondary) pilonidal fistulas outside the intergluteal cleft; 5 — perianal furuncle

history data (onset of the relevant complaints, presence of swelling in the past history that ended with self-drainage, and presence of surgical interventions associated with PD) (Fig. 1).

### Stage 2

**Task** | Carry out a differential diagnosis of PD

**Steps** | Assess the probability of having:

- dermoid cyst;
- pyoderma;
- pararectal fistula or abscess.

*Commentary:* If the patient has specific complaints that do not fit the typical clinical picture, consider other diseases whose clinical and morphological manifestations can mimic PD (Fig. 2).

### Stage 3

**Task** | Clearly establish anatomical landmarks for the subsequent diagnostic procedure

**Steps** | Determine the following anatomical structures and their boundaries:

- intergluteal cleft;
- lateral lines of the intergluteal cleft;
- posterior median line;
- anal triangle;
- bone landmarks (top of the coccyx, sacrococcygeal joint, outer surface of the sacrum).

*Commentary:* The intergluteal cleft (in this algorithm, the «navicular area» concept [15]) is an anatomical

area that extends downwards from the sacrum a few centimetres above the sacrococcygeal joint. It is bounded laterally by the intergluteal cleft on the sides and by the upper edge of the anal canal below. The lateral line of the intergluteal cleft is the line of the medial surface of the buttock, which, when the patient is in a standing position, contacts the surface of the contralateral buttock above the anal canal. The posterior median line is the arbitrary line that passes in the sagittal plane and divides the back part of the body into left and right sides. The anal triangle is an imaginary anatomical area formed by the coccyx, the sacrotuberous ligaments, and the arbitrary line between the ischial tuberosities. The anal triangle contains the anal canal and two ischio-anal fossae, which lie on both sides of the anal canal and are filled with subcutaneous adipose tissue [11] (Fig. 3–5).

### Stage 4

**Task** | Examine the patient in a standing position

**Steps** | Examine the perineal area (determine the presence of medial or lateralized fistula openings, swellings, pronounced cellulite, or scars)

*Commentary:* Medial (primary) fistula openings are defects of the skin in the form of an opening, located along the posterior midline within the intergluteal cleft. Lateral (secondary) fistula openings are defects of the skin in the form of an opening, located laterally to the posterior midline within the

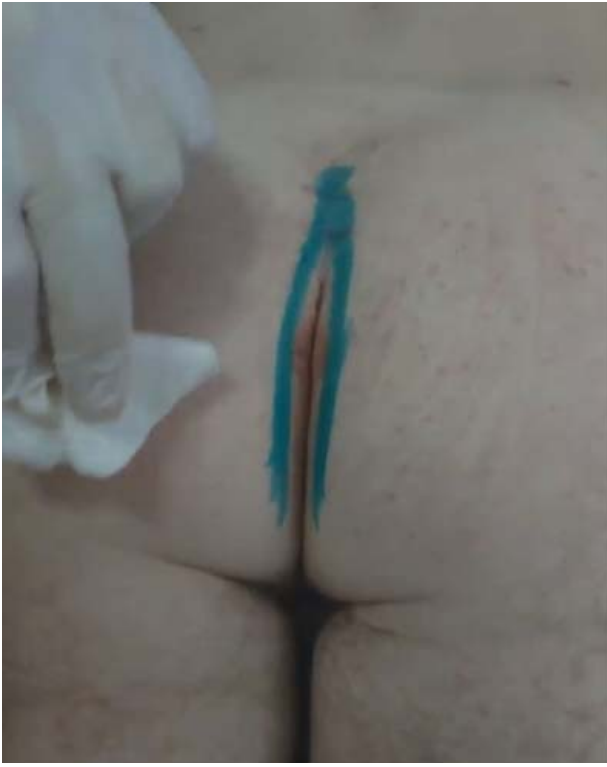

Figure 3. **Marking of the lateral line of the intergluteal cleft using a dye**

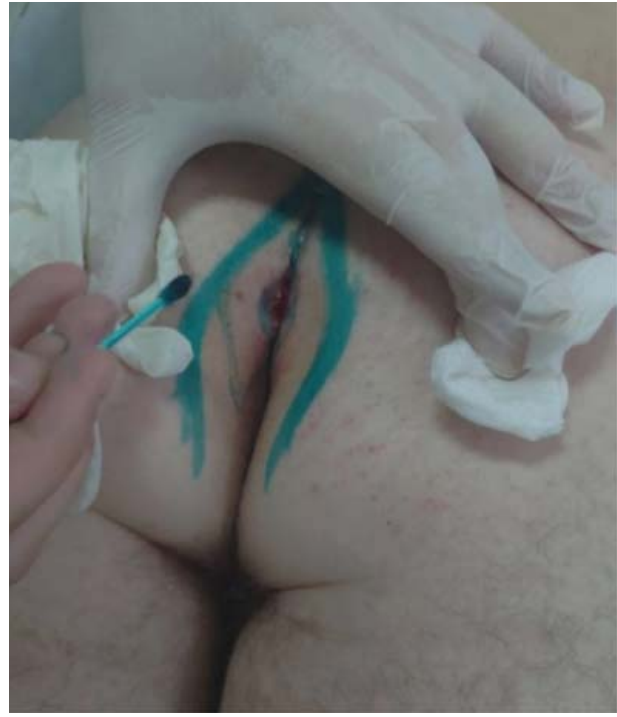

Figure 4. **Marking of the lateral line of the intergluteal cleft using a dye, multidirectional traction of the buttocks, partial visualization of the intergluteal cleft «navicular area»**

intergluteal cleft or outside it (Fig. 6).

### Stage 5

**Task** | Examine the sacrococcygeal area of the patient in Bozeman's position (knee-elbow position)

**Steps** | After explaining the specifics of the procedure, place the patient in a position that increases lumbar-kyphotic bending and assess.

**Factor 1** the intergluteal depth;

**Factor 2** hair growth in the corresponding area;

**Factor 3** the presence of white spots with signs of minimal inflammation at the bottom of the intergluteal cleft;

**Factor 4** the presence of fistulas along the posterior midline at the bottom of the intergluteal cleft, and determine their characteristics (size, presence of hair shafts, distance to the anal canal);

**Factor 5** the presence of infiltrates, hyperemia, local hyperthermia, pain, fluctuation;

**Factor 6** the presence of lateral (secondary) fistula canals within the intergluteal cleft, establish their nature (size, presence of hair shafts, distance from the intergluteal fold, presence/absence of secretions, presence/absence of signs of inflammation, ipsilateral/bilateral spread);

**Factor 7** the presence of lateral (secondary) fistula passages outside the intergluteal cleft, and

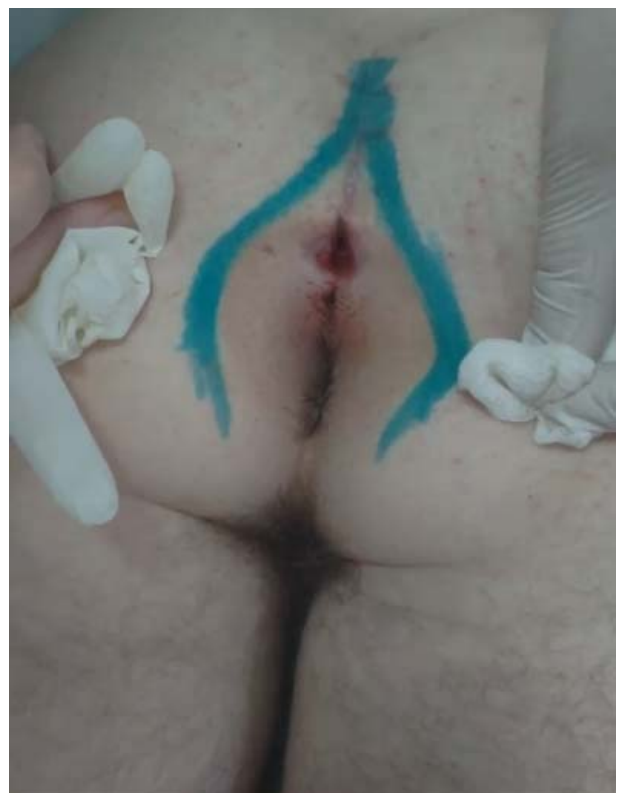

Figure 5. **Marking of the lateral line of the intergluteal cleft using a dye, multidirectional traction of the buttocks, complete visualization of the intergluteal cleft «navicular area»**



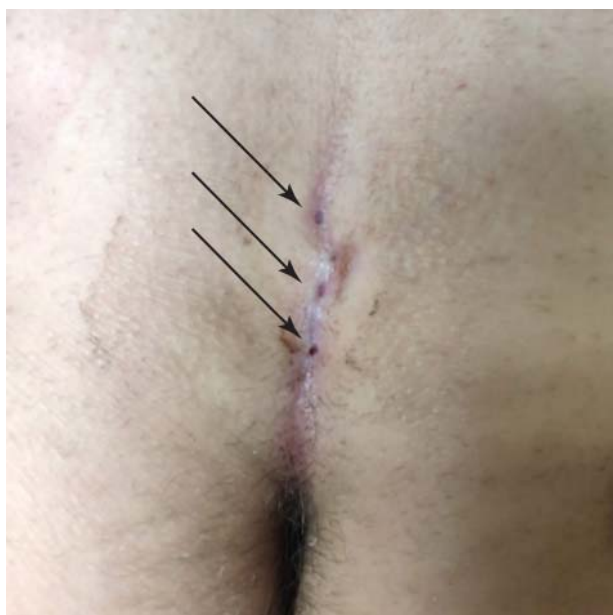

Figure 6. **Primary (medial) pilonidal fistula openings (indicated by arrows)**

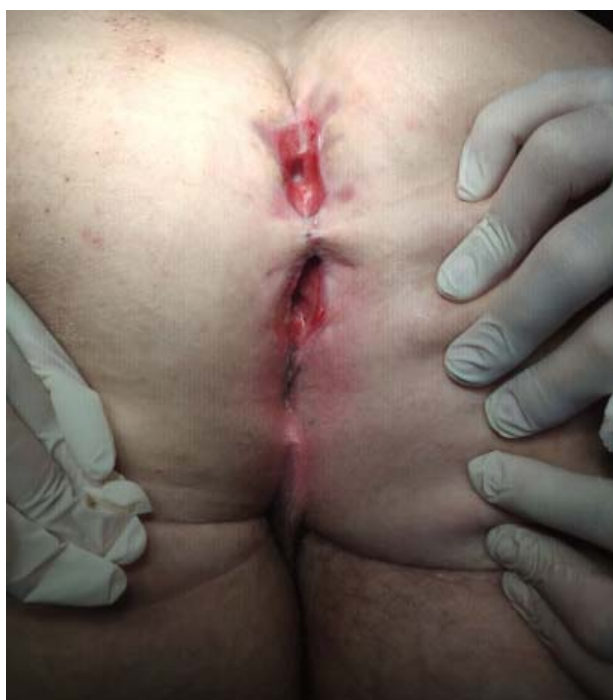

Figure 7. **Recurrent pilonidal cysts in the form of weakly granulating wounds. The lower wound has a transition to the upper edge of the anal canal involving the sphincter apparatus of the anus**

determine their nature (size, presence of hair shafts, distance from the intergluteal cleft, presence/absence of secretions, presence/absence of signs of inflammation, ipsilateral/bilateral spread;

**Factor 8** the presence of scars, postoperative scars, deformations, and determine their nature:

size, direction, shape (linear, herringbone, irregular).

*Commentary:* Before conducting the patient's examination in Bozeman's position, the specifics of the examination and the possible physical and moral discomfort should be explained to the patient (Fig. 7).

### Stage 6

**Task** | Examine the perianal area (anal triangle) of the patient in Bozeman's position (knee-elbow position)

**Steps** | After explaining the specifics of the procedure, place the patient in a position that increases lumbar-kyphotic bending and assess.

**Factor 1** the presence of fistula passages within the anal triangle, establish their nature (size, presence of hair shafts, distance from the intergluteal cleft, distance to the anal edge, presence of subcutaneous cords, presence/absence of secretions, presence/absence of signs of inflammation, ipsilateral/bilateral spread;

**Factor 2** the presence of secretions from the anal canal at rest and during palpation of fistula passages or swellings located nearby (provided they are present).

*Commentary:* This stage is extremely important to differentiate PD from rectal diseases. In addition to the visual assessment of fistula passages, local palpation is extremely important to establish the presence of subcutaneous cords (fistula passages) that may lead to the anal canal or the intergluteal cleft.

### Stage 7

**Task** | Conduct a digital rectal examination of the patient in Bozeman's position (knee-elbow position)

**Steps** | After explaining the specifics of the procedure, place the patient in a position that increases lumbar-kyphotic bending and assess.

**Factor 1** presence of tone of the anal sphincter apparatus and volitional effort;

**Factor 2** the presence of pain when performing a digital examination of the anal canal;

**Factor 3** the presence of swellings in the anal canal;

**Factor 4** the presence of cicatricial changes in the area of the front or back crypt (6 or 12 hours of the imaginary clock face);

**Factor 5** the nature of secretions from the anal canal if they are present.

*Commentary:* Before conducting a digital rectal examination, the specifics of the examination and the possible physical and moral discomfort should be explained to the patient. This stage is aimed at excluding the presence of pathology related to the

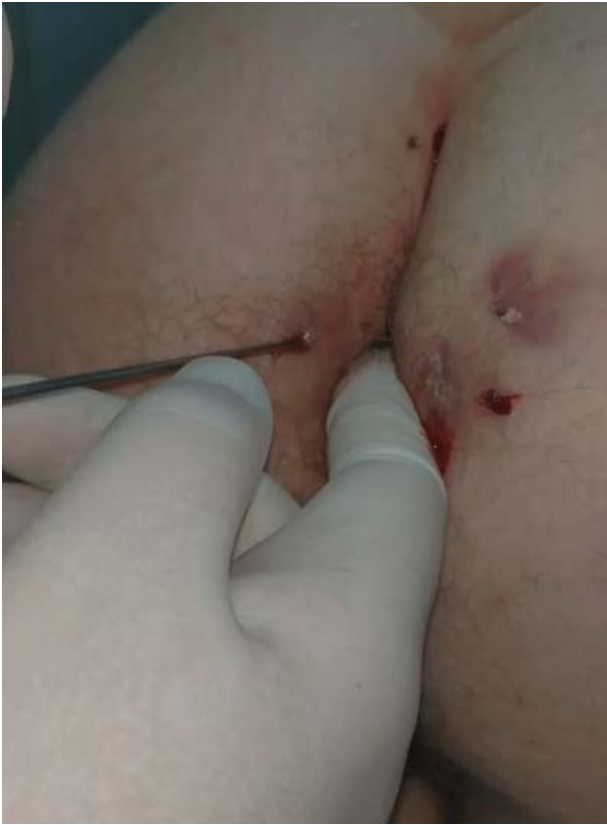

Figure 8. **Probing of the secondary pilonidal canal**

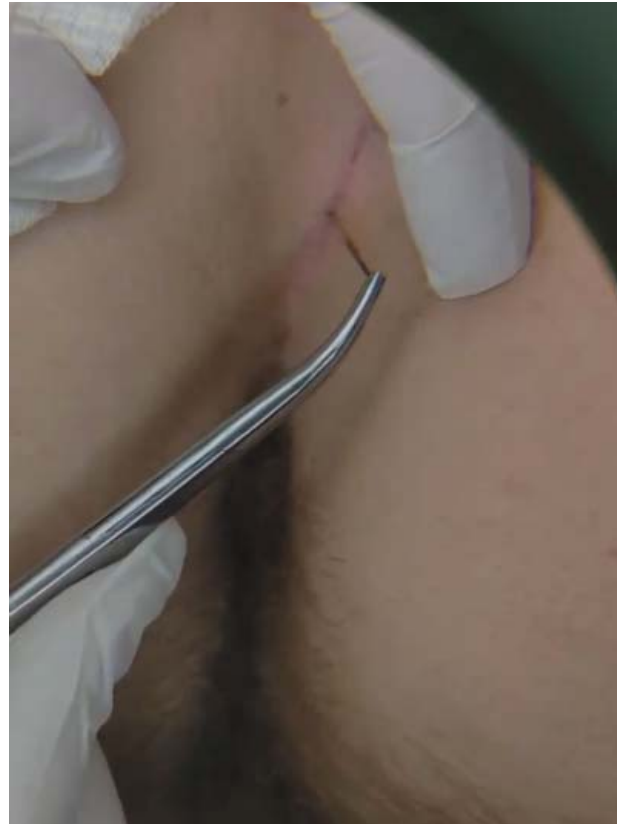

Figure 9. **Hair extraction from the pilonidal canal**

anal canal or more distal parts of the rectum, first of all, perianal fistulas or abscesses.

### Stage 8

**Task** | Conduct inspection and probing of fistula passages (provided they are present)

**Steps** | · Inspect all fistula openings with a safe probe – assess the presence of fistula passages, their length, direction, connection with other fistula openings or the anal canal.  
· Inspect with Mosquito forceps if there is hair in the fistula opening with an assessment of the type of hair and its amount

*Commentary:* Probing of the fistula passages is performed with a sterile atraumatic probe or a large-diameter elastic catheter. An important aspect of the examination is the avoidance of forceful probing (overcoming tissue resistance by force), which can lead to the formation of false passages or connections. If there is a pronounced pain syndrome, local anaesthesia can be used (Fig. 8–10).

### Stage 9

**Task** | Carry out staining of fistula passages (provided they are present)

**Steps** | Inject a small amount of a dye under pressure into the fistula opening with a syringe

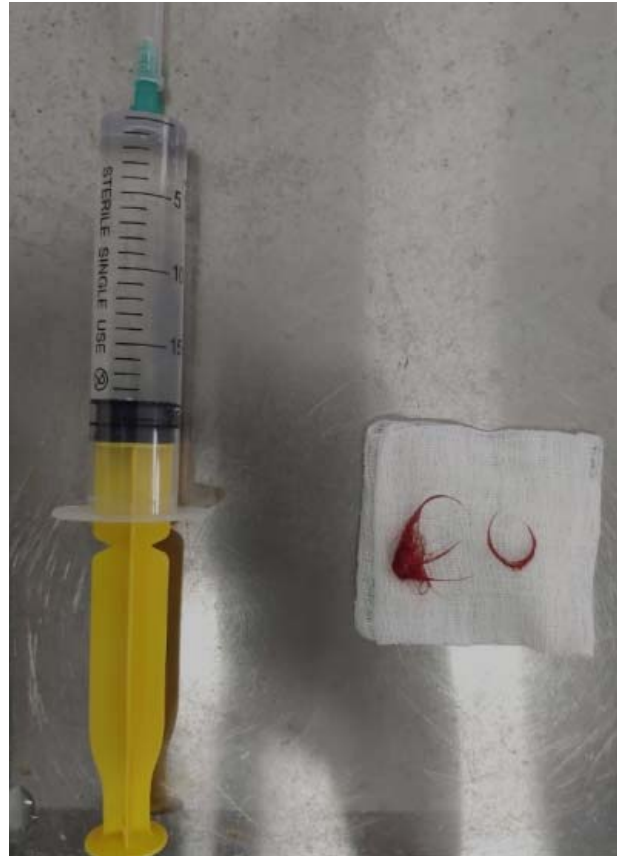

Figure 10. **Extracted hair from the pilonidal canal**

or catheter, and monitor the release of the dye from the primary fistula openings or the anal canal.

**Commentary:** the introduction of a dye into the fistula opening should be carried out taking into account the possible excessive staining of the surface under investigation. To avoid the aforementioned problem, a minimal amount of dye is used and tightness is ensured when it is introduced into the fistula opening.

## Conclusions

Sacrococcygeal pilonidal disease is a common condition that requires timely diagnosis and further management. In resource-limited settings, the creation of diagnostic algorithms is one of the important ways to improve access to health services. In order to enhance the efficiency of the proposed algorithms, the «task-step-commentary» principle is applied. This principle provides the healthcare professional with clear instructions regarding the sequence of diagnostic procedures and their clinical interpretation.

## DECLARATION OF INTERESTS

The authors declare that they have no conflicts of interest, including financial, personal, authorship, or others, that could affect the research and its results presented in this article.

**Funding.** The study was conducted without any financial support.

## AUTHORS CONTRIBUTIONS

D. Dubenko, Y. Susak: research concept and design;  
D. Dubenko: collection and processing of the materials,  
writing the manuscript.

## REFERENCES

1. Abdelatty MA, Elmansy N, Saleh MM, Salem A, Ahmed S, Gadalla AA, Osman MF, Mohamed S. Magnetic resonance imaging of pilonidal sinus disease: interobserver agreement and practical MRI reporting tips. *Eur Radiol.* 2024 Jan;34(1):115-125. doi: 10.1007/s00330-023-10018-2. Epub 2023 Aug 11. PMID: 37566273; PMCID: PMC10791724.
2. Beets-Tan RG, Beets GL, van der Hoop AG, Kessels AG, Vliegen RF, Baeten CG, van Engelshoven JM. Preoperative MR imaging of anal fistulas: Does it really help the surgeon? *Radiology.* 2001 Jan;218(1):75-84. doi: 10.1148/radiology.218.1.r01dc0575. PMID: 11152782.
3. Buchanan G, Halligan S, Williams A, Cohen CR, Tarroni D, Phillips RK, Bartram CI. Effect of MRI on clinical outcome of recurrent fistula-in-ano. *Lancet.* 2002 Nov 23;360(9346):1661-2. doi: 10.1016/S0140-6736(02)11605-9. PMID: 12457791.
4. Chintapatla S, Safarani N, Kumar S, Haboubi N. Sacrococcygeal pilonidal sinus: historical review, pathological insight and surgical options. *Tech Coloproctol.* 2003 Apr;7(1):3-8. doi: 10.1007/s101510300001. PMID: 12750948.
5. Dzhus M, Golovach I. Impact of Ukrainian- Russian War on Health Care and Humanitarian Crisis. *Disaster Med Public Health Prep.* 2022 Dec 7;17:e340. doi: 10.1017/dmp.2022.265. PMID: 36474326.
6. Halligan S, Tolan D, Amitai MM, Hoeffel C, Kim SH, Maccioni F, Morrin MM, Mortele KJ, Rafafelsen SR, Rimola J, Schmidt S, Stoker J, Yang J. ESGAR consensus statement on the imaging of fistula-in-ano and other causes of anal sepsis. *Eur Radiol.* 2020 Sep;30(9):4734-4740. doi: 10.1007/s00330-020-06826-5. Epub 2020 Apr 19. PMID: 32307564; PMCID: PMC7431441.
7. Isik A, Idiz O, Firat D. Novel Approaches in Pilonidal Sinus Treatment. *Prague Med Rep.* 2016;117(4):145-152. doi: 10.14712/23362936.2016.15. PMID: 27930892.
8. Johnson EK, Vogel JD, Cowan ML, Feingold DL, Steele SR; Clinical Practice Guidelines Committee of the American Society of Colon and Rectal Surgeons. The American Society of Colon and Rectal Surgeons' Clinical Practice Guidelines for the Management of Pilonidal Disease. *Dis Colon Rectum.* 2019 Feb;62(2):146-157. doi: 10.1097/DCR.0000000000001237. PMID: 30640830.
9. McCallum IJ, King PM, Bruce J. Healing by primary closure versus open healing after surgery for pilonidal sinus: systematic review and meta-analysis. *BMJ.* 2008 Apr 19;336(7649):868-71. doi: 10.1136/bmj.39517.808160.BE. Epub 2008 Apr 7. PMID: 18390914; PMCID: PMC2323096.
10. Menten O, Oysul A, Harlak A, Zeybek N, Kozak O, Tufan T. Ultrasonography accurately evaluates the dimension and shape of the pilonidal sinus. *Clinics (Sao Paulo).* 2009;64(3):189-92. doi: 10.1590/s1807-59322009000300007. PMID: 19330243; PMCID: PMC2666454.
11. Nauman K, Samra NS. Anatomy, Abdomen and Pelvis: Anal Triangle. 2023 Jul 24. In: StatPearls [Internet]. Treasure Island (FL): StatPearls Publishing; 2024 Jan-. PMID: 32491517. <https://www.ncbi.nlm.nih.gov/books/NBK557585/>.
12. Seow-Choen F, Seow-En I. Pilonidal disease: A new look at an old disease. *Seminars in Colon and Rectal Surgery.* 2022;33(4):100909. <https://doi.org/10.1016/J.SCRS.2022.100909>.
13. Søndenaa K, Andersen E, Nesvik I, Søreide JA. Patient characteristics and symptoms in chronic pilonidal sinus disease. *Int J Colorectal Dis.* 1995;10(1):39-42. doi: 10.1007/BF00337585. PMID: 7745322.
14. Steele SR, Hull TL, Hyman N, Maykel JA, Read TE and Whitlow CB (Editors). *The ASCRS Textbook of Colon and Rectal Surgery*, 4th edition. Springer Nature Switzerland AG. 2022. Available from: [https://www.ascrsu.com/ascrs/view/ASCRS-Textbook-of-Colon-and-Rectal-Surgery/2285000/all/About\\_ASCRS\\_Textbook\\_of\\_Colon\\_and\\_Rectal\\_Surgery](https://www.ascrsu.com/ascrs/view/ASCRS-Textbook-of-Colon-and-Rectal-Surgery/2285000/all/About_ASCRS_Textbook_of_Colon_and_Rectal_Surgery).
15. Tezel, E. (2007). A new classification according to navicular area concept for sacrococcygeal pilonidal disease. *Colorectal Disease : The Official Journal of the Association of Coloproctology of Great Britain and Ireland*, 9(6), 575-576. <https://doi.org/10.1111/j.1463-1318.2007.01236.x>

# Алгоритм діагностики пілонідальної хвороби крижово-куприкової ділянки в умовах роботи з обмеженими медичними ресурсами

Д. Дубенко, Я. Сусак

Національний медичний університет імені О. О. Богомольця, Київ

Пілонідальна хвороба (ПХ) є дуже поширеним захворюванням. У країнах з високим рівнем доходу на одиницю населення та широким доступом до надання медичної допомоги середньожиттєва захворюваність становить близько 26 випадків на 100 тис. населення. В США щорічно реєструється близько 70 тис. нових випадків захворювання. На тлі повномасштабної агресії російської федерації з лютого 2022 року доступ до висококваліфікованої медичної допомоги значно знизився для населення України, особливо для осіб, що опинились на тимчасово окупованих територіях, в громадах, які зазнали значних руйнувань, для внутрішньо переміщених осіб. Наявність пілонідальної хвороби призводить до різкого зниження працездатності та якості життя, в окремих випадках — до розвитку серйозних ускладнень, що становлять безпосередню загрозу для життя.

**Мета** — розробити стандартизований алгоритм діагностики ПХ крижово-куприкової ділянки для використання в умовах обмежених медичних ресурсів (зона бойових дій, території, розташовані в безпосередній близькості до театру бойових дій, населення яких не має повноцінного доступу до спеціалізованої медичної допомоги; деокуповані території, які тимчасово позбавлені доступу до повноцінного медичного людського потенціалу та відповідного технічного ресурсу).

Розроблено стандартизований алгоритм діагностики ПХ, що містить 9 етапів, розділених на послідовні блоки. Кожен етап оформлений згідно з концепцією «завдання-крок-коментар» і містить деталізовані пояснення для виконання діагностичного процесу.

**Висновки.** Пілонідальна хвороба крижово-куприкової ділянки потребує своєчасної діагностики та надання пацієнту медичної допомоги. В умовах обмеженості медичних ресурсів створення діагностичних алгоритмів — важливий допоміжний інструмент для збільшення доступності медичної допомоги населенню.

**Ключові слова:** пілонідальна хвороба, пілонідальний абсцес, рани, що в'яло гранулюють, діагностика, алгоритм, обмежені ресурси.

## FOR CITATION

■ Dubenko D, Susak Y. An algorithm for the diagnosis of sacrococcygeal pilonidal disease in resource-limited settings. General Surgery (Ukraine). 2023;3-4:79-95. <http://doi.org/10.30978/GS-2023-3-79>.