

UDC616.211-071
<https://doi.org/10.31612/2616-4868.2.2024.06>

INDICATORS OF MUC 5AC AND MUC 1 MUCOPOLYSACCHARIDE EXPRESSION IN THE NASAL MUCOSA OF PATIENTS WITH POSTNASAL DRIP SYNDROME AND NASAL SEPTUM DEVIATION

Nataliia V. Babchenko, Yulia V Dieieva, Serhii E. Konovalov, Oleksii V. Motailo

Bogomolets National Medical University, Kyiv, Ukraine

Summary

Introduction. Determining the cause of postnasal drip syndrome can be quite challenging. Nasal septum deformation has been recognized as one possible factor. Understanding the fundamental processes of postnasal drip syndrome is crucial for developing targeted therapeutic strategies for treating this pathology. In our study, we examined the clinical and histological features of postnasal drip syndrome in individuals with nasal septum deformation and investigated the expression of mucopolysaccharides, specifically the indicators of MUC 5AC and MUC 1.

The aim. This study aims to investigate the clinical and histological aspects of postnasal drip syndrome (PNDS) in patients with nasal septum deformation. Specifically, the study aims to explore the expression levels of MUC5AC and MUC1 in biopsies of the nasal turbinate mucosa.

Materials and methods. A total of 29 samples of nasal mucosa from the lower nasal turbinates were collected. These samples were divided into two groups: patients with nasal septum deviation with and without postnasal drip syndrome. Levels of MUC5AC and MUC1 were determined using Western blot analysis.

Results. Upon analysis of histological sections, we identified a significant increase in tissue metaplasia and lymphoid infiltration in the nasal mucosa of patients with postnasal drip syndrome compared to the control group. The levels of mucopolysaccharides, MUC5AC and MUC1, were higher in the nasal mucosa of the research group compared to the control group.

Conclusions. The obtained data suggest that anatomical changes in the nasal cavity may play a role in the development of postnasal drip syndrome through alterations in mucin secretion.

Keywords: nasal septum deviation, postnasal drip syndrome, histology, MUC5AC, MUC1, nasal cavity

INTRODUCTION

Postnasal Drip Syndrome (PNDS) is a condition characterized by an excessive amount of mucus dripping down the back of the throat, leading to symptoms such as cough, throat discomfort, and a sensation of a foreign body. It can significantly impact the quality of life [1, 2]. Although the cause of PNDS is often unknown, nasal septum deformation has been recognized as a potential contributing factor [3]. Deformation of the nasal septum, which divides the nasal cavity into two parts, can obstruct normal airflow in the nose and disrupt mucociliary clearance function, potentially leading to the accumulation of nasal secretions and the development of PNDS [4, 5]. Understanding the underlying processes of PNDS caused

by nasal septum deformation is essential for developing targeted therapeutic strategies for this condition.

Indicators such as MUC5AC and MUC1 have been described in the pathophysiology of various nasal conditions, including chronic rhinosinusitis [6]. MUC5AC and MUC1 are components of respiratory mucous secretion, and their overexpression is associated with excessive mucus production in various respiratory tract disorders [7, 8, 9, 10].

Despite the potential significance for treating conditions of the nasal cavity and paranasal sinuses, the role of these molecular markers in the development of Postnasal Drip Syndrome (PNDS) associated with nasal septum deformation remains largely unknown. Therefore,

this study aims to examine the clinical and histological features of PNDS in individuals with nasal septum deformation, with a particular focus on the expression of mucopolysaccharides, specifically the indicators of MUC 5AC and MUC 1. The results of this study may have a significant impact on clinical practice by improving the diagnosis, treatment, and therapeutic outcomes for individuals with PNDS related to nasal septum deviation.

THE AIM OF THE STUDY

This study aims to investigate the clinical and histological aspects of postnasal drip syndrome (PNDS) in patients with nasal septum deformation. Specifically, the study aims to explore the expression levels of MUC5AC and MUC1 in biopsies of the nasal turbinate mucosa.

MATERIALS AND METHODS

The study included two groups:

1. Research Group (RG): This group comprised 17 samples of nasal mucosa from the lower nasal turbinates, taken from patients with Postnasal Drip Syndrome (PNDS) and nasal septum deviation.

2. Healthy Control Group (CG): consisting of 12 samples of nasal mucosa from the lower nasal turbinates, taken from individuals with nasal septum deviation who did not have PNDS.

Exclusion criteria from the study were as follows: patients with upper respiratory tract infections or sinusitis in the past 2 months, patients with a clinical diagnosis of

allergic rhinitis, patients with vasomotor rhinitis, patients with a history of endonasal interventions, patients using nasal steroids or sprays, and patients with any other nasal disorders.

For histological analysis during septoplasty, samples of nasal mucosa from the lower nasal turbinates were obtained from areas located at the level of the most deviated part of the nasal septum, with a size ≤ 0.05 cm². The samples were fixed in 4 % buffered formaldehyde solution (24 hours, 4 °C) and then embedded in paraffin. Histological sections with a thickness of 4 μ m were stained with hematoxylin and eosin, Alcian blue at pH 2.5, and subjected to immunohistochemical reactions.

Specimens were examined under a light microscope at 40x magnification. The density of lymphocytic infiltration was assessed and classified as follows:

- Grade 0: Absence of lymphocytes.
- Grade 1: 1-2 lymphocytes per field.
- Grade 2: Scattered individual lymphocytes in all areas.
- Grade 3: Diffuse and intense lymphocytic infiltration.

RESULTS

All 29 patients included in this study exhibited nasal septum deviation, either to the left or to the right. Analyzing the results of histological sections, we found a statistically significant difference in the presence of squamous metaplasia in the mucosa of the septum in patients with Postnasal Drip Syndrome (PNDS) compared to the control group ($p=0.001$) (table 1).

Table 1

Squamous Metaplasia of the Nasal Mucosa

	Squamous Metaplasia
The mucosa of patients with both Postnasal Drip Syndrome (PNDS) and nasal septum deviation.	16
The mucosa of patients with nasal septum deviation	8

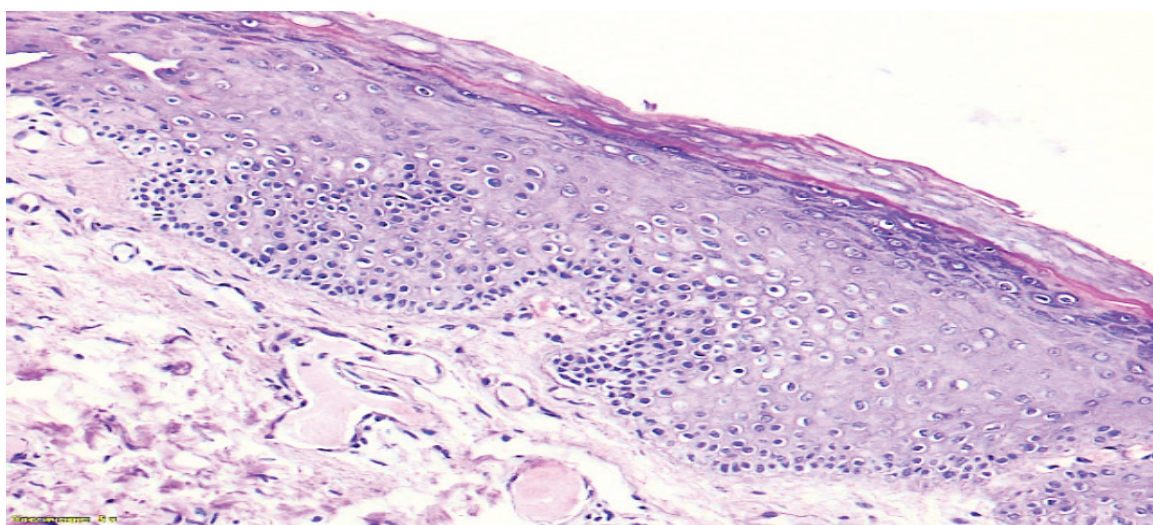


Figure 1. Microscopic image of the nasal mucosa. Squamous metaplasia and dense lymphocytic infiltration

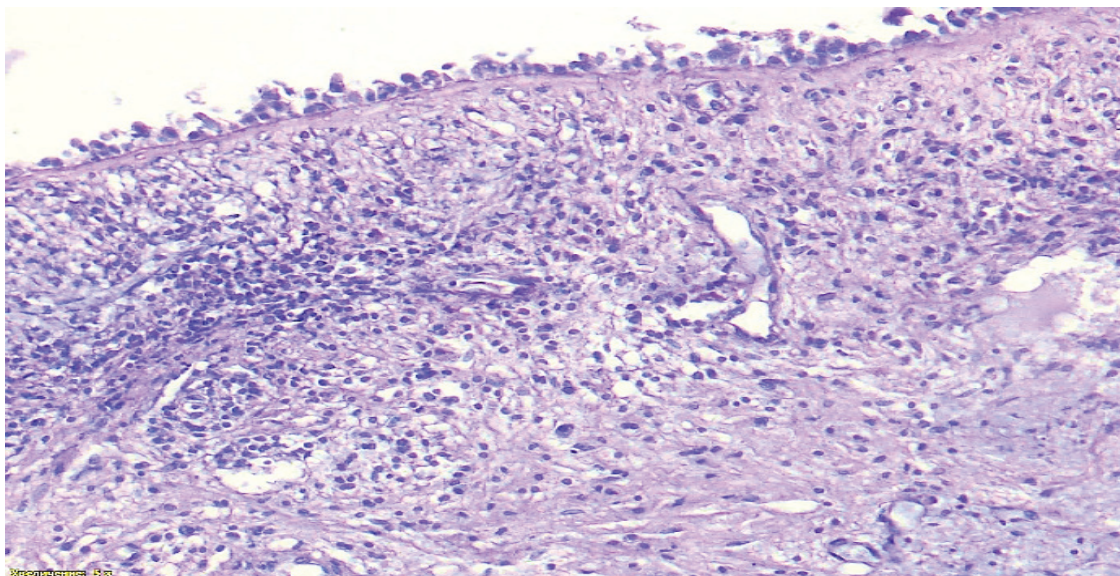


Figure 2. Microscopic image of the nasal mucosa. Lymphocytic infiltration in the epithelium

The intensity of lymphocytic infiltration in the nasal mucosa of patients with Postnasal Drip Syndrome (PNDS) was higher than in the control group, and the difference between them was statistically significant ($p < 0.001$).

Table 2

Lymphocytic infiltration of the nasal mucosa

	Lymphocytic Infiltration			
	Grade 0	Grade 1	Grade 2	Grade 3
The mucosa of patients with Postnasal Drip Syndrome (PNDS) and nasal septum deviation.	0	4	9	4
The mucosa of patients with nasal septum deviation.	2	5	4	1

We compared the levels of MUC 5AC and MUC 1 in the nasal mucosa. The levels of mucopolysaccharides MUC5AC and MUC1 were measured in the nasal mucosa of both groups using Western Blot analysis. Figure 1 presents the results of Western Blot analysis comparing the research group and the control group for the level of MUC5AC in the nasal mucosa.

The analysis showed that the levels of mucopolysaccharides MUC5AC were significantly higher in the research group compared to the control group. In the research group, the average concentration of MUC5AC was 8.27 ± 1.25 , and the optical density was at the level of 6536506.56, compared to the control group where these indicators were 2.92 ± 2.34 and 2060678.25.

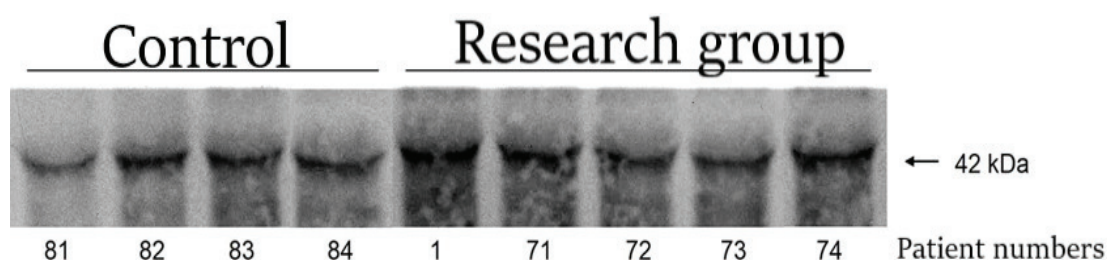


Figure 3. Western blot analysis comparing the research group and the control group for levels of mucopolysaccharides MUC5AC in the nasal mucosa

When analyzing the Western blot results of MUC1 indicators (fig. 2) in the nasal mucosa, we also observed a significant increase in the concentration of the protein component in the research group of patients compared to the control group, which were 5.60 ± 0.9 and 3.55 ± 0.75 , respectively. The optical density in the research group was 3943906.53, and in the control group, it was 2785502.29.

The elevated levels of mucopolysaccharides MUC5AC and MUC1 in the nasal mucosa of the research group indicate their potential role in the pathogenesis of postnasal drip syndrome. These results may suggest a possible association between increased mucopolysaccharide levels and clinical manifestations observed in patients with postnasal drip syndrome and nasal septum deviation.

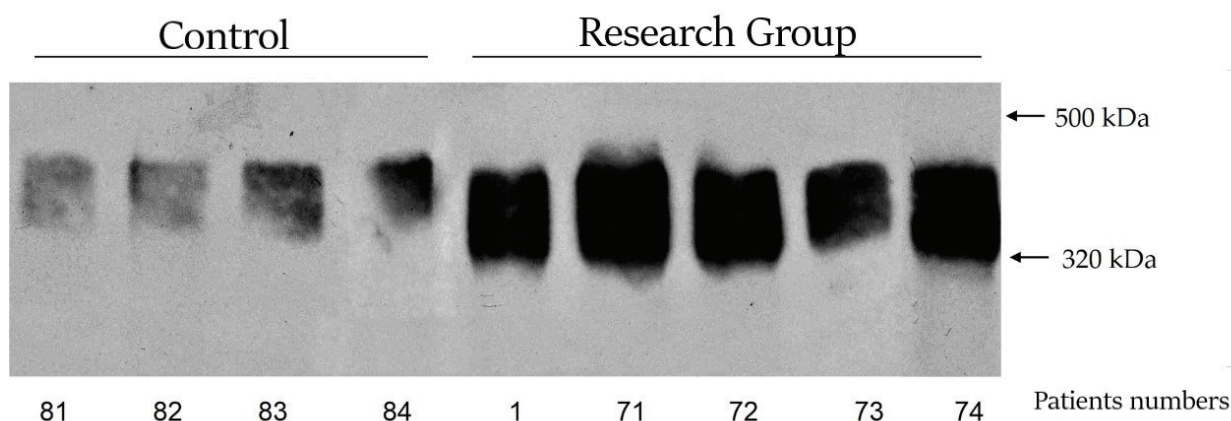


Figure 4. Western blot analysis comparing the research group and the control group regarding the levels of MUC1 in the nasal mucosa

DISCUSSION

According to our data, patients with nasal septum deviation and postnasal drip syndrome have higher levels of mucopolysaccharides MUC5AC and MUC1 secreted by the nasal mucosa than the control group. This may indicate a connection between the development of postnasal drip syndrome and structural changes in the nasal cavity. There is a hypothesis that postnasal drip syndrome is caused by several factors, including increased mucus production, impaired mucociliary clearance function, and inflammation of the respiratory epithelium [11, 12]. The specific etiology of the condition is not yet fully known. Glycoproteins known as mucins, present in the mucus layer covering the respiratory epithelium, are necessary to maintain hydration and barrier function of the respiratory tract. Secretion and disruption of mucin production are associated with reduced mucociliary clearance, inflammation, and tissue remodeling, as observed in our histological sections during our study, which, in turn, can lead to respiratory disorders. MUC5AC, the major gel-forming mucin, is primarily produced by goblet cells in the respiratory epithelium, while MUC1 is a transmembrane mucin expressed on the surface of epithelial cells [13, 14]. Patients with respiratory disorders such as chronic rhinosinusitis and asthma have higher levels of MUC5AC and MUC1 in the nasal mucosa [15, 16]. According to the study's conclusions, modifications in the production and secretion of mucins may be a contributing factor to the development of posterior nasal drip (PND) through structural changes in the nasal mucosa. Alteration in the shape of the nasal septum can impact airflow patterns in the nasal cavity, leading to increased mucus production and swelling of the lower nasal turbinates. This may complicate the removal of mucus from the nasal cavity, contributing to the development of PND. The use of Western Blot analysis in this study to identify target markers may have

limitations in sensitivity and specificity compared to alternative methods such as immunohistochemistry or quantitative PCR. Further research is needed to confirm these findings and elucidate the underlying mechanisms involved in the development of PND in patients with nasal septal deviation.

CONCLUSIONS

Analyzing the results of our study, it can be concluded that nasal septal deviation leads to histological changes in the nasal mucosa, manifested as lymphocytic infiltration and squamous metaplasia. These changes were observed in patients from both study groups, but they were found to be more severe in the study group compared to the control. Nasal septal deviation stimulates chronic inflammation and squamous metaplasia of the nasal mucosa, both of which may contribute to impaired mucociliary clearance and mucus production, as confirmed in our study by Western Blot analysis. The obtained data suggest that architectural changes in the nasal cavity may play a role in the development of posterior nasal drip (PND) through alterations in mucus production and disruption of its secretion, involving key protein components. Further research is needed to confirm these conclusions and provide insights into the underlying mechanisms contributing to the development of PND.

The prospects of future research. In the future, we plan to investigate the condition of the nasal cavity in patients with posterior nasal drip (PND) and nasal septal deviation clinically, using endoscopic examination and analyzing computed tomography results to compare the anatomical structures of the nose and paranasal sinuses.

We anticipate that this research will provide us with more comprehensive information about the nasal mucosa's condition in posterior nasal drip (PND) and

help compare different clinical groups based on the forms of nasal septal deviation.

FUNDING AND CONFLICT OF INTEREST

The authors declare no conflict of interest regarding this article. The article is self-funded.

COMPLIANCE WITH ETHICAL REQUIREMENTS

The study was conducted by the principles of the World Medical Association's Declaration of Helsinki «Ethical Principles for Medical Research Involving Human Subjects». All study participants provided informed consent in writing to participate in the study.

REFERENCES

- Ryan M.W. (2010). The patient with «postnasal drip.» *Med Clin North Am.* Sep [cited 2023 May 23], 94(5), 913-21. Available from: <https://pubmed.ncbi.nlm.nih.gov/20736103/>
- Morice A.H. (2004). Post-nasal drip syndrome – a symptom to be sniffed at? *Pulm Pharmacol Ther.*, 17(6), 343-5. Available from: <https://pubmed.ncbi.nlm.nih.gov/15564073/>
- Mariño-Sánchez F., Valls-Mateus M., Cardenas-Escalante P., Haag O., Ruiz-Echevarría K., Jiménez-Feijoo R., et al. (2017). Influence of nasal septum deformity on nasal obstruction, disease severity, and medical treatment response among children and adolescents with persistent allergic rhinitis. *Int J Pediatr Otorhinolaryngol.* Apr 1, 95, 145-54. Available from: <https://pubmed.ncbi.nlm.nih.gov/28576524/>
- Sam A., Deshmukh P. T., Patil C., Jain S., Patil R. (2012). Nasal Septal Deviation and External Nasal Deformity: A Correlative Study of 100 Cases. *Indian Journal of Otolaryngology and Head & Neck Surgery.* Dec, 64(4), 312. Available from: [/pmc/articles/PMC3477430/](https://pubmed.ncbi.nlm.nih.gov/20450396/)
- Mladina R., Skitarelić N., Poje G., Šubarić M. (2015). Clinical Implications of Nasal Septal Deformities. *Balkan Med J.*, 32(2), 137. Available from: [/pmc/articles/PMC4432693/](https://pubmed.ncbi.nlm.nih.gov/17850213/)
- Kim M.H., Bae C. H., Choi Y. S., Na H. G., Song S. Y., Kim Y. D. (2019). Endoplasmic Reticulum Stress Induces MUC5AC and MUC5B Expression in Human Nasal Airway Epithelial Cells. *Clin Exp Otorhinolaryngol.* May 1,12(2),181. Available from: [/pmc/articles/PMC6453786/](https://pubmed.ncbi.nlm.nih.gov/20450396/)
- Sano R., Reed J. C. (2013). ER stress-induced cell death mechanisms. *Biochimica et Biophysica Acta (BBA) – Molecular Cell Research.* Dec 1, 1833(12), 3460-70.
- Almanza A., Carlesso A., Chintha C., Creedican S., Doultinos D., Leuzzi B., et al. (2019). Endoplasmic reticulum stress signalling – from basic mechanisms to clinical applications. *FEBS J.* Jan 1, 286(2), 241-78. Available from: <https://onlinelibrary.wiley.com/doi/full/10.1111/febs.14608>
- Bonser L.R., Erle D. J. (2017). Airway Mucus and Asthma: The Role of MUC5AC and MUC5B. *J Clin Med.* Dec 1, 6(12). Available from: [/pmc/articles/PMC5742801/](https://pubmed.ncbi.nlm.nih.gov/20450396/)
- Livraghi-Butrico A., Grubb B. R., Wilkinson K. J., Volmer A. S., Burns K. A., Evans C. M., et al. (2017). Contribution of mucus concentration and secreted mucins Muc5ac and Muc5b to the pathogenesis of muco-obstructive lung disease. *Mucosal Immunol.* Mar 1,10(2), 395-407.
- Mladina R., Skitarelić N., Casale M. (2010). Two holes syndrome (THS) is present in more than half of the postnasal drip patients? *Acta Otolaryngol.* Nov, 130(11), 1274-7. Available from: <https://pubmed.ncbi.nlm.nih.gov/20450396/>
- Voynow J.A., Mengr B. K.R. Mucins, Mucus, and Sputum. *Chest.* 2009 Feb 1,135(2),505-12.
- Thornton D.J., Rousseau K., McGuckin M. A. (2008). Structure and function of the polymeric mucins in airways mucus. *Annu Rev Physiol.*,70, 459-86. Available from: <https://pubmed.ncbi.nlm.nih.gov/17850213/>
- Williams O.W., Sharafkhaneh A., Kim V., Dickey B. F., Evans C. M. (2006). Airway Mucus: From Production to Secretion. *Am J Respir Cell Mol Biol.* May,34(5),527. Available from: [/pmc/articles/PMC2644218/](https://pubmed.ncbi.nlm.nih.gov/17850213/)
- Cohn L. (2006). Mucus in chronic airway diseases: sorting out the sticky details. *Journal of Clinical Investigation.* Feb 2,116(2), 306. Available from: [/pmc/articles/PMC1359062/](https://pubmed.ncbi.nlm.nih.gov/17850213/)
- Tong J., Gu Q. (2020). Expression and Clinical Significance of Mucin Gene in Chronic Rhinosinusitis. *Curr Allergy Asthma Rep.* Nov 1, 20(11), Available from: [/pmc/articles/PMC7434719/](https://pubmed.ncbi.nlm.nih.gov/17850213/)

Резюме

ПОКАЗНИКИ ЕКСПРЕСІЇ МУКОПОЛІСАХАРИДІВ MUC 5AC ТА MUC 1 В СЛИЗОВІЙ ОБОЛОНЦІ НОСОВОЇ ПОРОЖНИНИ У ПАЦІЄНТІВ З СИНДРОМОМ ПОСТНАЗАЛЬНОГО СТІКАННЯ ТА ВИКРИВЛЕННЯМ НОСОВОЇ ПЕРЕДІЛКИ

Наталія В. Бабченко, Юлія В. Дєєва, Сергій Е. Коновалов, Олексій В. Мотайло

Національний медичний університет імені О. О. Богомольця, м. Київ, Україна

Вступ. Визначити причину синдрому постназального стікання доволі важко. Одним з можливих факторів була визнана деформація носової перегородки. Розуміння основних процесів синдрому постназального стікання має вирішальне значення для створення цілеспрямованих терапевтичних стратегій в лікуванні даної патології. В нашому дослідженні ми розглянули клінічні та гістологічні особливості синдрому постназального стікання у осіб з деформацією носової перегородки, та дослідили експресії мукополісахаридів, а саме показників MUC 5AC та MUC 1.

Мета дослідження. Метою даного дослідження є вивчення клінічних та гістологічних аспектів СПС у пацієнтів з деформацією носової перегородки. Конкретною метою дослідження є пошук показників MUC 5AC та MUC 1 у біопсії слизової оболонки носових раковин.

Матеріали та методи. Всього було взято 29 зразків слизової оболонки з нижніх носових раковин. Ці зразки були розділені на дві групи: пацієнти, що мають викривлення носової перегородки без та з синдромом/ом постназального стікання. Рівні MUC5AC та MUC1 визначали за допомогою Вестерн-Блот-аналізу.

Результати. При аналізі гістологічних зрізів ми виявили достовірне підвищення тканинної метаплазії та лімфоїдної інфільтрації в слизовій оболонці пацієнтів з синдромом постназального стікання в порівнянні з контрольною групою. Рівень мукополісахаридів MUC5AC та MUC1 був вищим у слизовій оболонці носової порожнини у дослідницької групи порівняно з контрольною групою.

Висновки. Отримані дані свідчать про те, що анатомічні зміни в носовій порожнині можуть відігравати певну роль у розвитку синдрому постназального стікання через зміни в секретії муцинів.