

GEORGIAN MEDICAL NEWS

ISSN 1512-0112

№ 10 (295) Октябрь 2019

ТБИЛИСИ - NEW YORK



ЕЖЕМЕСЯЧНЫЙ НАУЧНЫЙ ЖУРНАЛ

Медицинские новости Грузии
საქართველოს სამედიცინო სიახლენი

GMN: Georgian Medical News is peer-reviewed, published monthly journal committed to promoting the science and art of medicine and the betterment of public health, published by the GMN Editorial Board and The International Academy of Sciences, Education, Industry and Arts (U.S.A.) since 1994. GMN carries original scientific articles on medicine, biology and pharmacy, which are of experimental, theoretical and practical character; publishes original research, reviews, commentaries, editorials, essays, medical news, and correspondence in English and Russian.

GMN is indexed in MEDLINE, SCOPUS, PubMed and VINITI Russian Academy of Sciences. The full text content is available through EBSCO databases.

GMN: Медицинские новости Грузии - ежемесячный рецензируемый научный журнал, издаётся Редакционной коллегией и Международной академией наук, образования, искусств и естествознания (IASEIA) США с 1994 года на русском и английском языках в целях поддержки медицинской науки и улучшения здравоохранения. В журнале публикуются оригинальные научные статьи в области медицины, биологии и фармации, статьи обзорного характера, научные сообщения, новости медицины и здравоохранения.

Журнал индексируется в MEDLINE, отражён в базе данных SCOPUS, PubMed и ВИНТИ РАН. Полнотекстовые статьи журнала доступны через БД EBSCO.

GMN: Georgian Medical News – საქართველოს სამედიცინო სიახლენი – არის ყოველთვიური სამეცნიერო სამედიცინო რეცენზირებადი ჟურნალი, გამოიცემა 1994 წლიდან, წარმოადგენს სარედაქციო კოლეგიისა და აშშ-ის მეცნიერების, განათლების, ინდუსტრიის, ხელოვნებისა და ბუნებისმეტყველების საერთაშორისო აკადემიის ერთობლივ გამოცემას. GMN-ში რუსულ და ინგლისურ ენებზე ქვეყნდება ექსპერიმენტული, თეორიული და პრაქტიკული ხასიათის ორიგინალური სამეცნიერო სტატიები მედიცინის, ბიოლოგიისა და ფარმაციის სფეროში, მიმოხილვითი ხასიათის სტატიები.

ჟურნალი ინდექსირებულია MEDLINE-ის საერთაშორისო სისტემაში, ასახულია SCOPUS-ის, PubMed-ის და ВИНТИ РАН-ის მონაცემთა ბაზებში. სტატიების სრული ტექსტი ხელმისაწვდომია EBSCO-ს მონაცემთა ბაზებიდან.

МЕДИЦИНСКИЕ НОВОСТИ ГРУЗИИ

Ежемесячный совместный грузино-американский научный электронно-печатный журнал
Агентства медицинской информации Ассоциации деловой прессы Грузии,
Академии медицинских наук Грузии, Международной академии наук, индустрии,
образования и искусств США.
Издается с 1994 г., распространяется в СНГ, ЕС и США

ГЛАВНЫЙ РЕДАКТОР

Нино Микаберидзе

ЗАМЕСТИТЕЛЬ ГЛАВНОГО РЕДАКТОРА

Николай Пирцхалаишвили

НАУЧНО-РЕДАКЦИОННЫЙ СОВЕТ

Зураб Вадачкориа - председатель Научно-редакционного совета
Михаил Бахмутский (США), Александр Геннинг (Германия), Амиран Гамкрелидзе (Грузия),
Константин Кипиани (Грузия), Георгий Камкамидзе (Грузия),
Паата Куртанидзе (Грузия), Вахтанг Масхулия (Грузия), Тамара Микаберидзе (Грузия),
Тенгиз Ризнис (США), Реваз Сепиашвили (Грузия), Дэвид Элуа (США)

НАУЧНО-РЕДАКЦИОННАЯ КОЛЛЕГИЯ

Константин Кипиани - председатель Научно-редакционной коллегии
Архимандрит Адам - Вахтанг Ахаладзе, Амиран Антадзе, Нелли Антелава, Тенгиз Асатиани,
Гия Берадзе, Рима Бериашвили, Лео Бокерия, Отар Герзмава, Елене Гиоргадзе, Лиана Гогиашвили,
Нодар Гогебашвили, Николай Гонгадзе, Лия Дваладзе, Манана Жвания, Ирина Квачадзе,
Нана Квирквелия, Зураб Кеванишвили, Гурам Кикнадзе, Теймураз Лежава,
Нодар Ломидзе, Джанлуиджи Мелотти, Марина Мамаладзе, Караман Пагава,
Мамука Пирцхалаишвили, Анна Рехвиашвили, Мака Сологашвили, Рамаз Хецуриани,
Рудольф Хохенфеллнер, Кахабер Челидзе, Тинатин Чиковани, Арчил Чхотуа, Рамаз Шенгелия

Website:

www.geomednews.org

The International Academy of Sciences, Education, Industry & Arts. P.O.Box 390177,
Mountain View, CA, 94039-0177, USA. Tel/Fax: (650) 967-4733

Версия: печатная. **Цена:** свободная.

Условия подписки: подписка принимается на 6 и 12 месяцев.

По вопросам подписки обращаться по тел.: 293 66 78.

Контактный адрес: Грузия, 0177, Тбилиси, ул. Асатиани 7, III этаж, комната 313

тел.: 995(32) 254 24 91, 995(32) 222 54 18, 995(32) 253 70 58

Fax: +995(32) 253 70 58, e-mail: ninomikaber@hotmail.com; nikopir@dgmholding.com

По вопросам размещения рекламы обращаться по тел.: 5(99) 97 95 93

© 2001. Ассоциация деловой прессы Грузии

© 2001. The International Academy of Sciences,
Education, Industry & Arts (USA)

Содержание:

Лазишвили Г.Д., Егиазарян К.А., Ратъев А.П., Шпак М.А., Маглаперидзе И.Г. ГИБРИДНАЯ КОСТНО-ХРЯЩЕВАЯ ТРАНСПЛАНТАЦИЯ – НОВЫЙ СПОСОБ ХИРУРГИЧЕСКОГО ЛЕЧЕНИЯ РАССЕКАЮЩЕГО ОСТЕОХОНДРИТА КОЛЕННОГО СУСТАВА.....	7
Фищенко Я.В., Пионтковский В.К., Колисниченко В.А., Кравчук Л.Д. ПРИМЕНЕНИЕ ЭНДОСКОПИЧЕСКОЙ ТРАНСФОРАМИНАЛЬНОЙ МИКРОДИСКЭКТОМИИ В ЛЕЧЕНИИ ГРЫЖ МЕЖПОЗВОНКОВЫХ ДИСКОВ ПОЯСНИЧНОГО ОТДЕЛА.....	13
Dronov A., Zemskov S., Levchenko L., Rozhkova V., Prytkov F. FACTORS INFLUENCING RECOVERY AFTER PANCREATODUODENECTOMY: UNICENTER EXPERIENCE.....	17
Zasieda Y. EFFICIENCY EVALUATION OF COMBINED THERAPEUTIC APPROACH TO THE TREATMENT OF PEYRONIE'S DISEASE.....	20
Никитин А.Н., Бахтияров К.Р., Трубицына М.В. ОПЫТ ПРИМЕНЕНИЯ МЕТОДИКИ TOTRP В ЛЕЧЕНИИ СТРЕССОВОГО НЕДЕРЖАНИЯ МОЧИ У ЖЕНЩИН.....	25
Chigladze M. THE PREDICTIVE VALUE OF THE MATERNAL RISK FACTORS IN FETAL GROWTH RETARDATION.....	30
Lysenko O., Borysenko A. BIOACTIVE GLASS-CERAMIC COMPOSITION IN SURGICAL MANAGEMENT OF PERIODONTAL INTRABONY DEFECTS.....	34
Sevbitov A., Emelina G., Kuznetsova M., Dorofeev A., Emelina E. A STUDY OF THE PREVALENCE OF NON-CARIOUS DENTAL LESIONS RELATED TO PRODUCTION FACTORS IN RESIDENTS OF THE CITY OF PENZA.....	42
Lykhota K., Lykhota A., Petrychenko O. COMPARISON OF ECONOMIC EFFICIENCY OF ORTHODONTIC APPLIANCE FOR TREATMENT OF SAGITTAL BITE ANOMALIES.....	48
Stepanov Yu., Zavorodnia N., Lukianenko O., Konenko I., Yahmur V. ASSESSMENT OF THE HEPATIC AND PANCREATIC STRUCTURE WITH SHEAR WAVE ELASTOGRAPHY AND STEATOMETRY IN OBESE CHILDREN.....	51
Maharramova S., Kurbanov H. PECULIARITIES OF CLINICAL AND IMMUNOLOGICAL CHARACTERISTICS OF HERPESVIRUS INFECTIONS IN CHILDREN.....	57
Ивардава М.И., Сичинава И.В. НОВЫЕ МЕТОДЫ И ПЕРСПЕКТИВНЫЕ ПОДХОДЫ К ТЕРАПИИ ПИЩЕВОЙ АЛЛЕРГИИ У ДЕТЕЙ (ОБЗОР).....	61
Bukiy S., Olkhovskaya O., Kucherenko O., Olkhovsky E., Ogienko V. PECULIARITIES OF CYTOKINE RESPONSE IN CHILDREN WITH SHIGELLOSIS AND CONCOMITANT CYTOMEGALOVIRUS INFECTION.....	67
Чочия А.Т., Гогберашвили К.Я., Хачапуридзе Н.С., Бахтадзе С.З., Капанадзе Н.Б., Хундадзе М.С. СОВРЕМЕННЫЕ АСПЕКТЫ ДЕЙСТВИЯ КСЕНОБИОТИКОВ НА ОРГАНИЗМ ДЕТЕЙ И ПОДРОСТКОВ (ОБЗОР).....	71
Пивовар С.Н., Рудык Ю.С., Исаева А.С., Лозик Т.В., Гальчинская В.Ю., Бондарь Т.Н. ПОЛИМОРФИЗМ ГЕНОВ БЕТА ₁ - И БЕТА ₂ -АДРЕНОРЕЦЕПТОРОВ И ЭФФЕКТИВНОСТЬ БИСОПРОЛОЛА У БОЛЬНЫХ С СЕРДЕЧНОЙ НЕДОСТАТОЧНОСТЬЮ.....	76
Попов В.В., Явися А.М., Буланова Н.А., Иванов Г.Г., Хамидова Х.А., Панченкова Л.А., Мартынов А.И. КРИТЕРИИ ОЦЕНКИ КРАТКОСРОЧНОГО И ДЛИТЕЛЬНОГО ПРОГНОЗА У БОЛЬНЫХ В СТАЦИОНАРЕ НА ОСНОВЕ ХАРАКТЕРИСТИК ЭКГ СИГНАЛА ПРИ ПОСТУПЛЕНИИ. ОБОСНОВАНИЕ И ДИЗАЙН ИССЛЕДОВАНИЯ.....	84

The awareness of risk factors allows us to employ the timely measures for the reduction of negative impact on the fetus and neonate.

Keywords: Growth retardation, Fetal, Intrauterine, Genital pathology, Growth restriction.

РЕЗЮМЕ

РИСК-ФАКТОРЫ ПРИ ВНУТРИУТРОБНОЙ ЗАДЕРЖКЕ РАЗВИТИЯ ПЛОДА И ИХ ПРЕДИКТОРНОЕ ЗНАЧЕНИЕ

Чигладзе М.Ш.

Тбилисский государственный университет им. И. Джавахиди, медицинский факультет, Грузия

Целью исследования явилось определение социально-гигиенических и медико-биологических факторов внутриутробной задержки развития плода и их предикторного значения.

Проведено ретроспективное исследование методом случай-контроль с участием 142 рожениц. Исследуемую группу составили 92 матери, беременность которых завершилась рождением детей с внутриутробной задержкой развития. В контрольную группу вошли 50 рожениц со здоровыми новорожденными.

Результаты исследования выявили приоритетные риск-факторы: низкий уровень жизни (OR-3.61), нарушение сна (OR-3.33), хронический стресс (OR-3.06) и нерациональное питание (OR-3.81).

Что касается сочетанных патологий: эндокринная патология (OR-3.27), ишемическая болезнь сердца (OR-4.35), артериальная гипертензия (OR-6.47), железодефицитная анемия (OR-4.11), патология дыхательной системы (OR-3.42). Выявлена высокая предикторная значимость преэклампсии (92%) и низкого уровня околоплодных вод (89%).

Своевременное выявление риск-факторов внутриутроб-

ной задержки развития плода позволяет устранить их отрицательное влияние на плод и новорожденного.

რეზიუმე

ნაყოფის განვითარების შეფერხების რისკ-ფაქტორები და მათი პრედიქტორული მნიშვნელობა

მ. ჭიღლაძე

ი. ჯავახიშვილის სახ. სახელმწიფო უნივერსიტეტი, მედიცინის ფაკულტეტი, საქართველო

კვლევის მიზანს შეადგენდა დედის სოციალურ-ჰიგიენური და სამედიცინო-ბიოლოგიური რისკ-ფაქტორების შესწავლა და პრედიქტორული მნიშვნელობის განსაზღვრა.

ჩატარდა რეტროსპექტული კვლევა შემთხვევა-კონტროლი, რომელშიც მონაწილეობდა 142 ორსული. ძირითადი ჯგუფი შეადგინა 92 მშობიარემ, რომელთა ორსულობა დასრულდა საშვილოსნოსშიდა განვითარების შეფერხების მქონე ახალშობილის დაბადებით; საკონტროლო ჯგუფი - 50-მა ორსულმა, რომელთა ორსულობა დასრულდა ჯანმრთელი ახალშობილის დაბადებით. კვლევის შედეგებმა გამოავლინა შემდეგი რისკ-ფაქტორები: ცხოვრების დაბალი დონე (OR-3.61), ქრონიკული სტრესი (OR-3.06), ძილის დარღვევა (OR-3.33) და არასრულფასოვანი კვება (OR-3.81).

თანარსებული პათოლოგიის მხრივ: ენდოკრინული პათოლოგია (OR-3.27), გულის იშემიური დაავადება (OR-4.35), არტერიული ჰიპერტენზია (OR-6.47), რკინადაფიციტური ანემია (OR-4.11), სასუნთქი სისტემის პათოლოგია (OR-3.42). მაღალი პრედიქტორული მნიშვნელობა აღმოჩნდა პრეეკლამფსიას (92%) და მცირე წყლიანობას (89%).

რისკის ფაქტორების გამოვლენა საშუალებას იძლევა დროულად ჩატარდეს ნაყოფსა და ახალშობილზე ნეგატიური ზემოქმედების შემცირების ღონისძიებები.

BIOACTIVE GLASS-CERAMIC COMPOSITION IN SURGICAL MANAGEMENT OF PERIODONTAL INTRABONY DEFECTS

Lysenko O., Borysenko A.

O. Bogomolets National Medical University, Kyiv, Ukraine

Various treatment modalities have been investigated to repair/regenerate periodontal tissues in an attempt to reach goal of periodontal regeneration – gain periodontal attachment in severely compromised teeth, decrease pocket depth, and stabilize gingival recession [1]. Guided tissue regeneration (GTR) is preferred in the case of noncontaining defect and extended flaps, which allows to preventing apical epithelium proliferation, thickening the soft tissue profile, and providing support for blood clot [18]. The additional use of bone graft is not an obligate precondition. But such biomaterial supports barrier membrane from collapse

into intrabony defect side, creates favorable conditions for accelerating the restoration of bone tissue.

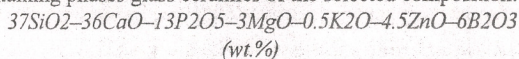
According to literature review, the research continues for biomaterials that would satisfy all requirements for periodontal regeneration [22]. Recently, synthetic products have been developed, regulating composition and method of preparation which allows achieve the necessary rate of biotransformation, complete biodegradation, antibacterial activity, pronounced osteoconduction, and even osteoinduction [25]. This is achieved due to guided change in the chemical composition of ceramic

systems and their physical properties: differentiated microporosity, nanostructuring, substitution of anionic and cationic phases, addition of new elements [23]. Another way is the introduction of biological agents – collagen, chitosan, protein and platelet-derived growth factors, platelet concentrations [6], the use of bio-ceramics as scaffolds for tissue-engineering needs [14].

One such biomaterial can be a new bioactive ceramic nanocomposite, where additional doped of ceramic components with silver and copper ions was used as directed functionalization [11]. We have developed the bone substitute composition based on this bio-ceramics in combination with a medicine containing glycosaminoglycan compounds (GAGs). GAGs are actively involved in the formation, development and repair of periodontal tissues [19]. Scabbia et al. [21] has reported that appliance of hydroxyapatite-based biomaterial with chondroitin sulphate (Biostite®, Vevas s.r.l., Italy) in deep intrabony defects significantly improves periodontal healing. However, to apply of the proposed composition such as bone graft in order to stimulate reparation/regeneration of periodontal tissues in flap surgery requires further studies.

Thus, the aim of this research was to investigate clinical and radiological efficacy of the proposed bioactive glass-ceramic composition as bone substitute material for intrabony defects in patients with periodontitis during GTR surgical procedure.

Material and methods. Bioactive glass-ceramic composition (BGCC) feature. Samples of the bioactive ceramic composite are microporous granules ranged in size from 0.3 to 0.7 mm consist of uniformly distributed nanostructured particles (30-50 nm) of biphasic calcium phosphate ceramics (hydroxyapatite (15-20%) and β -tricalcium phosphate (15-20%)), and the rest (60-70%) containing phases glass ceramics of the selected composition:



To add antibacterial properties, the granules of the ceramic composite were additionally doped with silver (1 at.%) and copper (0.5 at.%).

To further additional stimulation of periodontal regeneration, we proposed to introduce bone metabolism corrector (Alflutop®, Biotehnos S.A., Romania) into the bioactive ceramic composite. The medicine is available in ampoules, in the form of a sterile solution for injection, which contains a low-fat biologically active extract of small marine fish. The extract contains a significant quantity of GAGs, sulfated polysaccharides and mineral salts of sodium, potassium, calcium, magnesium, iron, copper, and zinc.

Study population. The study was conducted in a clinical group of 47 patients (28 men and 19 women), with an average age of 43.2 ± 1.7 years, suffering from periodontitis, stage III, IV; grade A, B. Inclusion criteria: patients suffered from periodontitis and who consented to participate in the study, presence of a narrow intrabony noncontaining defect with depth of 5 mm and more. Exclusion criteria: presence of a width intrabony defect and horizontal type of an alveolar bone resorption, presence less than 2 mm keratinized gingiva, smokers, patients with allergic anamnesis and decompensated related systemic pathology, pregnant women and lactating mothers.

All patients underwent surgical treatment after successful initial periodontal therapy consisting of oral hygiene instructions and scaling and root planing. Which led to soft tissues acute inflammatory reactions elimination, to gingival and hygienic indices normalization. Teeth presenting with mobility greater grade 1 were temporary splinted before surgery for 4 weeks. Patients randomization was done by blind method in two experimental groups (main and control). 24 patients both women and men, with average age 45.2 ± 1.2 years, were included in the control

group. All surgeries and measurements were performed by the same operator.

The clinical study was conducted in compliance with bioethical standards and agreed by the Bogomolets National Medical University (Kyiv, Ukraine) Bioethics Committee, protocol № 82 from 08.10.2014. Informed consent was obtained from all individual participants included in the study.

Surgical technique and postoperative management. After local anesthesia at the surgical site full thickness mucoperiosteal flap was elevated after intracervicular incisions were performed both buccally and lingually. In case of width interdental space (>2 mm) the modified papilla preservation technique was applied [5]. After flap reflection and bone defect exposure the periodontal full debridement was carried out. The root surface was conditioned with chelating agent (PrefGel®, Straumann, Switzerland) during 2-3 min. The intrabony defect was filled with bone substitute grafts. A barrier membrane was adapted to defect margins and it was fixed after sterile saline solution hydrated. The wound suturing was performed with monofilament suture (5/0-6/0 Prolene®, Ethicon, USA) using single internal mattress or double internal mattress technics.

In the main group were applied BGCC and bioresorbable collagen membrane (Bio-Gide®, Geistlich Pharma AG, Switzerland) (Fig. 1B). Previously BGCC sterilized granules were hydrated in GAGs-based solution during 2-3 min. In the control group were used the same barrier membrane and deproteinized bovine bone mineral (DBBM) (Bio-Oss®, Geistlich Pharma AG, Switzerland) – S fraction, with 0.25-1.0 mm size granules.

Postoperative management of patients was carried out according to generally accepted protocols and the same in both clinical groups. No systemic antibiotic coverage was used. 0.12% Chlorhexidine solution mouth-rinsing 3-4 times per day during 10 days were prescribed. Patients were strongly requested to avoid brushing, flossing and chewing in the treated area. Local hypothermia on skin from the side of surgery during 5-7 min was proposed. A one week after sutures were removed and the supragingival surgery site gently debrided.

Clinical data assessment. In the early postoperative period (7, 14 days) of postoperative pain, bleeding, hyperemia and soft tissue swelling intensity was assessed according to the significant criteria: none, minor, moderate or severe. The condition of the mucoperiosteal flaps was estimated according to the early wound-healing index by Wachtel et al. [28].

The following clinical parameters were evaluated at baseline, 6- and 12-months follow-up: clinical attachment level (CAL), pocket probing depth (PPD), gingival recession level using UNC 15 (LMDental, Finland) probe. Defect morphology was characterized after flap reflection and debridement in terms of distance between the cemento-enamel junction and the bottom of the defect (CEJ-BD) (Fig. 1A). Any probing of periodontal tissues was ruled out for the first 3 months. Hygienic status and inflammation degree of periodontal tissues in general and locally, in the treated sites, were recorded from baseline using Full Month Plaque Score index (FMPS) [15], Papilla Bleeding index (PBI) [13], Plaque index (PI) and Gingival index (GI) [10] and were reevaluated 6, 12 months after surgery.

Radiological data assessment. The alveolar bone tissue condition was assessed by X-ray panoramic view, intraoral contact radiograms, and Cone Beam Computed Tomography (CBCT). The quality of bone tissue was assessed supporting beam densitometry, have been used software SimPlant Pro (ver. 11.02, Materialise, Belgium) tools by an algorithm represented earlier [17]. The features of periodontal defects topography, their configuration and relation

to the surrounding teeth at baseline and follow-up 12 months after surgical treatment were performed according to three-dimensional reconstructions obtained from CBCT data.

Linear measurements (in mm) of distance between the CEJ and the BD (A_1) and the most coronally located part of the alveolar crest (C) were performed on all three-dimensional reconstructions of periodontal defects at baseline. The intraosseous component value of intrabony defects (B_1) were calculated by the formula: where B – distance between the crest of the alveolar bone and the bottom of the defect [20]. A year later, postoperative marks were determined in the same positions (A_2 , B_2).

The intrabony defect bone filling value (D) determined by difference in mm. The radiological periodontal defect filling percentage was calculated by the formula [9]:

$$\frac{D}{A_1} \times 100.$$

Proportionality $(B_1 - B_2) / B_1 \times 100$ has been used for estima-

tion the radiological filling percentage intraosseous component of the intrabony defect.

Statistical analysis. Software Statistica (ver. 10.1, StatSoft Inc., USA) was used to analysis. Kolmogorov-Smirnov test was applied to confirm normal data distribution ($\alpha=0.05$). Evaluation of results were performed by statistical variational and variance ANOVA analysis, paired and unpaired t-test for twin comparisons. A data was considered statistically significant for $p < 0.05$. All quantitative parameters are represented in Mean \pm SE format in which M – statistical mean, SE – standard error, and n – subject quantity.

Results and their discussion. The main group consisted of 23 patients, among whom IV grade periodontitis was diagnosed in 15 (65.2%) persons, III grade – in 8 (34.7%). The control group included 24 patients, among them 18 (75%) persons with IV grade periodontitis and 6 (25%) persons with III grade periodontitis. The distribution of patients, periodontal defects and their characteristics are presented in Table 1.

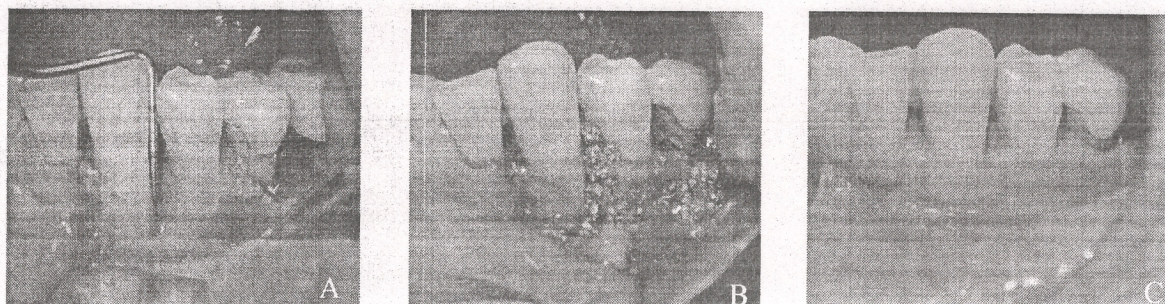


Fig. 1. Clinical images. (A) The intrabony defect after flap reflection, CAL is 9 mm. (B) Filling the intrabony defect with the bone substitute within contours of the alveolar bone prior to a barrier membrane placing. (C) Clinical outcome in position teeth 3.3-3.5 at the 6th month after surgery – gingival marginal part restoration, CAL – 4 mm, gingival recession within 2 mm. CAL – clinical attachment level

Table 1. Characteristics of patients and periodontal intrabony defects in the main and control groups before surgical treatment

Parameter	Group		p-value
	Main	Control	
Patients number (n=47)	23	24	–
Age of patients (years)	42.1 \pm 1.8	45.2 \pm 1.2	0.18
Intrabony defects (n=56)	27 (48%)	29 (52%)	0.78
PPD (mm)	6.93 \pm 0.26	7.06 \pm 0.19	0.69
CAL (mm)	8.37 \pm 0.35	8.57 \pm 0.37	0.73
Gingival recession (mm)	1.44 \pm 0.17	1.51 \pm 0.18	0.78
Radiographic defect depth, CEJ-BD (mm)	9.17 \pm 0.31	9.47 \pm 0.32	0.51
Intrabony component, AC-BD (mm)	5.57 \pm 0.42	6.17 \pm 0.37	0.29

notes: CEJ – cemento-enamel junction, AC – alveolar crest, BD – bottom of the defect

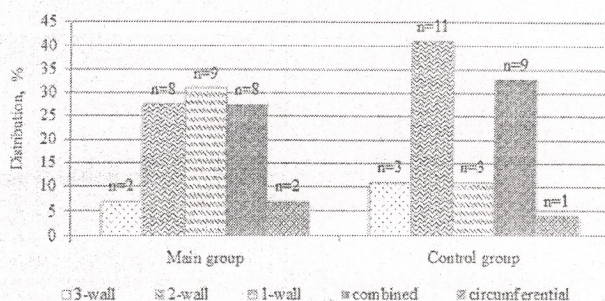


Fig. 2. Intergroup distribution of intrabony defects and their type

Table 2. Clinical parameters changing in dynamics: CAL, PPD, gingival recession, inflammation degree of periodontal tissues and hygienic indices in groups

Parameter	Baseline (BS)	6 months	12 months	BS-6 mo, p-value*	BS-12 mo, p-value*
CAL (mm)					
Main group (n=27)	8.37±0.35	5.54±0.32	5.81±0.31	<0.01	<0.01
Control group (n=29)	8.57±0.37	5.83±0.26	6.37±0.28	<0.01	≤0.01
p-value**	0.73	0.48	0.18		
PPD (mm)					
Main group (n=27)	6.93±0.26	3.14±0.32	3.22±0.36	<0.01	<0.01
Control group (n=29)	7.06±0.19	3.72±0.27	3.86±0.24	<0.01	<0.01
p-value**	0.69	0.16	0.14		
Gingival recession (mm)					
Main group (n=27)	1.44±0.17	2.35±0.19	2.54±0.20	<0.05	<0.01
Control group (n=29)	1.51±0.18	2.21±0.16	2.41±0.18	<0.05	<0.01
p-value**	0.78	0.57	0.63		
FMPS (%)					
Main group (n=27)	8.60±1.70	19.40±3.10	18.12±2.90	<0.01	≤0.01
Control group (n=29)	12.23±1.96	23.80±3.20	20.23±2.70	<0.01	<0.05
p-value**	0.17	0.32	0.57		
PI (score)					
Main group (n=27)	0.16±0.05	0.13±0.04	0.19±0.03	>0.05	>0.05
Control group (n=29)	0.18±0.04	0.19±0.05	0.21±0.03	>0.05	>0.05
p-value**	0.75	0.35	0.64		
PBI (score)					
Main group (n=27)	0.89±0.19	1.12±0.18	1.19±0.18	>0.05	>0.05
Control group (n=29)	0.87±0.15	1.08±0.14	1.14±0.15	>0.05	>0.05
p-value**	0.93	0.82	0.59		
GI (score)					
Main group (n=27)	0.52±0.07	0.17±0.05	0.15±0.04	<0.01	<0.01
Control group (n=29)	0.51±0.05	0.26±0.04	0.29±0.05	<0.01	<0.01
p-value**	0.90	0.16	<0.05		

notes: CAL – clinical attachment level, PPD – pocket probing depth, FMPS – Full Month Plaque Score, PBI – Papilla Bleeding index, GI and PI – Gingival and Plaque index, *paired t-test, **unpaired t-test

A total of 56 intrabony defects underwent surgical treatment: in the main group 27 (48.2%) and in the control group – 29 (51.8%) subjects. Of these, 26 (46.4%) were placed on the maxilla and 30 (53.6%) were placed on the mandible. Of teeth in the treated sites of which intrabony defects localized, dominated frontal – 35 (62.5%) teeth, and lateral ones were 21 (37.5%) teeth. The distribution of intrabony defects types are presented in Fig. 2.

Early clinical results. Immediately after surgery, after 7 days and 14 days during the early postoperative period according to the EHI no significant difference between the groups was detected ($p>0.05$). Distribution of the treated sites according to the EHI, 1-5 score, after surgery is shown in Fig. 3. Incomplete flap closure resulting in a negative healing of the interproximal tissue was not present in treated sites after 14 days. Any inflammatory complications or rejection of graft granules of osteoplastic materials or barrier membrane exposure did not occur during the entire study period in both clinical groups.

© GMN

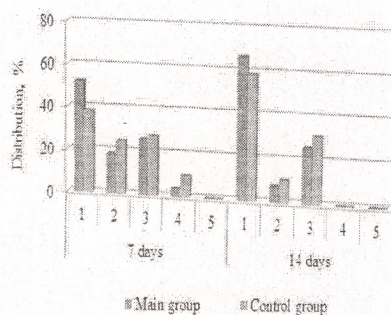


Fig. 3. Early wound healing index percentage (by Wachtel et al. [28]) in treated sites 2 weeks after surgery: 1 – complete flap closure - no fibrin line in the interproximal area; 2 – complete flap closure - fine fibrin line in the interproximal area; 3 – complete flap closure - fibrin clot in the interproximal area; 4 – incomplete flap closure - partial necrosis of the interproximal tissue; 5 – incomplete flap closure - complete necrosis of the interproximal tissue

In the main group, there was a slight decrease in discomfort for all patients at an early stage in terms of pain intensity, soft tissue bleeding and swelling in treated sites in Fig. 4.

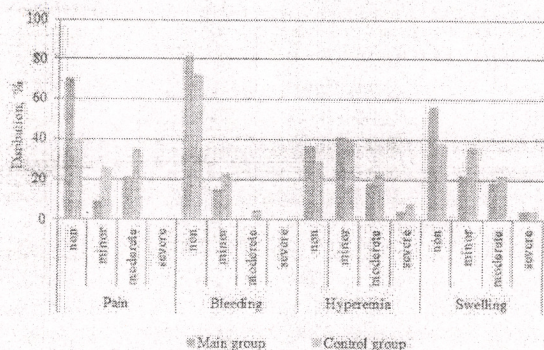


Fig. 4. Percentage of discomfort factors for patients in early period after surgery (in %)

Late clinical results. Clinical results at 6 and 12 months after periodontal treatment are presented in Table 2. Bone substitute materials used for guided tissue regeneration in all groups led to a significant clinical improvement in periodontal conditions.

After 6 months follow-up, probing depth of periodontal defects halved. The level of CAL increased from baseline by 33.8% in the main group: before treatment 8.37 ± 0.35 mm, after -5.54 ± 0.32 mm ($p < 0.01$). In the control group, it was 31.9% less than at baseline: 8.57 ± 0.37 mm before treatment and 5.83 ± 0.26 mm ($p < 0.01$). However, the main group identified an increase in gingival recession by 63.2% – 2.35 ± 0.19 mm, and in the control group by 46.3% – 2.21 ± 0.16 mm compared with baseline. GI directly determined in the treated sites was 0.17 ± 0.05 in the main group, which was significantly different ($p < 0.05$) from the previous result and 0.26 ± 0.04 in the control group, which was 11.5% higher than the previous value at baseline. No significant changes in PI were found in both clinical groups ($p > 0.05$).

In this period was observed stabilization of pathological processes in the treated sites of all patient's groups. The discomfort feeling and other symptoms in periodontal tissues completely disappeared, the normalization of tooth function was noted, the mobility of the teeth completely disappeared. Objective examination of both groups revealed a pale pink color mucosa of marginal and attached gingiva. Complete restoration of the papillae configuration was achieved – they are compacted and evenly between the interdental spaces, closed to the teeth (Fig. 1C).

After 12 months follow-up, gingival recession in both clinical groups increased by 1.1 ± 0.19 mm and by 0.90 ± 0.12 mm respectively relative to baseline without significant differences between the groups ($p > 0.05$). PPD in tested sites

of the main group was 3.22 ± 0.36 mm and in the control – 3.86 ± 0.24 mm ($p > 0.05$). The rate of clinical attachment loss in the main group was less than at baseline by 2.55 ± 0.38 mm ($p < 0.01$), in the control group – by 2.40 ± 0.18 mm ($p < 0.01$). No significant changes in FMPS and PI index were detected ($p > 0.05$). In the control group, GI tended to deteriorate; in the main – it remained unchanged.

The clinical study demonstrated formation of a new clinical attachment level, up to 4-5 mm, 12 months after surgical treatment in both groups. In the main group, there was an increasing distribution of intrabony defects in terms of reduction of attachment loss: a gain CAL within 2 mm was observed in 25.9%, 2-3 mm in 33.4%, and more than 3 mm was observed in 40.7% of the total number of intrabony defects. The control group was dominated by the number of intrabony defects in which the reduction in clinical attachment loss was minimal (34.5%) and largest (44.8%), and a reduction of 2-3 mm was observed in only 20.7% of the total number of defects (Fig. 5).

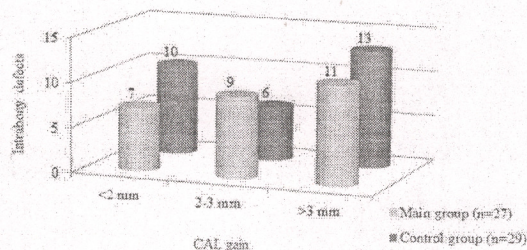


Fig. 5. Distribution (number) of intrabony defects depending on the attachment loss reduction a year after surgery. CAL – clinical attachment level

Radiological results. Radiographically determined CAL was gained by 2.53 ± 0.27 mm in the main group and 2.85 ± 0.33 mm in the control group after 12 months, reflecting the percentage of filling intrabony defects with bone tissue by 27.5% and by 30.1% respectively. In the main group the percentage of bone filling was 45.4% and in the control one – 46.2%. Some reparative/regeneration bone processes were occurred from the 9th-10th month in the control group and from the 8th-9th month in treated sites of the main group. Even a year later, there was no bone augmentation in the one site (3.7%) in the main group and two sites (6.8%) in the control group. In these cases, radiographic shadow of the bone substitute continued to be unchanged throughout trial period.

Densitometric study in the main group determined a significant ($p < 0.05$) increase density in the alveolar bone and the interdental septa by 47.3% to 1065.3 ± 27.1 Hounsfield units (HU) a year after surgery. In the control group it increased by 32.6% ($p < 0.05$) to 876.6 ± 22.8 HU respectively in Table 3. Final bone formation occurred only from the 12th month without benefits from each of clinical groups (Fig. 6).

Table 3. Radiographic bone densitometry indicators of interdental septa in tested sites (in Hounsfield units)

Group	Baseline (BS)	After surgery			p-value*
		12 months	max	min	
Main (n=27)	723.2 ± 41.1	1065.3 ± 27.1	1286.7	762.9	<0.05
Control (n=29)	671.1 ± 37.8	876.6 ± 22.8	1166.5	625.6	<0.05
p-value**	>0.05	<0.05			

notes: *paired t-test, **unpaired t-test

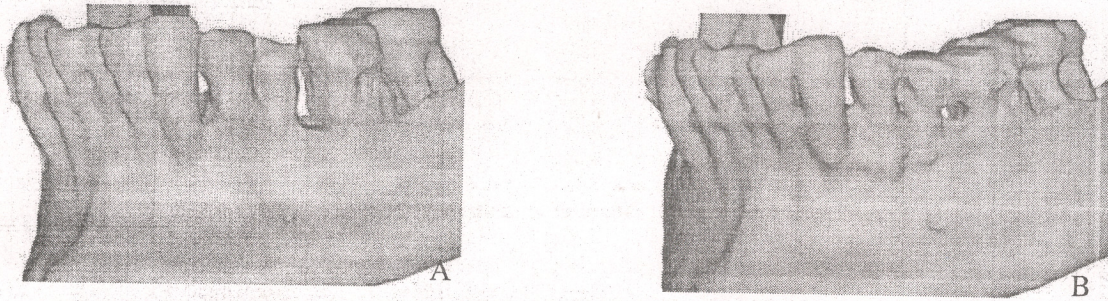


Fig. 6. Cone beam computed tomography reconstruction. (A) Three-dimensional reconstruction of mandible to visualize the spatial topography of intrabony defects in position teeth 3.3-3.7. (B) Three-dimensional reconstruction of mandible one year after surgery. Radiographic signs of the interdental septa bone tissue restoration in position teeth 3.3-3.6

Periodontal regeneration has been the subject of many previous fundamental studies [2,4,6,18]. Several surgical approaches have already been proposed with many different regenerative materials, including barrier membranes, grafts, active biological compounds and combinations of those for clinical improvements in intrabony defects, but none has demonstrated clear superiority over the others.

Although the clinical efficacy of surgical access in this 12-month follow-up study was determined by the stabilization of the pathological process in periodontal tissues, the results obtained were no more significant than those of the group for comparison. Almost the same decrease in the depth of intrabony defects was determined by 53.5% in the main group (from 6.93 ± 0.26 mm to 3.22 ± 0.36 mm) and by 45.7% in the control group (from 7.06 ± 0.19 mm to 3.86 ± 0.24 mm). The level of clinical attachment loss was reduced by 30.4% (from 8.37 ± 0.35 mm to 5.81 ± 0.31 mm) in the main group and by 28.0% (from 8.57 ± 0.37 mm to 6.37 ± 0.28 mm) in the control group ($p < 0.05$). In the present study, BGCC and DBBM together with collagen membrane resulted in significant improvement of all clinical parameters with a mean bone fill of 45.4% and in the control one – 46.2% respectively. This compares well with results obtained in other similar studies using other types of biomaterials for periodontal regeneration: only barrier membrane [12], amelogenins [8], their combination [27], xenogeneic bone grafts [9], calcium phosphate ceramics, and bioglass [22]. According to Camelo et al. [3] in study, histologically confirmed that combination of autogenous bone/DBBM graft and collagen membrane stimulates the bone formation, periodontal ligament, and tooth cement. Oortgiesen et al. [16] reported alkaline phosphatase immobilization more pronounced onto DBBM and collagen membrane combination. Periodontal and bone regeneration was demonstrated in vivo experimental model.

However, in this study, unlike the other, there were evidences of significant gingival recession increasing by approximately 60% within one year after surgery (Table 2). This may be explained by the postoperative soft tissues retraction, although causes of this require further study.

The proposed composition for GTR stimulated periodontal repair/regeneration in principle within significant limits. It is not possible to disagree with findings Susin and Wikesjö [26], effective regeneration in the first requires: sufficient tissues vascularization, minimal invasiveness, biological feasibility, defect morphology features, surgical approach, surgical skills only then bone grafts choice.

Perhaps the biggest failure of GTR is membrane exposure with followed bacterial contamination. However, a barrier

membrane itself can accumulate oral cavity microflora and periodontopathogens [24]. Dóri et al. [7] suggested that the presence of periodontopathogens in the regenerated site may negatively influence the clinical outcomes. Thus, antimicrobial additives have been specifically added to BGCC structure to prevent these phenomena. Zhang et al. [29] reported that bioglass components themselves demonstrate varying degrees of antibacterial properties. Indirectly, the antibacterial activity of the doped silver and copper ceramics was manifested by maintaining GI within achieved limits in the main group at the 12th month (Table 2), unlike in the control group, where it tended to increase ($p < 0.05$). In this study, decline hygienic and PBI indices after surgery did not lead to significant changes in the local recorded Gingival index (Table 2). Which may determine the treated tissues high resistance to bacteria. However, against the background of a tendency for general hygiene of the oral cavity reduction, the hygienic indices determined in the tested sites did not change significantly. Which may indicate a more active hygiene of patients in these sites.

However, significant influence of the proposed glass-ceramic composition on bone mineralization was determined. The CBCT examination confirmed after BGCC appliance the bone pattern resembled a natural one. In the control group some radiocontrast inclusions were identified, indicates incomplete resorption of DBBM. The bone density profile of the restored/regenerated bone was 21.7% higher in the main group than in the control group ($p < 0.05$). These findings are supported in other in vivo studies [11].

Undifferentiated approach to intrabony defects in the site of dental furcation and interdental areas, non-controlled endodontic treatment, limited clinical trial within one year, lack of histological data, small sample of patients can be attributed as limitations in this study.

Conclusions. Within the limits of the study, it can be inferred that generally no significant differences were found either by using BGCC with collagen membrane or DBBM with collagen membrane in the treatment of intrabony defects both clinically and radiographically.

Application BGCC with collagen membrane in treatment intrabony defects leads to significant reduction in probing depth, clinical attachment level gain, and raises bone density profile. Thus, it allows to consider such bioactive glass-ceramic composition as bone substitute material of choice during preoperative plane of surgical treatment for patients with periodontitis. However, further long-term clinical studies with histological evaluation are necessary.

REFERENCES

1. Ausenda F, Rasperini G, Acunzo R, Gorbunkova A, Pagni G. New perspectives in the use of biomaterials for periodontal regeneration. // *Materials (Basel)* 2019; 12: 2197.
2. Bosshardt DD, Sculean A. Does periodontal tissue regeneration really work? // *Periodontol* 2000. 2009; 51: 208-19.
3. Camelo M, Nevins ML, Lynch SE, Schenk RK, Simion M, Nevins M. Periodontal regeneration with an autogenous bone-Bio-Oss composite graft and a Bio-Gide membrane. // *Int J Periodontics Restorative Dent* 2001; 21: 109-19.
4. Cortellini P, Buti J, Pini Prato G, Tonetti MS. Periodontal regeneration compared with access flap surgery in human intrabony defects 20-year follow-up of a randomized clinical trial: tooth retention, periodontitis recurrence and costs. // *J Clin Periodontol* 2017; 44: 58-66.
5. Cortellini P, Prato G, Tonetti MS. The modified papilla preservation technique. A new surgical approach for interproximal regenerative procedures. // *J Periodontol* 1995; 66: 261-66.
6. Cortellini P, Tonetti MS. Clinical concepts for regenerative therapy in intrabony defects. *Periodontol.* - 2000. - V.68 (1): 282-307.
7. Dóri F, Kristóf K, Gera I, Sculean A, Eick S. Bacterial contamination of ePTFE membranes following regenerative surgery of intrabony defects treated with platelet-rich plasma and natural bone mineral. // *Oral Health Prev Dent* 2019; 2: 1-7.
8. Esposito M, Grusovin MG, Papanikolaou N, Coulthard P, Worthington HV. Enamel matrix derivative (Emdogain) for periodontal tissue regeneration in intrabony defects. // *Cochrane Database Syst Rev* 2009; 4: CD003875.
9. Gokhale ST, Dwarakanath CD. The use of a natural osteoconductive porous bone mineral (Bio-Oss™) in infrabony periodontal defects. // *Indian Soc Periodontol* 2012; 16: 247-52.
10. Löe H. The Gingival Index, the Plaque Index and the Retention Index systems. // *J Periodontol* 1967; 38: 610-6.
11. Lysenko O, Dubok O, Borysenko A, Shinkaruk O. The biological properties of the silver and copper-doped ceramic. // *J Nanopart Res* 2015; 17: 178-93.
12. Mayfield L, Söderholm G, Hallström H, Kullendorff B, Edwardsson S, Bratthall G, et al. Guided tissue regeneration for the treatment of intraosseous defects using a biabsorbable membrane. A controlled clinical study. // *J Clin Periodontol* 1998; 25: 585-95.
13. Mühlemann HR. Psychological and chemical mediators of gingival health. // *J Prev Dent* 1977; 4: 6-11.
14. Novello S, Debouche A, Philippe M, Naudet F, Jeanne SJ. Clinical application of mesenchymal stem cells in periodontal regeneration: A systematic review and meta-analysis. // *Periodontol Res* 2019. doi: 10.1111/jre.12684.
15. O'Leary TJ, Drake RB, Naylor JE. The plaque control record. // *J Periodontol* 1972; 43: 38.
16. Oortgiesen DA, Plachokova AS, Geenen C, Meijer GJ, Walboomers XF, van den Beucken JJ, et al. Alkaline phosphatase immobilization onto Bio-Gide® and Bio-Oss® for periodontal and bone regeneration. // *J Clin Periodontol* 2012; 39: 546-55.
17. Osnach R, Lysenko O, Palivoda I. Radiographic jaws densitometry for orthodontic tooth movement rate estimation. // *Современная стоматология* 2015; 4: 120-4 (in Ukrainian).
18. Polimeni G, Xirapaidis VX, Wikesjo UME. Biology and principles of periodontal wound healing/regeneration. // *Periodontol* 2000 2006; 41: 30-47.
19. Reynolds JJ, Meikle MC. Mechanisms of connective tissue matrix destruction in periodontitis. // *Periodontol* 2000 1997; 14: 144-57.

20. Santosh Kumar BB, Aruna DR, Gowda VS, Galagali SR, Prashanthi R, Navaneetha H. Clinical and radiographical evaluation of a bioresorbable collagen membrane of fish origin in the treatment of periodontal intrabony defects: a preliminary study. // *J Indian Soc Periodontol* 2013; 17: 624-30.
21. Scabbia A, Trombelli L. A comparative study on the use of a HA/collagen/chondroitin sulphate biomaterial (Biostite) and a bovine-derived HA xenograft (Bio-Oss) in the treatment of deep intra-osseous defects. // *J Clin Periodontol* 2004; 31: 348-55.
22. Sheikh Z, Hamdan N, Ikeda Y, Grynypas M. Natural graft tissues and synthetic biomaterials for periodontal and alveolar bone reconstructive applications: A review. // *Biomater Res* 2017; 21: 9.
23. Shepherd JH, Shepherd DV, Best SM. Substituted hydroxyapatites for bone repair. // *J Mater Sci Mater Med* 2012; 23: 2335-47.
24. Slutzkey S, Kozlovsky A, Artzi Z, Matalon S. Collagen barrier membranes may accelerate bacterial growth in vitro: a potential clinical risk to regenerative procedures. // *Quintessence Int* 2015; 46: 43-50.
25. Song J. A chemical and engineering approach towards «smart» synthetic bone grafts. // *J Musculoskelet Neuronal Interact* 2007; 7: 325.
26. Susin C, Wikesjö UM. Regenerative periodontal therapy: 30 years of lessons learned and unlearned. // *Periodontol* 2000 2013; 62: 232-42.
27. Tu Y, Needleman I, Chambrone L, Lu HK, Faggion CM Jr. A Bayesian network meta-analysis on comparisons of enamel matrix derivatives, guided tissue regeneration and their combination therapies. // *J Clin Periodontol* 2012; 39: 303-14.
28. Wachtel H, Schenk G, Böhm S, Weng D, Zuhur O, Hürzeler MB. Microsurgical access flap and enamel matrix derivative for the treatment of periodontal intrabony defects: a controlled clinical study. // *J Clin Periodontol* 2003; 30: 496-504.
29. Zhang D, Leppä O, Munukka E, Ylänen H, Viljanen MK, Eerola E, et al. Antibacterial effects and dissolution behavior of six bioactive glasses. // *J Biomed Mater Res* 2010; 93: 475-83.

SUMMARY

BIOACTIVE GLASS-CERAMIC COMPOSITION IN SURGICAL MANAGEMENT OF PERIODONTAL INTRABONY DEFECTS

Lysenko O., Borysenko A.

O. Bogomolets National Medical University, Kyiv, Ukraine

It has been earlier proposed a novel graft on basis of bioactive glass-ceramics for infected bony defects, where silver and copper ions are represented as antibacterial agents.

The objective was to investigate clinical and radiological efficacy of the bioactive glass-ceramic composition (BGCC) as bone substitute material for periodontal intrabony defects surgery.

In a group of 47 patients with periodontitis was conducted controlled clinical study of the proposed composition. As a control in 24 patients it has been used deproteinized bovine bone mineral (DBBM) with collagen membrane. Such parameters as pocket probing depth (PPD), clinical attachment level (CAL), gingival recession, the early wound-healing index (EHI), hygienic and gingival indices, radiological bone density were used for evaluation surgical outcomes.

Guided tissue regeneration was carried out in 56 intrabony defects. A year after surgery it has been determined almost the same significant ($p < 0.05$) decrease PPD to 53.5% in the BGCC group and to 45.7% in the DBBM group, CAL gain to 30.4% in the BGCC group and to 28.0% in the DBBM group. Intrabony defects were bone filled to 27.5% and to 30.1% respectively with no significant differences for comparison groups. However, it was noted the advantage of significant increasing bone density in treated sites with BGCC ($p < 0.05$). It also has shown a tendency to decrease discomfort for patients and to improve wound healing in postsurgical period according to the EHI in the same group.

The using of BGCC with collagen membrane leads to significant reduction in probing depth, clinical attachment level gain, raises bone density profile. However, further long-term clinical studies with histological evaluation are necessary.

Keywords: modified bioglass ceramics, periodontal regeneration, periodontitis, intrabony defects.

РЕЗЮМЕ

БИОАКТИВНАЯ СТЕКЛОКЕРАМИЧЕСКАЯ КОМПОЗИЦИЯ В ХИРУРГИЧЕСКОЙ КОРРЕКЦИИ ПАРОДОНТАЛЬНЫХ ВНУТРИКОСТНЫХ КАРМАНОВ

Лысенко А.С., Борисенко А.В.

Национальный медицинский университет им. А.А. Богомольца, Киев, Украина

Ранее при инфицированных дефектах использовали новый костнопластический материал на основе биоактивной стеклокерамики, где в роли бактерицидных агентов выступали ионы серебра и меди.

Цель исследования - определение клинико-рентгенологической эффективности применения стеклокерамической композиции в качестве костно-замещающего материала в хирургическом лечении внутрикостных пародонтальных карманов.

В группе из 47 пациентов с генерализованным пародонитом проведено контролируемое клиническое исследование предложенной композиции. В качестве контроля использовалась бычья депротеинизированная кость (БДК) с коллагеновой мембраной 24 пациентов. Такие параметры как глубина пародонтальных карманов (ГПК), уровень клинического прикрепления (УКП), уровень рецессии десны, индекс раннего заживления раны (ИРЗР), гигиенические и гингивальные индексы, рентгенологическая плотность кости использованы для оценки результатов хирургического лечения.

Направленная тканевая регенерация выполнена в области 56 внутрикостных карманов. Спустя год после хирургического лечения определено существенное ($p < 0,05$) понижение ГПК на 53,5% в группе со стеклокерамической композицией (СКК) и на 45,7% в группе с БДК, повышение УКП на 30,4% в группе с СКК и на 28,0% в группе с БДК. Внутрикостные пародонтальные карманы заполнялись костной тканью на 27,5% и на 30,1%, соответственно, без существенного различия между группами сравнения. Однако, отмечено преимущество в значительном увеличении плотности кости в участках, пролеченных с помощью СКК ($p < 0,05$). В этой же группе отмечена тенденция к пониже-

нию уровня дискомфорта у пациентов и улучшению показателей заживления послеоперационных ран согласно ИРЗР.

Использование СКК в сочетании с коллагеновой мембраной ведет к существенной редукации глубины карманов, повышению уровня клинического прикрепления, нарастанию профиля плотности костной ткани. Однако, необходимо проведение долгосрочных клинических исследований с гистологическим подтверждением.

რეზიუმე

ბიოაქტიური მინაკერამიკის კომპოზიცია პარადონტალური ძვალში და ჯიბაკების ქირურგიულ კორექციის

აღისენკო, ა.ბორისენკო

ა.ბოგომოლცის სახ. ეროვნული სამედიცინო უნივერსიტეტი, კიევი, უკრაინა

ინფიცირებული დეფექტების შემთხვევაში ადრე შემოთავაზებული იყო ახალი ძვალპლასტიკური მასალა, დამზადებული ბიოაქტიური მინაკერამიკის საფუძველზე, სადაც ბაქტერიოციდური აგენტების როლს ასრულებდნენ ვერცხლის და სპილენძის იონები.

კვლევის მიზანს წარმოადგენდა ძვალში და ჯიბაკების ქირურგიული მკურნალობის დროს მინაკერამიკული კომპოზიციის ძვლის შემცველი მასალად გამოყენების კლინიკო-რენტგენოლოგიური ეფექტურობის შეფასება.

გენერალიზური პარადონტიტით დაავადებულ 47 პაციენტს ჩატარდა შემოთავაზებული კომპოზიციით მკურნალობის საკონტროლო-კლინიკური კვლევა. საკონტროლო მასალის სახით გამოყენებული იყო ხარის დეპროტეინიზირებული ძვალი (ხდმ) კოლაგენური მემბრანით (=24). ქირურგიული შედეგების შესაფასებლად გამოყენებული იყო შემდეგი პარამეტრები: პარადონტული ჯიბაკების სიღრმე (პჯს), კლინიკური მიმაგრების დონე (კმდ), ღრძილების რეცესიის დონე, ჭრილობის ადრეული შეხორცების ინდექსი (ჭაში), პიგიენური და გინგივალური ინდექსები, ძვლის რენტგენოლოგიური სიმკვრივე.

მიმართული ქსოვილური რეგენერაცია შესრულდა 56 ძვალში და ჯიბაკების არეში. ქირურგიული მკურნალობიდან ერთი წლის შემდეგ განისაზღვრა ჯგუფში პჯს არსებითი დაქვეითება 53,5%-ით ($p < 0,05$) მინაკერამიკულ ჯგუფში და 45,7%-ით საკონტროლო ჯგუფში, კმდ მომატება 30,4%-ით მინაკერამიკულ ჯგუფში და 28,0% - საკონტროლო ჯგუფში. შიდა ძვლის პარადონტული ჯიბაკები ივსებოდა ძვლის ქსოვილისგან 27,5%-ით და 30,1%-ით, შესაბამისად, უმნიშვნელო განსხვავებით. მინაკერამიკის მასალით მკურნალობის ჯგუფში ძვლის სიმკვრივე გაცილებით უფრო მეტი იყო, აღინიშნა ნაკლები დისკომფორტი და ჭაში-ის უფრო მაღალი მაჩვენებელი, ვიდრე საკონტროლო ჯგუფში.

კოლაგენურ მემბრანასთან შერწყმული მინაკერამიკული კომპოზიციის გამოყენება უზრუნველყოფს ჯიბაკების სიღრმის არსებით რედუქციას, კლინიკური მიმაგრების დონის ზრდას, ძვლის ქსოვილის პროფილის სიმკვრივის გამუჯობესებას. ავტორების აზრით, აუცილებელია კლინიკური კვლევების გაგრძელება პისტოლოგიური დადასტურებით.