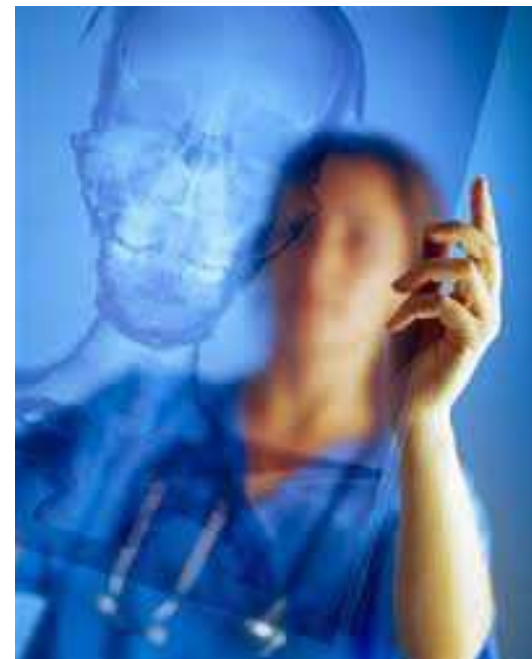

**Ministry of Health of Ukraine
Bohomolets National Medical University
Department of Forensic Medicine and Medical Law**

**N.M. ERHARD
A.M. BILYAKOV
B.V. MIKHAILICHENKO**

**MACROPREPARATIONS OF BODILY
INJURY FOR PRACTICAL TRAININGS
FROM FORENSIC MEDICINE**



Educational edition

**ERHARD Natalia Mykolaivna
BILIAKOV Andrii Nikolaevich
MIKHAILICHENKO Boris Valentinovich**

**MACROPREPARATIONS OF BODILY
INJURY FOR PRACTICAL TRAININGS
FROM FORENSIC MEDICINE**

Підписано до друку 21.05.2019
Формат 60×84. Папір офсетний.
Тираж 300 прим.

Видавництво УкрДГРІ
Р.с. серія ДК №182 від 18.09.2000 р.
04114, м. Київ-114, вул. Автозаводська, 78

Адреса редакції та п/п: інформаційно-видавничий відділ УкрДГРІ
04114, м. Київ-114, вул. Автозаводська, 78
Тел. 206-35-18; тел/факс 430-41-76

**Ministry of Health of Ukraine
Bohomolets National Medical University
Department of Forensic Medicine and Medical Law**



**MACROPREPARATIONS OF BODILY
INJURY FOR PRACTICAL TRAININGS
FROM FORENSIC MEDICINE**



Kyiv - 2019

Agreed and amended by the department of forensic medicine and medical law of Bohomolets National Medical University (Protocol № 20 from 21.05.2019).

N.M. Erhard, A.M. Biliakov, B.V. Mikhailichenko Macropreparations of bodily injury for practical trainings from forensic medicine. Kyiv, 2019. 32 p.

The proposed material is a collection of various types of bodily injuries caused by different traumatic objects.

Macropreparations are designed for students which to study practical skills and for their control on practical classes.

Macropreparations can be useful for medical professionals, law enforcement agencies, students, scientific and pedagogical staff of medical and legal educational institutions.

1. Концевич И.А. Судебно-медицинская диагностика странгуляций / И.А. Концевич. – К., 1968. – 156 с.
2. Пермяков А.В. Судебно-медицинская гистология: Руководство для врачей / А.В. Пермяков, В.И. Витер, Н.И. Невопин. – Ижевск-Екатеринбург: Экспертиза, 2003. – 214 с.
3. Витер В.И. Судебно-медицинская экспертиза механической асфиксии. Руководство для врачей / В.И. Витер, А.А. Матышев. – СПб. – Ижевск: Медицина, 1993. – 218 с.
4. Muller E. Thyroglobulin content of the blood in cases of hanging / E. Muller, C. Erfurt, W. G. Franke // Z. Rechtsmed. – 1990. – Vol. 103, N 5. – P. 361-367.
5. Диагностика различных видов смерти по состоянию путей микроциркуляции / Л.М. Бедрин, А.В. Шилин, В.С. Белов [и др.] // 3-й Всероссийский съезд судебных медиков: Материалы съезда. – Саратов, 1992. – Часть II. – С. 381-384.
6. Авдеев М.И. Судебно-медицинская экспертиза трупа: Руководство / М.И. Авдеев. – М., 1976. – 677 с.
7. Loubser J. D. Ophang as oorsaak van dood, die post mortem diagnose J. D. Loubser // S. A. J. Contin. Med. Educ. – 1986. – Vol. 4, N 12. – P. 45-48.
8. Cutaneous findings in congenital disorders of glycosylation: the hanging fat sign / J. A. Dyer, C. J. Winters, S. L. Chamlin // Pediatr. Dermatol. – 2005. – Vol. 22, N 5. – P. 457-460.
9. Raekallio J. Serotonini and histamine contents as vital reactions. II. Fu-topsy studies // J. Raekallio, P. L. Makinen // Zacehia. – 1970. – Vol. 45. – N 3. – P. 403-414.

List of Macropreparations

1. Femur bumper fracture.
2. Tibia bumper fracture.
3. Buttonhole skull fracture.
4. Depressed skull fracture caused by a blunt object with cylindrical surface.
5. Depressed skull fracture caused by a blunt object with edge (a stepped fracture).
6. Depressed skull fracture caused by a blunt object with spherical surface.
7. Depressed skull fracture caused by a blunt object with a flat limited surface.
8. Linear skull fracture caused by blunt object.
9. Comminuted skull fracture.
10. Contused skin wounds.
11. Superficial and deep cut of cranial vault (suicide).
12. Superficial cut of cranial vault (suicide).
13. Incised wounds (suicide).
14. Incised neck wounds (murder).
15. Incised palm wounds (self-defense).
16. Incised stab wounds (knife).
17. Incised stab and stab wounds (scissors).
18. Entrance hole on skull bones.
19. Exit hole on skull bones.
20. Entrance wound with a contact range.
21. Hydrodynamic bullets effect on the heart.
22. Bullet entrance wound due to the shot from a close range (rifled and hunter firearm).
23. Exit wounds of the skin.
24. Choking of airways with foreign subject in the breathing ways (larynx and trachea).
25. Hanging (strangulation mark).
26. Ligature strangulation (strangulation mark).
27. Drowning (Paltauf's sports).
28. Skin maceration.
29. Spots of Vishnevsky.
30. Poisoning by sulfuric acid.
31. Poisoning by nitric acid.
32. Beklar's and Zhuravlova's nucleus.
33. Electric mark.

Table of content

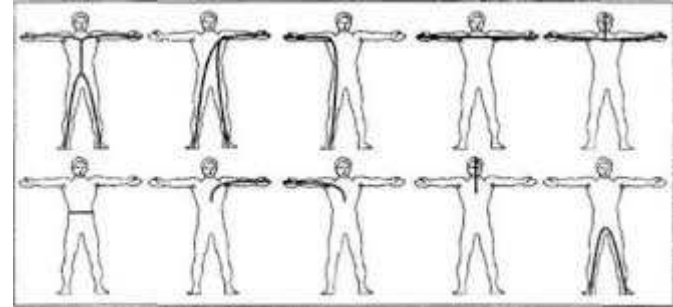
Foreword	4
I. Blunt objects injuries	5
II. Sharp objects injuries	10
III. Gunshot injuries	17
IV. Mechanical asphyxia	23
V. Injuries from low temperature effect	27
VI. Morphological signs of poisoning	27
VII. Fetal age definition	28
VIII. Electrical injuries	29
References	31

FOREWORD

During the investigation of criminal proceedings, the investigation has a question the solution of which related to medical and biological knowledges. The Forensic Medical Examination resolves these issues.

Concerning the existing legislation, if necessary, a doctor of any specialty may be involved for investigation for examination and description of the corpse on the disposal site. Therefore knowledge of morphological manifestations of damage is a compulsory skill for practicing doctors.

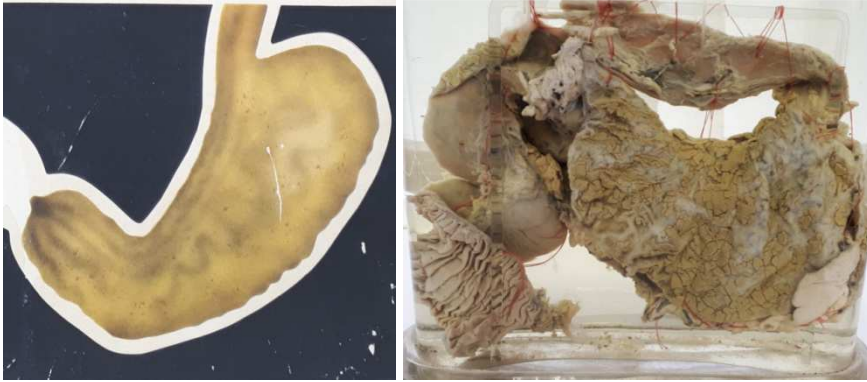
VIII. ELECTRICAL INJURIES



Standard current loops

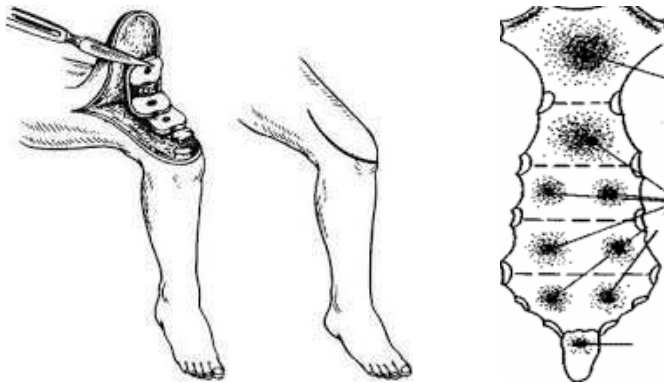


The electric mark at the place of the current input



Stomach: poisoning by nitric acid

VII. FETAL AGE DEFINITION

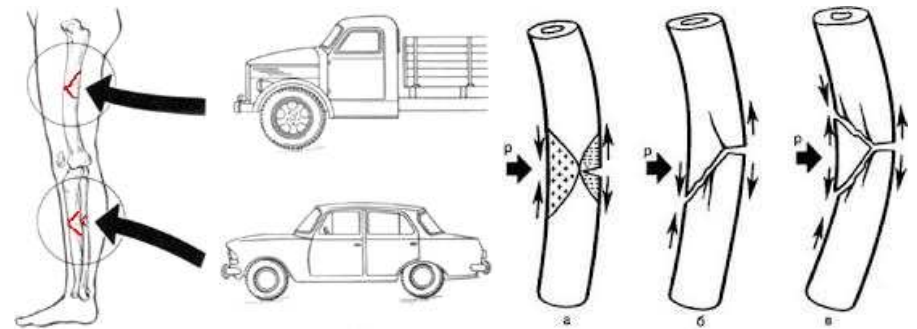


Beklar's and Zhuravlova 's nucleus

I. BLUNT OBJECTS INJURIES

1. Bumper fracture: femur and tibia bones.
2. A buttonhole skull fracture caused by a blunt object with a flat limited surface.
3. Depressed skull fracture caused by a blunt object with: edge, cylindrical surface, spherical surface, flat limited surface.
4. Linear skull fracture caused by a blunt object.
5. Comminuted fracture caused by a blunt object with a flat unlimited surface.
6. Contused skin wound caused by a blunt object.

1. Femur bumper-fracture and tibia bumper-fracture.



Femur bumper fracture



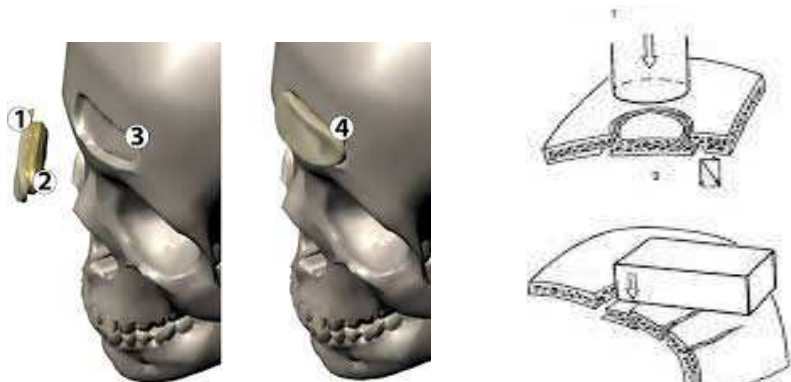
Tibia bumper fracture

2. A Buttonhole skull fracture caused by a blunt object with a flat limited surface

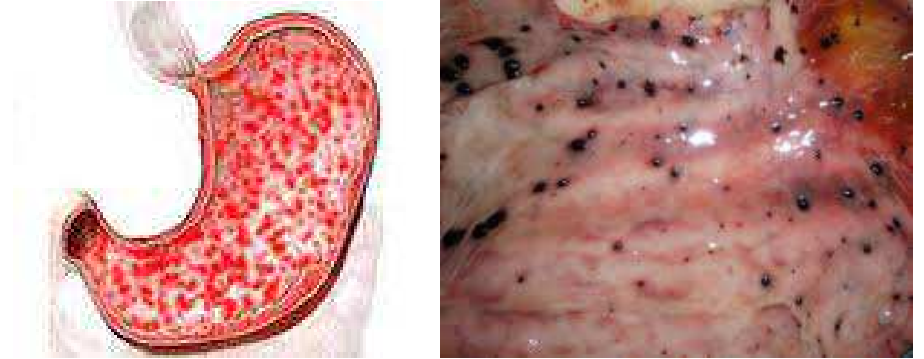

Buttonhole skull fracture

3. Depressed skull fracture caused by a blunt object with: edge, cylindrical surface, spherical surface, flat limited surface.

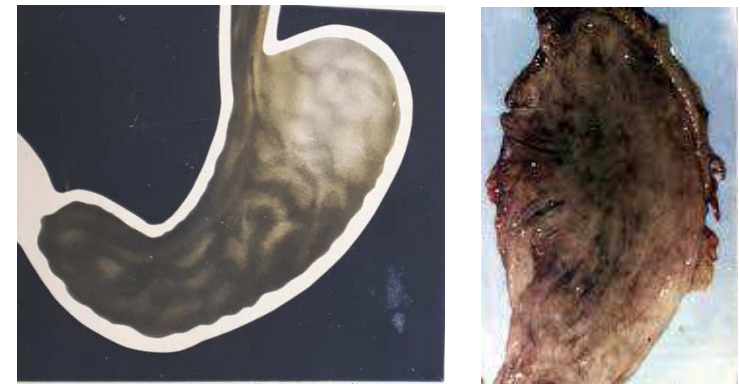

V. INJURIES FROM LOW TEMPERATURE EFFECT

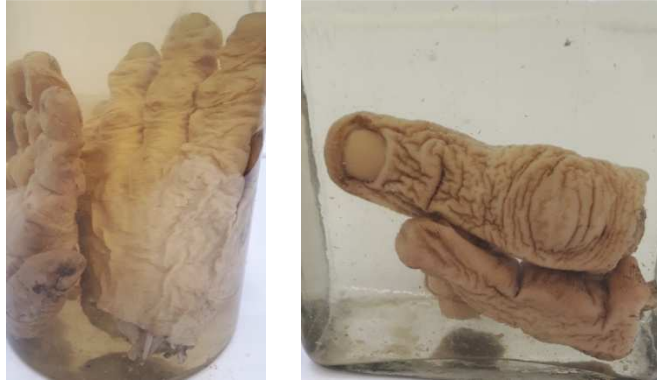

Spots of Vishnevsky - diagnostic sign of death from hypothermia

VI. MORPHOLOGICAL SIGNS OF POISONING



Stomach: poisoning by sulfuric acid



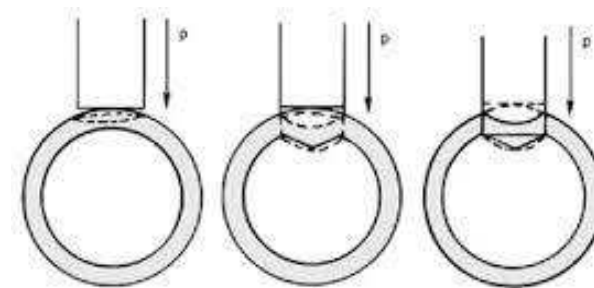
Skin maceration



Depressed skull fracture caused by a blunt object with cylindrical surface



Depressed skull fracture caused by a blunt object with edge (a stepped fracture)



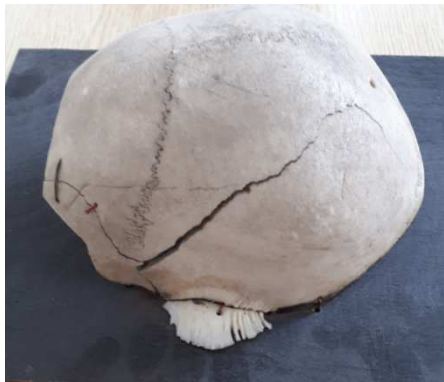

Depressed skull fracture caused by a blunt object with spherical surface.



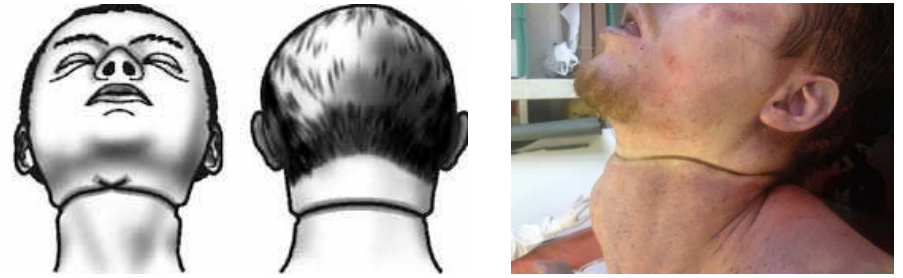Depressed skull fracture caused by a blunt object with a flat limited surface.

4. Linear skull fracture caused by blunt object



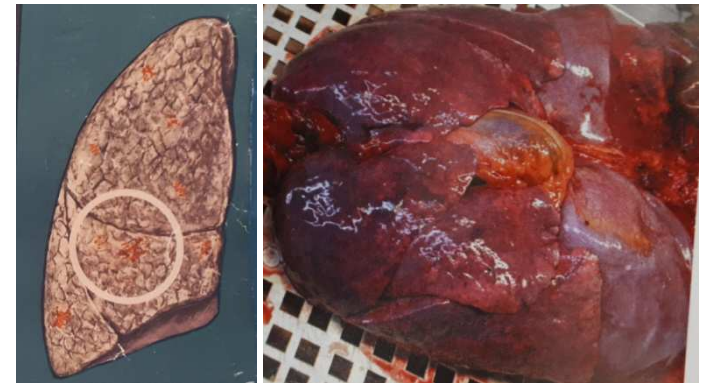Linear skull fracture

4. Ligature strangulation

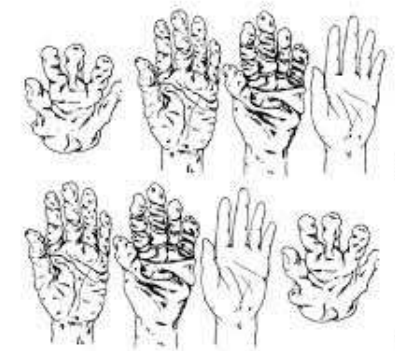


Strangulation mark

5. Drowning



Paltauf's spots on the lung surface



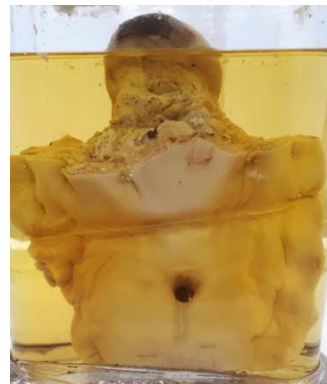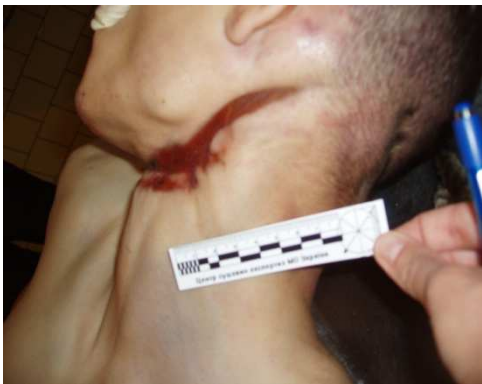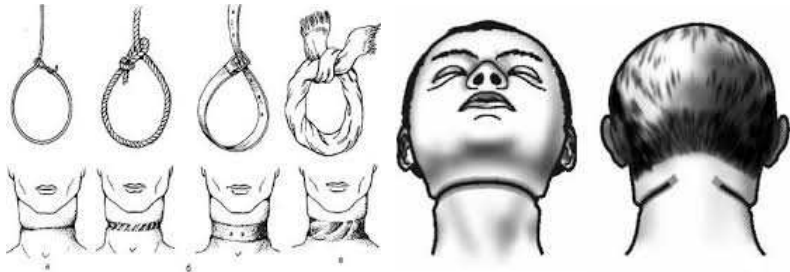
Skin maceration which indicating that the body stayed in water

2. Choking of airways with foreign subject in the trachea



Choking

3. Hanging



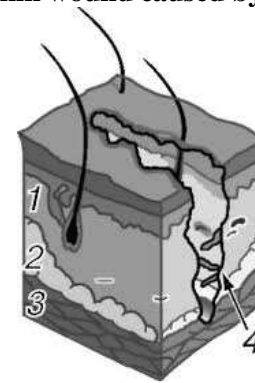
Strangulation mark

5. Comminuted fracture caused by a blunt object with a flat unlimited surface



Comminuted skull fracture (falling from height)

6. Contused skin wound caused by a blunt object.

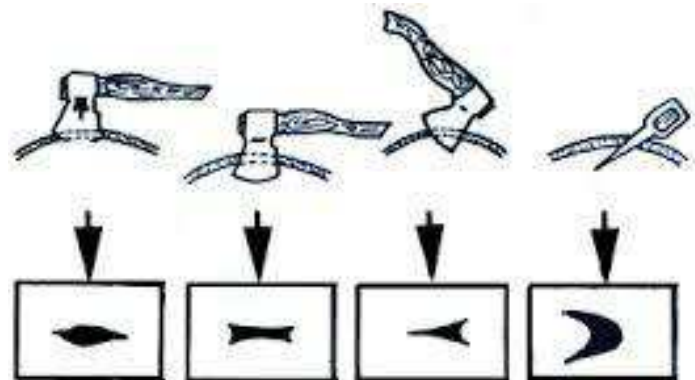


Contused skin wounds

II. SHARP OBJECTS TRAUMAS

1. Damage caused by chopping objects with superficial and deep cut (suicide).
2. Damage caused by chopping objects with superficial cut (suicide).
3. Incised wounds caused by a sharp cutting object (suicide).
4. Incised neck wound caused by a sharp cutting object (murder).
5. Incised palm wounds caused by a sharp cutting object (self-defense).
6. Incised stab wounds from the action of a sharp object with cutting and stabbing properties.

1. Cranial vault damage caused by a chopping objects with superficial and deep cut (suicide).

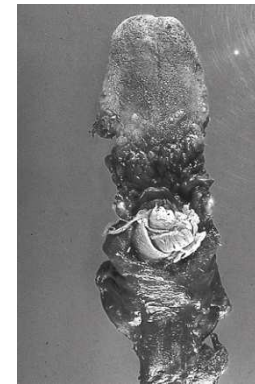


Superficial and deep cut of cranial vault (suicide)

IV. MECHANICAL ASPHYXIA

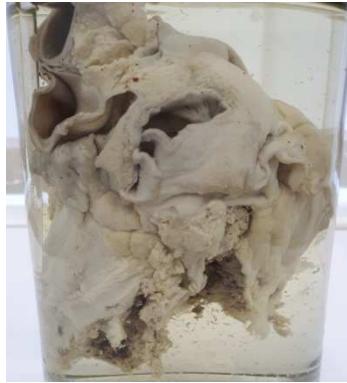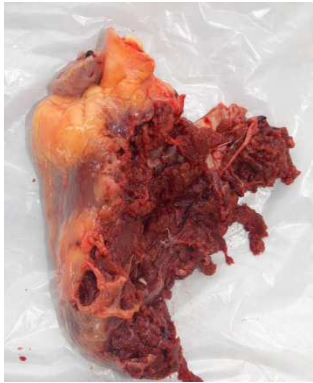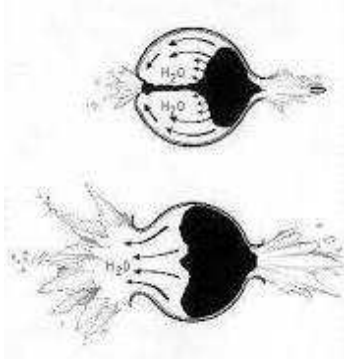
1. Choking of airways with foreign subject in the larynx.
2. Choking of airways with foreign subject in the trachea.
3. Hanging.
4. Ligature strangulation.
5. Drowning.

1. Choking of airways with foreign subject in the larynx



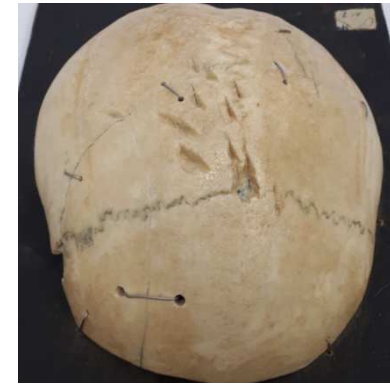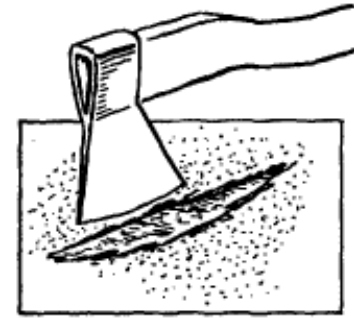
Choking

6. Hydrodynamic action of a bullet



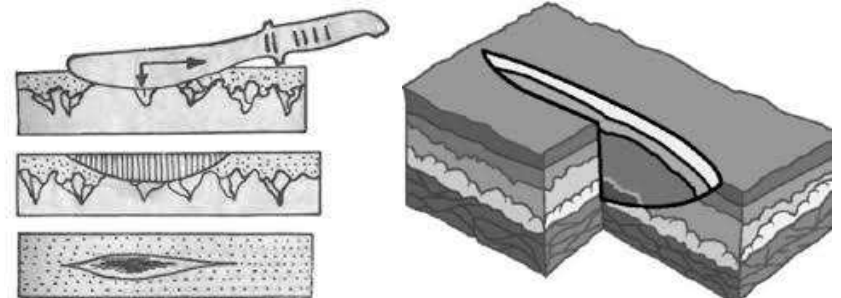
Hydrodynamic bullets effect on the heart

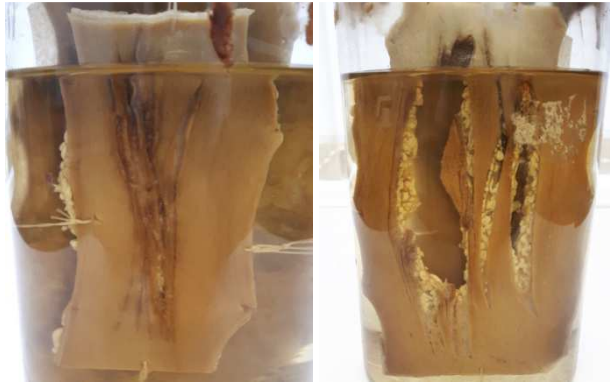2. Cranial vault damage caused by chopping objects with superficial cut (suicide)



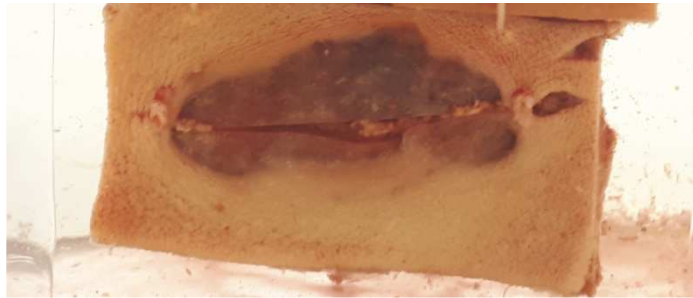
Superficial cut of cranial vault (suicide)

3. Incised wounds caused by a sharp cutting object



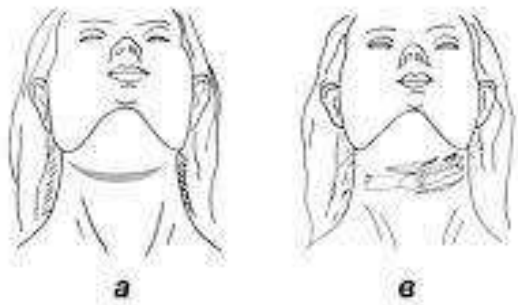


Incised wounds (suicide)

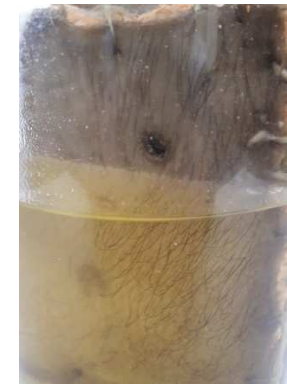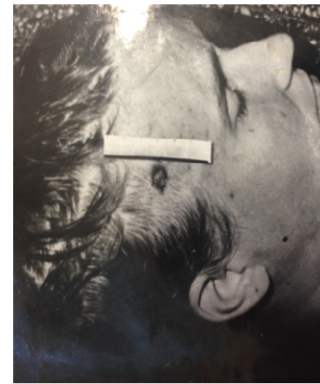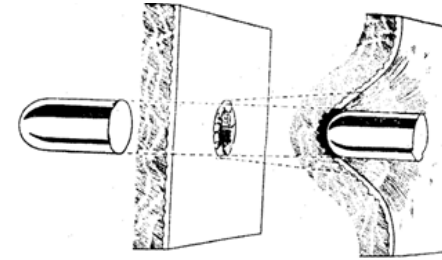


Incised wound

4. Incised wound caused by a sharp cutting object (murder).

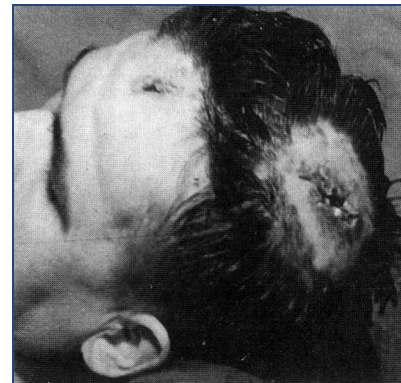


4. Bullet entrance wound due to the shot from a long range

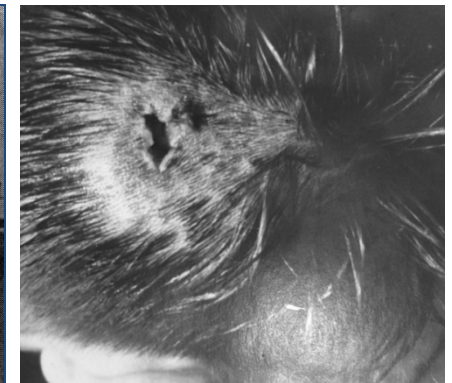

Entrance wound with a rifled firearm


5. Exit wounds of the skin



Entrance and Exit wound



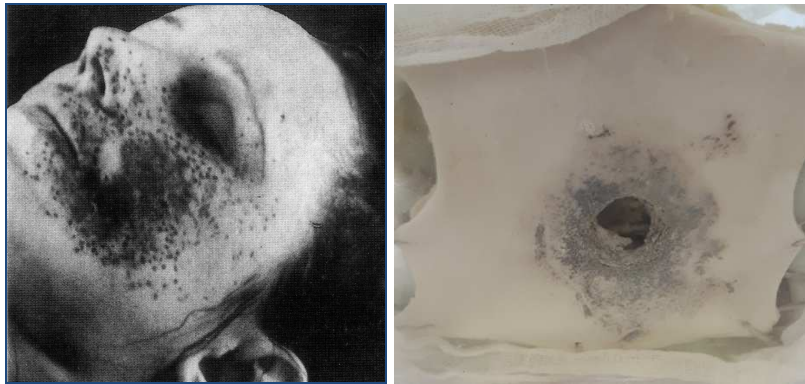Exit wound



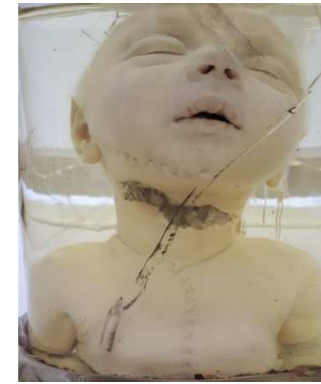Entrance wound with a rifled firearm



Incised neck wound (murder)



Entrance wound with a hunter firearm



Incised neck wound (murder)

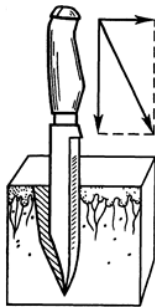
5. Incised palm wounds caused by a sharp cutting object (self-defense).





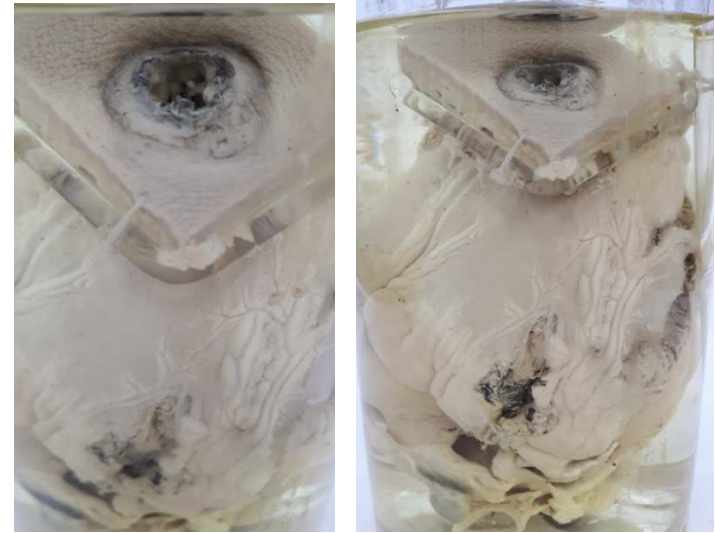Incised palm wounds (self-defense)

6. Incised stab wounds from the action of a sharp object with cutting and stabbing properties



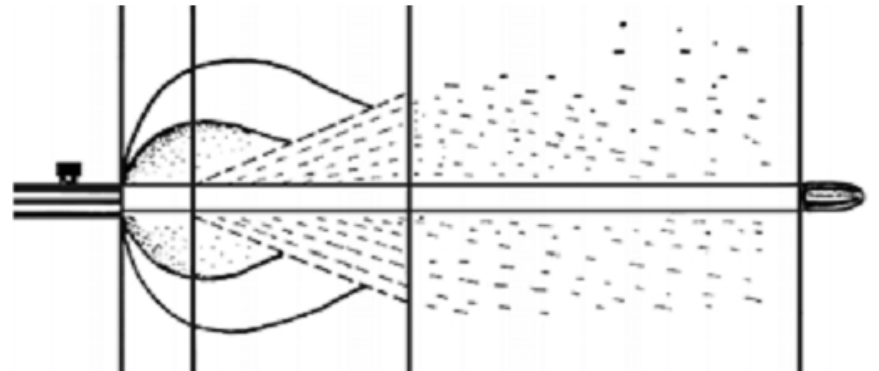
Incised stab wounds (knife)

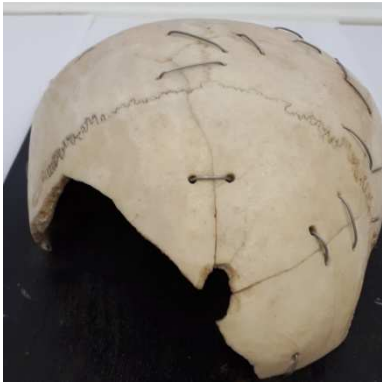
Entrance wound with a contact range



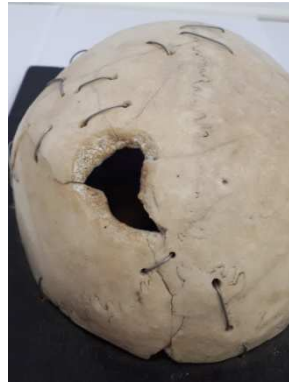Entrance wound with a contact range

3. Bullet entrance wound due to the shot from a close range

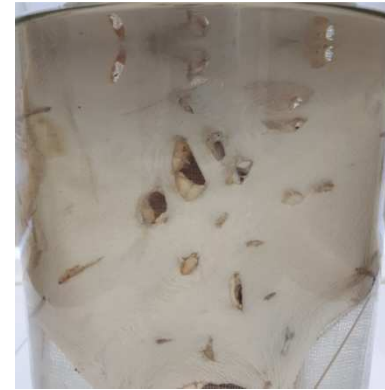



Entrance hole on skull bone

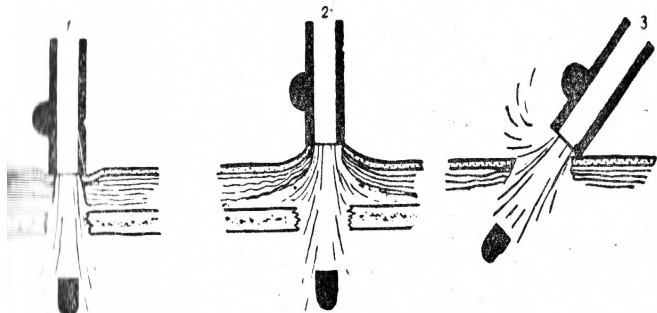


Exit hole on skull bones

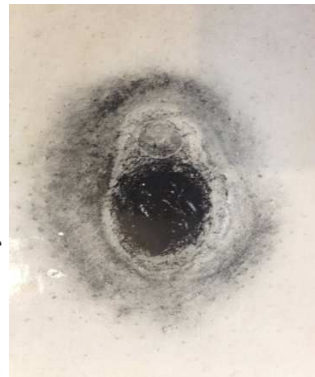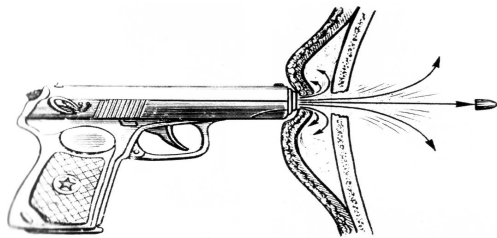


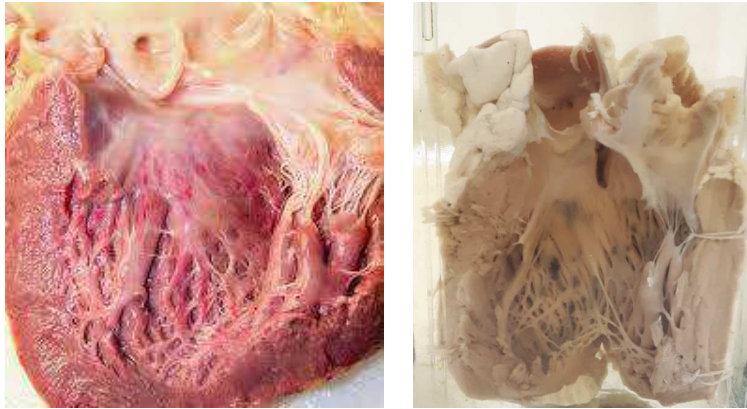
Incised stab and stab wounds (scissors)

2. Contact range.



Incised stab wound (knife)



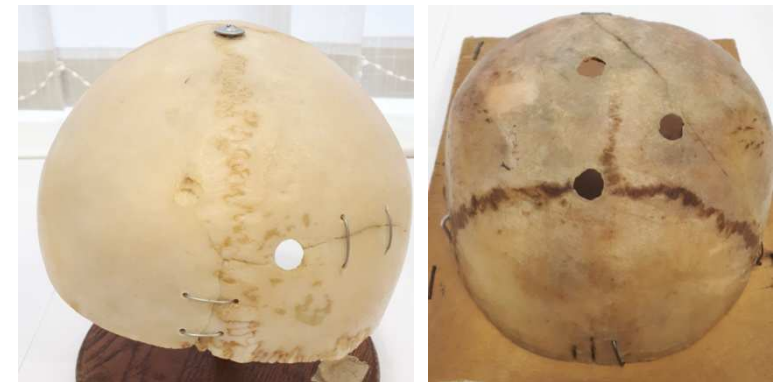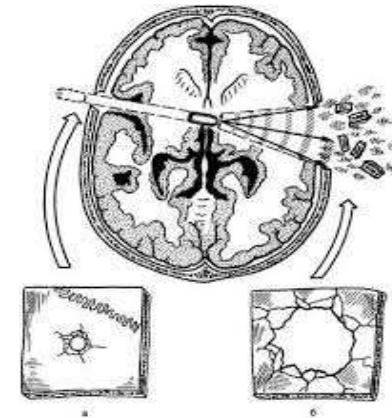


Minakov spots are a sign of acute blood loss

III. GUNSHOT INJURIES

1. Entrance and exit hole on skull bones.
2. Contact range.
3. Bullet entrance wound due to the shot from a close range
4. Bullet entrance wound due to the shot from a long range
5. Exit wound on the skin
6. Hydrodynamic action of a bullet.

1. Entrance and exit hole on skull bones



Entrance hole on skull bones