

NEW SURGICAL METHODS FOR TREATMENT OF UTERINE SUBSEROUS LEIOMYOMA**Benyuk V.***M.D., Professor**Head of the Department of Obstetrics and Gynecology №3**Bogomolets National Medical University**Kyiv, Ukraine***Shcherba E.***Ph. D., Assistant**Department of Obstetrics and Gynecology №3**Bogomolets National Medical University**Kyiv, Ukraine***Lastovetska L.***Ph. D., Associated professor**Department of Obstetrics and Gynecology №3**Bogomolets National Medical University**Kyiv, Ukraine***Maydannik I.***Ph. D., Associate professor**Department of Obstetrics and Gynecology №3**Bogomolets National Medical University**Kyiv, Ukraine***Shako V.***Intern**Department of Obstetrics and Gynecology №3**Bogomolets National Medical University**Kyiv, Ukraine***Vytyshchenko A.***Intern**Department of Obstetrics and Gynecology №3**Bogomolets National Medical University**Kyiv, Ukraine***НОВЫЕ ПОДХОДЫ К ОПЕРАТИВНОМУ ЛЕЧЕНИЮ СУБСЕРОЗНОЙ ЛЕЙОМИОМЫ
МАТКИ****Бенюк В.А.***доктор медицинских наук, профессор**заведующий кафедрой акушерства и гинекологии №3**Национальный медицинский университет имени А.А. Богомольца, Киев, Украина***Щерба Е.А.***кандидат медицинских наук, ассистент**кафедра акушерства и гинекологии №3**Национальный медицинский университет имени А.А. Богомольца Киев, Украина***Ластовецкая Л.Д.***кандидат медицинских наук, доцент**кафедра акушерства и гинекологии №3**Национальный медицинский университет имени А.А. Богомольца, Киев, Украина***Майданник И.В.***кандидат медицинских наук, доцент**кафедра акушерства и гинекологии №3**Национальный медицинский университет имени А.А. Богомольца, Киев, Украина***Шако В.А.***врач-интерн**кафедра акушерства и гинекологии №3**Национальный медицинский университет имени А.А. Богомольца, Киев, Украина***Витищенко А.С.***врач-интерн**кафедра акушерства и гинекологии №3**Национальный медицинский университет имени А.А. Богомольца**Киев, Украина*

Abstract

Leiomyoma of the uterus is a hormone-dependent benign tumor of the myometrium, which develops from muscular and connective tissue elements. At the present stage, up to 30-50% of women of reproductive age are observed with this pathology. Often there is an asymptomatic course. Leiomyoma of the uterus is a common cause of infertility, ectopic pregnancy, spontaneous abortion, premature birth. With the subserous localization of the neoplasm, its connection element can be easily twisted and torn off, which leads to severe pain with the development of the state of the acute abdomen.

To date, leiomyoma of the uterus is the main indication for performing a radical surgery in gynecology, including among 24-27% in patients of reproductive age. In this view, the minimally invasive operations are of increasing interest. The introduction of laparoscopic organ-preserving technologies in the treatment of uterine leiomyoma aims to preserve the reproductive function of patients and has shown promising results.

This paper reflects the features of the use of a self-locking thread during laparoscopic removal of the leiomatous node. Reduction of the time spent on suturing the uterine wall after its enucleation of the leiomatous node allows reducing the volume of blood loss during the operation.

The use of a self-locking thread during suturing the defect of the uterine wall after the performed myomectomy is of a great importance and can significantly affect the outcome of surgical treatment and therefore reduce the incidence of complications.

Аннотация

Лейомиома матки - гормонозависимая доброкачественная опухоль миометрия, которая развивается из мышечных и соединительнотканых элементов. На современном этапе наблюдается у 30-50% женщин репродуктивного возраста. Часто встречается бессимптомное ее течение. Лейомиома матки является причиной бесплодия, внематочной беременности, самопроизвольных аборт, преждевременных родов. При субсерозной локализации новообразования ножка может перекрутиться и оторваться, что приводит к появлению сильной боли с развитием картины острого живота.

На сегодняшний день лейомиома матки является основным показанием к выполнению радикальных операций в гинекологии, в том числе в 24-27% у пациенток репродуктивного возраста. В этом плане все больше интерес представляют малоинвазивные операции. Внедрение лапароскопических органосохраняющих технологий в лечении лейомиомы матки направлено на сохранение репродуктивной функции пациенток и имеет перспективные результаты.

В данной работе отражены особенности использования самофиксирующейся нити при лапароскопической операции удаления лейоматозного узла. Сокращение времени, затраченного на ушивание стенки матки после энуклеации лейоматозного узла, позволяет уменьшить объем кровопотери во время операции.

Использование самофиксирующейся нити при ушивании дефекта стенки матки после выполненной миомэктомии, имеет большое значение и может существенно повлиять на исход оперативного лечения, снизить частоту осложнений.

Keywords: uterine leiomyoma, surgical treatment, suture material.

Ключевые слова: лейомиома матки, оперативное лечение, шовный материал.

Leiomyoma of the uterus is the most common tumor of female genital organs and makes in 20-40% cases of gynecological morbidity of the structure [1, p. 33, 7, p. 56].

According to the published data, this pathology occur in 30-50% of women of reproductive age [1, p. 33, 3, p. 104].

Despite its benign nature, the disease does significant harm to the female reproductive health, leading to serious social and economic consequences - a decrease in the reproductive capacity, working ability and the quality of life [2, p. 57, 8, p. 20].

In order to determine a more accurate indicator of the occurrence of this disease now it is not possible because of its asymptomatic course in more than 70% of cases [10, p. 433, 15, p. 725].

The average age of patients with the detected uterine leiomyoma is 33 years. Surgical treatment of uterine leiomyoma is performed on average at the age of 44-45 years (most often it is hysterectomy). Taking into consideration the frequency of uterine leiomyoma, it is worth considering not only its dependence on age, but also on ethnic origin, as well as the patients' examining method [1, p. 34, 10, p. 433].

The risk factors for the development of uterine leiomyoma include:

- Late menarche, hyperpolymenorrhea;
- Disorders in the pituitary-ovary-uterus system;
- Inflammatory diseases of the genital organs;
- Medical abortion;
- Pronounced changes in hemodynamics of the pelvic organs;
- Dysfunction of the adrenal glands, thyroid gland (thyroid gland);
- Diseases of the cardiovascular system;
- Late onset of sexual activity and / or its irregularity;
- Genetic predisposition;
- Excessive emotional stress.

The problems of the hormonal status and functional state of the reproductive system take the key place in the pathogenesis of uterine leiomyoma [8, p. 20, 9, p. 359].

For a long time there was an opinion that hyperestrogonia plays an important role in the development of the uterus leiomyoma. However, according to numerous studies, it has been established that an increased es-

trogen content is not observed in all patients. The leading factor in the development of uterine fibroids are metabolic disorders of estrogens (the advantage of estrone and estradiol in the folliculin, and estriol - in the luteal phase of the cycle) and the functions of the yellow body. The development and growth of uterine leiomyoma are largely predetermined by the state of the receptor apparatus of the uterus. Specific proteins (receptors), when they are in contact with hormones, form a complex of estrogen-receptor or gestagen-receptor. Currently, specialists pay great attention to the stimulating effect of progesterone. Progesterone and progestins affect leiomyoma: first, they limit the response of the tissue to estrogen stimulation by reducing the amount of estrogen receptors; secondly, they by themselves can stimulate the proliferation process. The result may depend on the prevalence of one of the effects enlisted above [8, p. 20, 12, p. 2433, 15, p. 725].

The clinical manifestation of uterine leiomyoma depends on a number of factors, such as localization of this process, magnitude, morphological features, patient's age, concomitant genital and extragenital pathology [2, p. 57, 13, p. 530].

Leiomyoma of the uterus is capable of growth, regression and even a complete disappearance during menopause. However, the main symptoms of uterine leiomyoma are uterine bleeding, pain that can be localized, usually in the lower abdomen or in the lower back. With the subserous localization of the neoplasm, the connecting leg may be twisted and torn off, which leads to the appearance of severe pain and development of the acute abdomen state. When leiomyoma of the bladder or rectum is squeezed, frequent urination, constipation may occur [11, p. 43, 13, p. 530].

Leiomyoma of uterus is one of the causes of infertility, ectopic pregnancy, spontaneous abortion, premature birth. Leiomyoma affects not only the pregnancy but also the childbirth. Statistics say that every second pregnant woman has a prolonged delivery. In addition, if leiomyoma is present, there is an increased need for delivery with caesarean section. Although the leiomyoma as a rule does not represent a real risk for fetal birth, myomatous nodes (especially the large ones) are often combined with anomalies of the position and presentation of the fetus (transverse position, pelvic and facial lie), at which natural delivery is not possible. In patients with fibroids, placental abruption occurs more often (especially if the myoma is located behind the placenta - retroplacentally). Both early and late postpartum complications can be associated with the presence of leiomyoma. The early postpartum hemorrhages are associated with a decreased uterus tonus, tight attachment and increment of the placenta. The late postpartum hemorrhages are associated with the incomplete involution of the uterus (when the uterus is not reduced to the "original" size), infectious diseases [3, p. 104, 6, p. 37, 8, p. 20].

Modern classification of uterine leiomyoma according to ICD-10:

- D25 Leiomyoma of the uterus
- D25.0 Submucosal uterine leiomyoma
- D25.1 Intramural leiomyoma of the uterus
- D25.2 Subfertility leiomyoma of the uterus

D25.9 Uterine leiomyoma, unspecified

Classification of uterine leiomyoma by site localization:

- Intramuscular (intramural);
- Subsurface
- Submucous (submucous).

Atypical forms are distinguished for their localization: cervical, preexternal, retroperitoneal, suprapertoneal, paracervical, interconnected.

The growth of the node can be centripetal (in the middle), expansive (tissue bundle), eccentric (outward), intraligamentary (in sheets of broad ligament).

According to the tumor elements ratio the uterine leiomyoma is classified:

1. Fibromioma - the predominance of connective tissue (the ratio of muscle and connective tissue is 1:2-3).
2. Myoma - the ratio of muscle and connective tissue is 4-5:1

2.1. Leiomyoma is a tumor, which consists only of smooth muscle cells of myometrium.

2.2. Rhabdomyoma is a tumor that consists of transversely striated myometrium cells.

According to the morphological type and activity of proliferative processes, the uterine leiomyoma is classified:

1. Simple fibroid, that develops through benign muscle hyperplasia - slow growth and proliferative processes are not expressed.

2. Proliferating myoma, which possesses morphogenetic criteria of a true benign tumor - increased mitotic activity, rapid growth, no atypical myometrium cells.

3. Presarcoma is characterized by the presence of multiple elements with phenomena of atypia, heterogeneity of cell nuclei with large hyperchromic nuclei.

By the nature of growth and localization of nodes, the uterine leiomyoma is classified into:

- I. Diffuse growth of fibroids
- II. Nodular growth of fibroids:

1. Interstitial (intramural) arrangement of nodes - the tumor is located in the thickness of the muscular layer of the uterine wall.

2. Sub-serous (subperitoneal) arrangement of nodes - tumor growth occurs under the serous membrane of the uterus towards the abdominal cavity.

3. Submucosal (submucous) arrangement of nodes - the tumor grows towards the uterine cavity, deforming it.

4. Intraligamentary (interconnected) arrangement of nodes - tumor grows towards the parameter between the leaves of the broad ligament of the uterus.

Clinical and ultrasound classification of uterine leiomyoma (according to D. Wildemeersch, E. Schacht, 2001):

Type I - one or multiple small intramural nodes or subserosal nodes are present (less than 3 cm). Submucous nodes are absent.

Type II - one or multiple intramural or subserous nodes (3-6 cm) are present. Submucous nodes are absent.

Type III – one or multiple intramural or subserous nodes (greater than 6 cm) are present. Submucous nodes are absent.

Type IV – one or multiple intramural or subserous nodules are present. A proven submucosal node is under suspicion or present.

The modern method of diagnosing uterine leiomyoma include ultrasound of the pelvic organs, which allows to determine the size, amount, localization, echogenicity, the structure of the nodes, to identify the presence of concomitant hyperplasia of the endometrium. In severe cases, it is necessary to use an MRI that reveals all the varieties of myoma of the uterus, giving an exhaustive characterization, necessary for the optimal treatment [3, p. 104, 4, p.105, 15, p. 728].

Treatment of uterine leiomyoma is not an easy task, as despite hormonal dependence, it is extremely heterogeneous. Methods of treatment now are not unique, but they are widely used: conservative, surgical, and also minimally invasive methods [5, p. 22, 7, p. 56, 9, p. 359].

Despite the fact that conservative treatment is based on the effect of sex steroids on estrogen and progesterone receptors and consequently on the growth of leiomyoma. The main therapy choices are analogues of gonadotropin-releasing hormone (a-GnRH) and analogues of mifepristone. However, the possibility of conservative therapy of uterine leiomyoma is limited. The use of these therapy choices is limited to 6 months because of a negative impact on life quality of a woman, namely pronounced hypoestrogeny, a bone mineral density decrease [7, p. 57, 12, p. 2433].

Considering surgical methods of treatment of uterine leiomyoma, there are a number of indications for them:

1. Symptomatic leiomyoma:

- Hemorrhagic syndrome - profuse prolonged menstruation (menorrhagia) or acyclic bleeding (metrorrhagia);

- Pain syndrome;

- The presence of chronic anemia;

- Symptoms of compression of adjacent organs.

2. The size of the tumor, exceeding the size of the pregnant uterus of 13-14 weeks.

3. Presence of a submucous node (causes profuse bleeding, which leads to persistent anemia of the patient). Often the uterus does not reach large sizes, in some cases - only slightly increased. Urgent help is required while formation of a submucosal node.

4. Suspicion of node trophism - with aseptic necrosis, the infection can spread hematogenously or lymphogenically.

5. Presence of a subserous node of a leiomyoma on a pedicle (in connection with the possibility of node torsion).

6. Rapid growth (by an amount corresponding to 4-5 weeks of pregnancy per year and more, especially in the climacteric or in the menopausal period).

7. The presence of atypical forms of the location of the nodes of the leiomyoma. Intraligamentary localization causes the appearance of pain due to compression of the nerve plexuses and impaired renal function due to ureters' compression. The node location in the

neck, as a rule, leads to disruption of the function of adjacent organs.

8. Leiomyoma in combination with peridragular pathology of the endometrium or ovaries, ovulation or loss of the uterus.

9. Infertility or miscarriage of pregnancy due to uterine leiomyoma (it is necessary to exclude other factors that can cause this pathology, and accurately assess the nodes' location).

Classification of surgical treatment of uterine leiomyoma:

1. Conservative surgical treatment (organ-saving operations):

- a) Laparoscopic myomectomy;

- b) Hysteroscopic myomectomy;

- c) Laparotomy with myomectomy;

- d) Percutaneous and transcatheter embolization of uterine arteries.

2. Radical surgical treatment:

- a) Total hysterectomy (extirpation of the uterus):

- Laparoscopic;

- Transvaginal;

- Laparotomic.

- b) Subtotal hysterectomy (supravaginal amputation of the uterus):

- Laparoscopic;

- Transvaginal;

- Laparotomic.

An alternative treatment in the present time are minimally invasive operations, namely uterine artery embolization (UAE) and focused ultrasound ablation under MRI control. However, there are complications associated with premature ovarian exhaustion in the late period that limit the use of reproductive age in patients [14, p. 252].

The volume of surgical treatment in patients with uterine leiomyoma depends on the severity of clinical manifestations, as well as the desire to preserve reproductive function [2, p. 58, 5, p. 24].

To date, leiomyoma is the main indication for performing radical surgery in gynecology, including 24-27% in patients of reproductive age. At the same time, 80% of the hysterectomies are performed to treat the clinical manifestations of uterine leiomyoma. It is essential that hysterectomy is the final solution to the problem of leiomyoma of the uterus [1, p. 33, 2, p. 57, 13, p. 530].

In this regard, minimally invasive operations are of increasing interest. The introduction of laparoscopic organ-preserving technologies in the treatment of uterine leiomyoma aims to preserve the reproductive function of patients and shows promising results [5, p. 22, 13, p. 530].

Despite the current level of endoscopic surgery development, the choice of operative access is problematic due to in connection with the formation of an endoscopic suture for the defect of the uterine wall after enucleation of the node, which is the main goal of successful gestation.

The existing technical problems of stitching during laparoscopy at the site of a remote node are surgeon's experience and skills of surgical intervention that as a result can lead to uterine ruptures.

In this regard, deserves attention to the suturing of the lining, the edges of the uterus wall and despite the wide choice of suture material, surgeon's preference makes the final decision.

Now, the market presents two types of self-locking threads from different manufacturers, bidirectional and unidirectional.

Today self-locking yarns are a standard monofilament yarn with thin burrs along the entire length, spirally spaced in different directions, which ensures the reduction of the wound edges without tying of additional surgical knots.

The use of a self-locking thread during suturing the defect of the uterine wall after the performed myomectomy shows great importance and can significantly affect the outcome of surgical treatment and reduce the incidence of complications.

A self-locking unidirectional thread attracted our interest; the commercial name is V-Loc 180 (CovidienSurgical, USA). This is a relatively new absorbable suture material that is designed using unidirectional laser notches, which allows you to drag the thread through the tissues in only one direction. After tightening, the thread does not dissolve. This thread design allows covering the wound 50% faster than comparing to the conventional suture material.

Purpose of the study. To evaluate the effectiveness of the self-fixing V-Loc180 filament in laparoscopic treatment of subserous leiomyoma in women of reproductive age.

Materials and methods of research

We examined 60 women of reproductive age with a subserous leiomyoma of the uterus in the Kyiv City Maternity Hospital №3, on the basis of which a Department of Obstetrics and Gynecology № 3 of the Bogomolets National Medical University is located. All women had further reproductive plans, so we performed laparoscopic surgical removal of the node.

All patients underwent an organ-preserving operation of laparoscopic myomectomy. Depending on the suture used, two groups of the subjects were formed. In

the first group consisted of 30 patients suturing of the myometrium defect was carried out by a continuous multi-row intracorporal suture with a self-fixing unidirectional resorbable V-Loc180. Second group (comparison) group comprised 30 patients, who ligated the myomatous node bed with a continuous multi-row intracorporal suture through absorbable woven filaments.

Inclusion criteria were the age of patients (from 20 to 45 years), subserous localization of myomatous nodes with a distance to the uterine cavity of at least 5 mm (according to ultrasound), single uterine myoma with a node diameter of 5 to 8 cm, absence of concomitant gynecological pathology requiring expansion volume of operation, laparoscopic access to surgical treatment.

From the study, we excluded patients with the myomatous node less than 3 cm in diameter, with multiple uterine leiomyomas, previously hormonal therapy (gonadotropin-releasing hormone agonists, combined oral contraceptives, progestins), diagnosed neoplastic processes of any site, and additionally patients who had anesthesia contraindications.

Patients of both study groups were comparable in terms of anamnestic and clinical data; no statistically significant differences were detected ($p > 0.05$).

Examination before and after surgery included the use of physical, laboratory, instrumental research methods.

The statistical processing of the material was carried out using the standard package of programs "StatisticaforWindows" version 13.0, StatSoftInc (USA), following the recommendations for medical and biological research.

Results and discussion

The age structure of the subjects showed that the average age of the patients was $34,6 \pm 4,8$ years.

The main complaints presented by the examined patients with the subserous leiomyoma of the uterus were abdominal pain (66,7%), abnormal uterine bleeding (26,7%), infertility (18,3%) [Fig. 1].

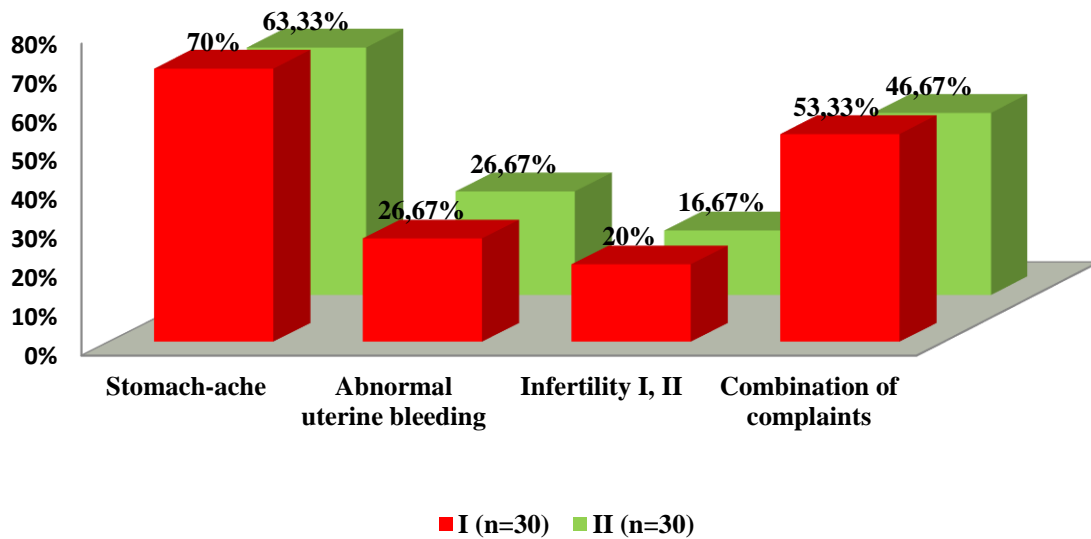


Fig.1 Complaints of the examined patients with a subserous leiomyoma of the uterus (percentage).

Analysis of menstrual function showed that in most patients, the menstrual cycle was regular (81,7%),

but menstrual dysfunction was observed such as soreness (43,3%), abundant (31,6%) [Fig. 2].

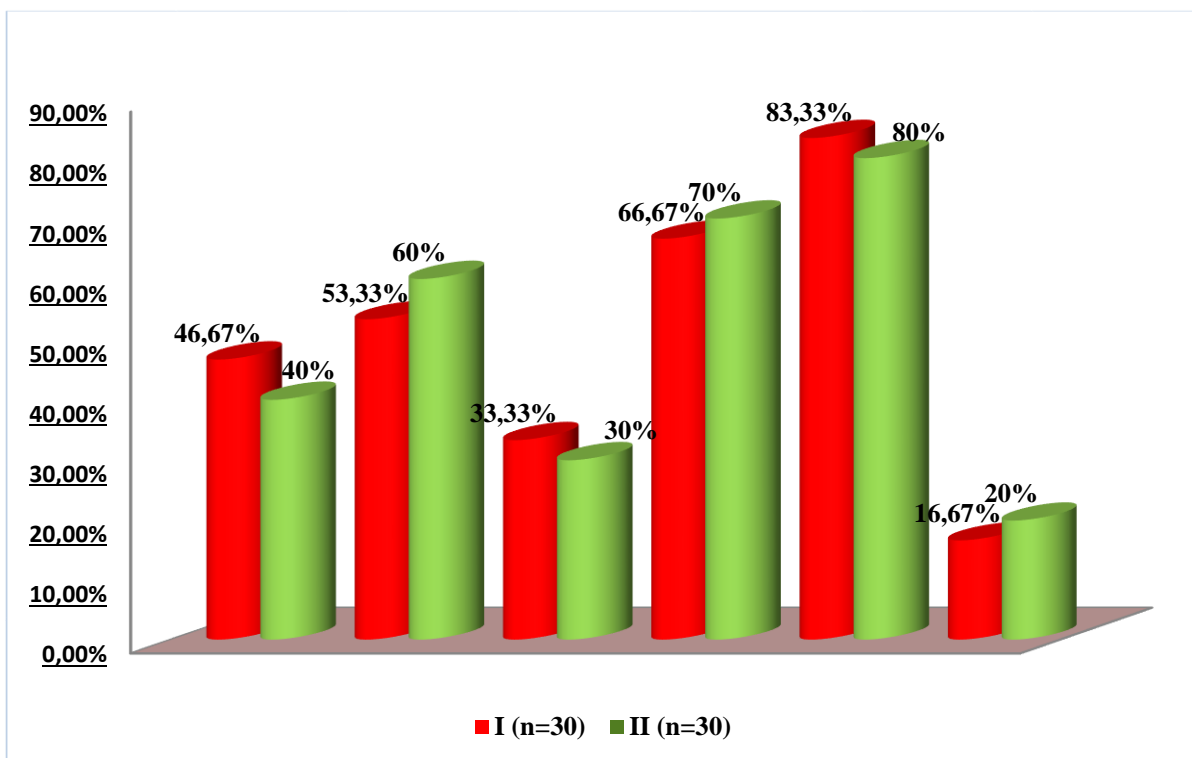


Fig.2 Characteristics of the menstrual function of patients with subserous leiomyoma of the uterus (percentage).

Among the most common gynecological diseases, the most typical were pelvic inflammatory disease (43,34%), cervical disease (23,34%), and endometrial pathology (20%).

Extragenital diseases accounted for a large proportion of diseases of the urinary system (25%), as well as

of the gastrointestinal tract and hepatobiliary system (20%).

A study of the reproductive history of the subjects showed that 81,7% of the patients had pregnancy and childbirth. However, a high percentage of artificial

abortions is established (46,7%). Spontaneous abortions were observed in 6,7%, ectopic pregnancy - in 3,4% of cases.

All patients were referred to routine surgical treatment, which was performed in the volume of laparoscopic myomectomy.

Estimating the time of suturing of the uterine wall after removal of the node, we managed a 2-fold reduction in the patients of group I of the survey who used a self-fixing unidirectional resorbable V-Loc 180 strain comparing with the women from the group II [Fig. 3].

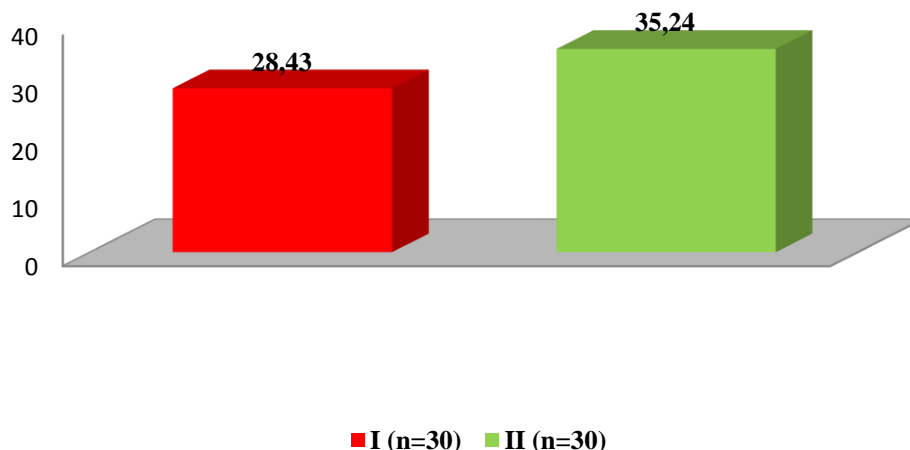


Fig.3 Uterine wall suturing time among examined women with subserous leiomyoma of the uterus (min).

The study of the volume of intraoperative blood loss showed a 1,5-fold decrease in the patients of the first (main) group, which in these patients averaged 150 ml in comparison with the patients of the second group (comparison), which averaged 250 ml.

The conducted study of the hemoglobin level of blood 24-48 hours after the operative treatment in the comparison groups was different.

Analysis of the number of erythrocytes in the peripheral blood before and after surgery showed that the blood hemoglobin level in patients in group II was significantly lower in the postoperative period (2,5 times) than in group I (primary). In addition, we found a 2-fold decrease in the level of erythrocytes in patients of group II, in comparison with group I ($p < 0,01$) [Fig. 4].

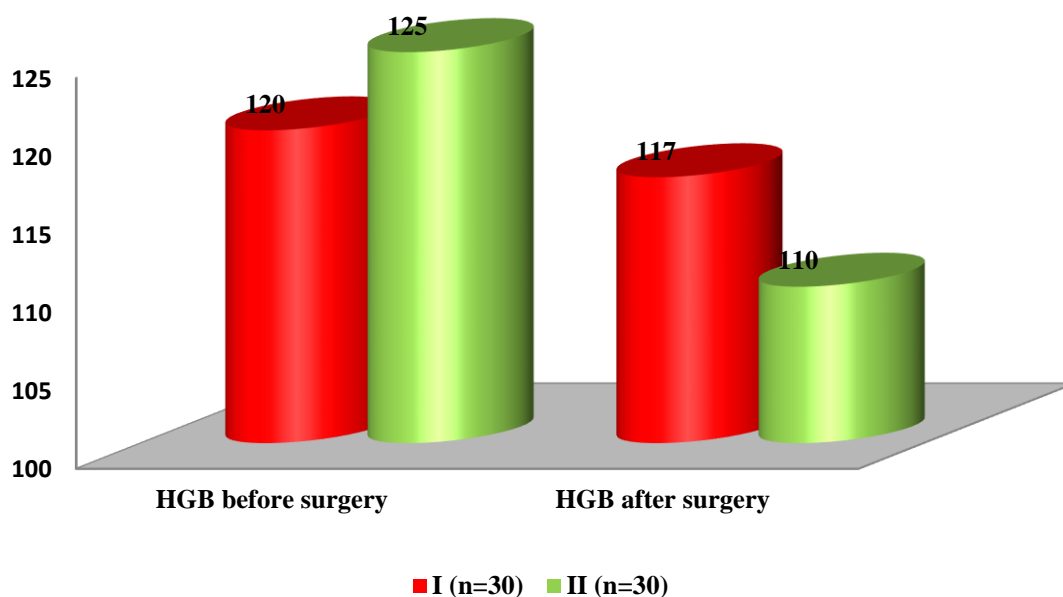


Fig.4 The level of hemoglobin HGB of the examined women with the subserous leiomyoma of the uterus (g/l).

The closest postoperative period in all patients, regardless of the type of suture used, during laparoscopic myomectomy proceeded without any peculiarities, according to the time and severity of the surgery. Complications for the period of observation in the hospital were not found, which allowed dismissing them in a satisfactory condition at the recommended time.

The rehabilitation period did not differ in patients both in the main and in the comparison group.

Conclusions:

The use of a unidirectional self-locking thread V-Loc 180 when lining the uterine wall during laparoscopic myomectomy showed promising results, which is confirmed by hemostatic indices, shortening of the knot bed site, and the absence of complications during the operation and in the postoperative period.

REFERENCES:

1. Benyuk V.A. Ways to improve care for patients with gynecological operations leiomyoma of the uterus in the outpatient stage / V.A. Benyuk ., I.V. Vinyarsky, V.M. Hancharenka // Tavrishesky medical-biological paper - 2011. - V. 14, № 3, 2 h (55). - S. 33-36.
2. Boyko V.I. Differentiated approach to surgical treatment of large uterine fibroids / V.I. Boyko, V.A. Terekhov // - K.: Women's Health. - 2016. - №7. - with. 57-61.
3. Gladchuk I.Z. Reproductive effects in women who have undergone conservative myometectomy / I.Z. Gladchuk, O.J. Nazarenko // - K.: Reproductive health in women. - 2005. - Volume 3 (23). - S. 104-106.
4. Lyanna M.V. Actual issues of preconceptional preparation of women with leiomyoma and pathology of the cervix in anamnesis / M.V. Lyanna // - K.: Women's Health. - 2013. - №5. - S. 105-106.
5. Medvedev M.V. Algorithms of organ-preserving treatment of leiomyoma of the uterus / M.V. Medvedev / - K.: Caring about Women, №6, 2011. - S. 22-26.
6. Nazarenko L.G. Current insights on the problem of non-pregnancy/ L.G. Nazarenko // - K.: Woman's doctor. - 2013. - № 1 (45). - S. 36-42.
7. Tatarchuk T.F. Uterine fibroids and reproductive function of women: a critical assessment of therapeutic approaches. / T.F. Tatarchuk, N.V. Cossey, T.N. Tutchenko / - K.: Reproductive Endocrinology №1, 2011. - p. 56-59.
8. Chayka K.V. Current concepts of etiology, pathogenesis and morphogenesis of leiomyoma of the uterus // Medical and social problems of the family. - 2012. - V. 17, № 1. - pp. 20-26.
9. Berek Jonathan S. Novak's Gynecology / Berek Jonathan S. - New York. - 2014. - P. 359-361.
10. Buttram V.C. Uterine leiomyomata: aetiology, symptomatology, and management / V.C. Buttram, R. Reiter // Fertil Steril. - 2011. - № 36. - P. 433-443.
11. Foissac R. Torsion of a huge pedunculated uterine leiomyoma / R. Foissac, N. Sautot-Vial, I. Birtwistle // Am. J. Surg. - 2015. - Vol. 201. - P. 43-45.
12. Ishikawa H., Ishi K., Serna V.A. et al. Progesterone is essential for maintenance and growth of uterine leiomyoma // Endocrinology. - 2010. - V. 151. - P. 2433
13. Ohtani T. Resolution of a leg ulcer after hysterectomy for huge uterine myoma/ T. Ohtani, M. Tanita, H. Tagami // J. Dermatol. / 2013. - Vol.30. - P. 530-532.
14. Vo N.-J., M.D., Torrance A.R. Uterine Artery Embolization: A Safe and Effective, Minimally Invasive, Uterine-Sparing Treatment Option for Symptomatic Fibroids // Semin Intervent Radiol. 2008. V. 25 (3): 252-260.
15. William H. Parker, M.D. Etiology, symptomatology, and diagnosis of uterine myomas // American Society for Reproductive Medicine Fertil Steril. - 2013. - Vol. 87. - P.725-736.