

TABLE OF CONTENTS

RESEARCH ARTICLES

Caused by Kozyavkin® method changes in hand function parameters in children with spastic form of cerebral palsy and their EEGs, HRVs and GDVs accompaniments O V Kozyavkina, N V Kozyavkina, T B Voloshyn, M S Hordiyevych, V I Lysovych, V Y Babelyuk, H I Dubkova, T A Korolyshyn, I R Mysula, D V Popovych, W Zukow, I L Popovych	PDF 11-30
Evaluation of athletic club training management fostered by youth and sports department, Aceh province, Indonesia Ziknur Rahmat, Irfandi Irfandi, Abdullah Al Hazmy, Sapta Kunta Purnama, Agus Kristiyanto	PDF 62-76
Cosmeometric features in atopic dermatitis under the conditions of filaggrin dyamorphism in children O. V. Reshetilo	PDF 117-124
Simultaneous myomectomy during surgical delivery D. M. Zhelezov, O. S. Salekh	PDF 125-130
Effectiveness of the therapeutic-prophylactic complex in patients with bronchial asthma against the background of excessive body weight or obesity D. O. Lagoda	PDF 131-140
Comparison of the subjective assessment of severity of pain during labor in various methods of pharmacological analgesia Michał Michalczyk, Dorota Torbé, Andrzej Torbé	PDF 141-148
Comparison of scoliosis posture athlete's table tennis and tennis at children and adolescents Muhammad Satria Purnama, Muchsin Doewes, Sapta Kunta Purnama	PDF 149-162
Changes in electrokinetic index of buccal epithelium correlated with changes in some parameters of immunity and fecal microbiocenosis Iryna G Kyrylenko, Igor-Severyn S Flyunt, Vitalii M Fil', Walery Zukow, Igor L Popovych	PDF 168-174
Predictors of injuries among young players team games Jarosław Domaradzki, Sebastian Chmielewski, Izabela Barbara Trojanowska, Dawid Koźlenia	PDF 175-189
Dragon Fruit Giving Effect Against Malondealdehyde (MDA) Levels in Muay Thai Athletes With High Intensity Interval Training (HIIT) Method Abdul Latif Rahman Hakim, Rachmah Laksmi Ambardini, Wildan Alfia Nugroho, Erick Burhaein	PDF 190-198
The influence of vestibular load on the heart vessel system of high qualification fencer V. A. Pastuhova, N. L. Andreyuk	PDF 199-208
Bile production features in case of ischemic-reperfusion syndrome of limbs, abdominal trauma complicated with massive blood loss I. V. Kuzminsky, V. O. Krylyuk, M. A. Maksymenko	PDF 209-218
Variants and factors of catatonic syndrome pathomorphosis in the structure of endogenous catatonia D. M. Safonov	PDF 219-226
Analysis of step kinematics during maximum speed of 60 m sprint performance Rafał Omelko, Marek Fostiak, Krzysztof Mackala	PDF 227-235
Dynamic of indices of lipid peroxidation and antioxidant protection in muscular tissue and blood serum of rats with acute ischemia-reperfusion A. T. Televiak, T. O. Veresiuk, P. R. Selsky, A. S. Volska, K. I. Kurylo, Z. M. Nebesna, T. V. Datsko, I. I. Boymystruk	PDF 245-255
The use of autologous bone grafts and xenogenic bone materials for reconstruction of the facial bone defects (randomized prospective study) V. A. Rybak, T. A. Pavlychuk, A. V. Kopchak	PDF 256-272
General characteristics of morphometric parameters nerve structures of the tentorium cerebelli S. S. Malakhov	PDF 273-284
Effect of elevated levels of uric acid on thrombocyte hemostasis in patients with hypertonic disease of stage II Maria Valigura	PDF 285-293
State of plasma hemostasis in patients with hypertension in combination with non-alcoholic fatty liver disease N. Bazhenova	PDF 294-303
Distribution of "model" congenital malformations in children whose mothers used to live in the environmentally unfavorable areas Olena Vlasova, Iryna Lastivka	PDF 304-311
Prognostic value of CD3, CD4, CD8 and CD 68 in high-grade diffuse astrocytomas, the transformation of an immune profile in recurrent tumors Taisia Chertenko, Irina Yakovtsova	PDF 312-325
Circadian rhythm of metabolism indicators in healthy people according to saliva study findings Yu. M. Hryshko, T. V. Gorbach, A. I. Gozhenko	PDF 338-346
Efficiency of adaptation to hypoxic hypoxia in a course of artificial climatotherapy in correction of the hormonal status at thyroid gland hypofunction at children Maria Radziejowska	PDF 347-356
The hypotyesis in patients with chronic obstructive pulmonary disease (COPD) N. A. Matsegora, O. E. Shpota	PDF 357-362
The swine intestinal wall thickening dynamic in result of different pressure applying inside the welding anastomotic instrument model S. S. Podpriatov, S. E. Podpriatov, G. S. Marinsky, V. A. Tkachenko, V. G. Hetman, K. G. Lopatkina	PDF 363-374

Rybak V. A., Pavlychuk T. A., Kopchak A. V. The use of autologous bone grafts and xenogenic bone materials for reconstruction of the facial bone defects (randomized prospective study). Journal of Education, Health and Sport. 2018;8(10):256-272. eISSN 2391-8306. DOI <http://dx.doi.org/10.5281/zenodo.1478147>  
<http://ojs.ukw.edu.pl/index.php/johs/article/view/6277>

The journal has had 7 points in Ministry of Science and Higher Education parametric evaluation. Part b item 1223 (26/01/2017).  
1223 Journal of Education, Health and Sport eISSN 2391-8306 7

© The Author(s) 2018;

This article is published with open access at Licensee Open Journal Systems of Kazimierz Wielki University in Bydgoszcz, Poland

Open Access. This article is distributed under the terms of the Creative Commons Attribution Noncommercial License which permits any noncommercial use, distribution, and reproduction in any medium, provided the original author (s) and source are credited. This is an open access article licensed under the terms of the Creative Commons Attribution Non commercial license (<http://creativecommons.org/licenses/by-nc/4.0/>) which permits unrestricted, non commercial use, distribution and reproduction in any medium, provided the work is properly cited.

This is an open access article licensed under the terms of the Creative Commons Attribution Non commercial License (<http://creativecommons.org/licenses/by-nc/4.0/>) which permits unrestricted, non commercial use, distribution and reproduction in any medium, provided the work is properly cited.

The authors declare that there is no conflict of interests regarding the publication of this paper.

Received: 02.10.2018. Revised: 19.10.2018. Accepted: 31.10.2018.

## **THE USE OF AUTOLOGOUS BONE GRAFTS AND XENOGENIC BONE MATERIALS FOR RECONSTRUCTION OF THE FACIAL BONE DEFECTS (RANDOMIZED PROSPECTIVE STUDY)**

**V. A. Rybak <sup>1</sup>, T. A. Pavlychuk <sup>2</sup>, A. V. Kopchak <sup>2</sup>**

**<sup>1</sup>Centre of Maxillofacial Surgery and Stomatology, Kyiv Regional Clinical Hospital, Ukraine;**

**<sup>2</sup>Department of Stomatology, Institute of Postgraduate Education, Bogomolets National Medical University, Ukraine**

### **Abstract**

The objective - to compare the efficacy of surgical interventions to replace jaw defects with the use of different types of bone grafts based on objective clinical and radiological criteria. The study included 90 patients with postoperative jaws defects. They underwent reconstructive operation for creating conditions for further prosthetic rehabilitation. The patients were divided into 3 randomized groups, depending on the surgical treatment used: group I - xenogenic bone substitutes were used, group II - autologous corticocancellous bone grafts from the iliac crest and in group III autograft combined with PRGF. Patients' status was assessed in the early (up to 1 month) and long-term postoperative period (more than 6 months). In the study series, xenogenic materials showed the highest volumetric stability in the remote postoperative period ( $19,9 \pm 8,1\%$  versus  $45.6 \pm 21.84\%$  for bone autografts). However, autologous grafts demonstrated better integration and quality of bone tissue. There were no significant differences in frequency of postoperative complications or the possibility of implant placement in the study groups. The use of PRGF in combination with autograft accelerated the regeneration of soft tissues, but it does not affect significantly the incidence of

infection complications and volume loss of the bone grafts.

**Key words:** autologous bone grafts, xenografts, PRP, PRGF, bone volume and density

**Background.** Reconstruction of the jaw defects caused by congenital pathology, chronic inflammatory processes, traumatic injuries and surgical interventions for tumours and tumour-like lesions is a complex challenge in maxillofacial surgery [1, 2]. Extensive bone defects (critical size defects) fail to heal spontaneously; therefore, the main method of their treatment is the replacement with bone grafts or synthetic bone substitutes with various physical, mechanical and biological properties[3, 4]. The main options for bone replacement widely used in clinical practice include auto-, allo-and xenografts. Their biological behaviour, advantages and disadvantages depend on the origin, physical and mechanical properties, chemical composition, architectonics and microstructure [5-7].

In management of the facial bone defects, the use of free bone autografts is considered as a ‘gold standard’ by many authors [7, 8, 11]. The autologous bone provides the biologically active proteins, growth factors and viable osteogenic cells to the recipient site, which significantly increases the efficacy of the bone grafting procedures. Autologous bone grafts are characterized by high biocompatibility, regenerative potential, osteoinductive properties, minimal risk of allergic or immune responses, resistance to infections, and the capability of adaptive remodeling unfavorable clinical and biological conditions [8, 9]. Despite the obvious advantages, autografts have a number of drawbacks, involving among others an increase in the duration and complexity of surgical interventions, the risk of complications in the donor site and the limited volume of bone tissue, especially when the graft is harvested from intraoral sites, as well as the volume loss and resorption of autografts during regeneration and bone remodelling in the defect area [12]. According to the literature, the degree of resorption can range from 12 to 85%. [13-15]

In order to reduce the invasiveness of bone grafting procedures and increase their predictability, xenomaterials have gained widespread use [10, 16-19]. They are applied independently or in combination with autologous bone [20]. Xenografts are represented by natural hydroxyapatite or deproteinized bone which have good osteoconductive properties and high biocompatibility. The microstructure of xenogeneic materials corresponds to the natural three-dimensional structure of the human bone and thus it ensures rapid vascular invasion in transplantation sites, migration and fixation of osteogenic cells on the material surface, acting as a matrix for building new bone structures [10]. In the process of reparative regeneration

and bone remodelling, the bone substitutive material is gradually absorbed and replaced by the newly formed bone tissue. [16-18]

A number of experimental studies and randomized clinical trials have shown the clinical efficiency of xenomaterials [16-19]. The resorption of xenomaterials is lower than that of autotransplants however, their remodelling takes a long time, and the resulting bone tissue can substantially differ from the intact bone in structure, biological, physical and mechanical properties [10, 21]. During reparative regeneration, complex tissue structures arise at the defect site. They contain bone areas with different architectonics and mineral density, pores, zones of the connective tissue growth and residual parts of the material undergoing structural degradation. Histological studies show that the residual material particles can be present in bone regenerate even 10 years after surgery [22]. The fragility and possibility of material migration further affects the biomechanical properties of the bone in the transplantation site and the functional outcomes of the surgical intervention. In addition, unlike bone autografts, xenomaterials do not have osteoinductive or osteogenic properties [10]. Therefore, in cases where osteogenic potential and blood supply of the recipient site are compromised, authors recommend to give preference to autografts and reparative medicine techniques, in particular, application of the stem cells and growth factors in order to optimize the regeneration process in the bone grafting area [23]. In recent years, the combination of grafts with platelet concentrates (PRP) has been used to fill the jaw defects [24]. Autologous growth factors contained in platelet alpha granules, in particular the transforming growth factor-beta (TGF- $\beta$ ), vascular endothelial growth factor (VEGF), platelet-derived growth factor (PDGF) and others (IGF-1, FGF, EGF) enhance tissue regeneration by stimulating cell proliferation, synthesis of extracellular organic matrix, vascular invasion, etc. Some researchers have shown the improvement in the regenerative processes and wound healing of soft tissues in PRP usage, but as for the bone tissue, the obtained results are controversial [25].

Thus, further studies are necessary to define the indications for use of the different types of bone grafts and to improve the efficacy of treatment for the facial bone defects. These studies should be aimed at a comparative assessment of the clinical efficacy and identification of factors that influence the surgical outcomes.

The purpose of this randomized prospective study was to compare the efficacy of surgical interventions to replace jaw defects with the use of xenogenic and autologous bone grafts, as well as their combination with plasma rich in growth factors (PRGF) based on objective clinical and radiological criteria.

**Materials and methods.** The patients with postoperative jaw defects treated at the Centre for Maxillofacial Surgery and Stomatology, Kyiv Regional Clinical Hospital were included to the study. From 2012 to 2017, 90 patients aged from 16 to 60 years (average age  $37.6 \pm 13.4$  years) were selected. They underwent reconstructive operations for replacing jaw defects with bone grafts and creating conditions for further prosthetic rehabilitation. The exclusion criteria were the following: age under 16, radiation- or chemotherapy in anamnesis, a concomitant decompensated somatic pathology, systemic osteoporosis, endocrine pathology, which can affect the metabolism of the bone tissue, mental illness, HIV, steroid therapy, chronic alcoholism or drug addiction, non-compliance with medical recommendations and lack of interaction with a doctor in the postoperative period, refusal of the patient to participate in the study. According to aetiology, the distribution of patients was as follows: 58.2% were operated for facial bone tumours and tumour-like lesions, 41.8% had defects of the alveolar process associated with traumatic multiple teeth removal, age-related atrophy or chronic inflammatory processes. The male to female ratio was 1:1.33. The patients were divided into 3 randomized groups, depending on the surgical treatment used (fig.1).

In group I, xenogenic bone substitutes (deproteinized animal bone matrix) were used in the form of granules 1-2 mm in diameter (Tutobone®, Gernamy, Alpha-Bio's Graft, Israel), or milled bone blocks (Ilaya, Ukraine), the maximum size of which reached 3-3.5 cm<sup>3</sup>.

In group II, autologous corticocancellous bone grafts obtained from the iliac crest were used to fill the defects. The bone blocks were fixed in the correct position by screws or titanium mini-plates (I-Plant, Ukraine). In group III, the defects were replaced by bone autograft combined with PRGF (BTI, Spain). To obtain PRGF, samples in standard test tubes containing 0.9 ml of 3.8 % sodium citrate per 8.1 ml of blood were centrifuged (580 g) for 8 minutes. The resulting plasma was divided into two fractions (F1 and F2). Fraction F2 was represented by 'platelet concentrate' with the highest platelet content, whereas fraction F1 was low in platelets and was used to form the fibrin membrane. Calcium chloride (0.5 ml per 1 ml of plasma) was added to the selected fractions to activate the coagulation and to form a clot or membrane. The resulting clots were added to the defect together with the autologous bone, and the fibrin membranes derived from fraction F1 were used to cover the graft before the surgical wound suturing. (Table 1).



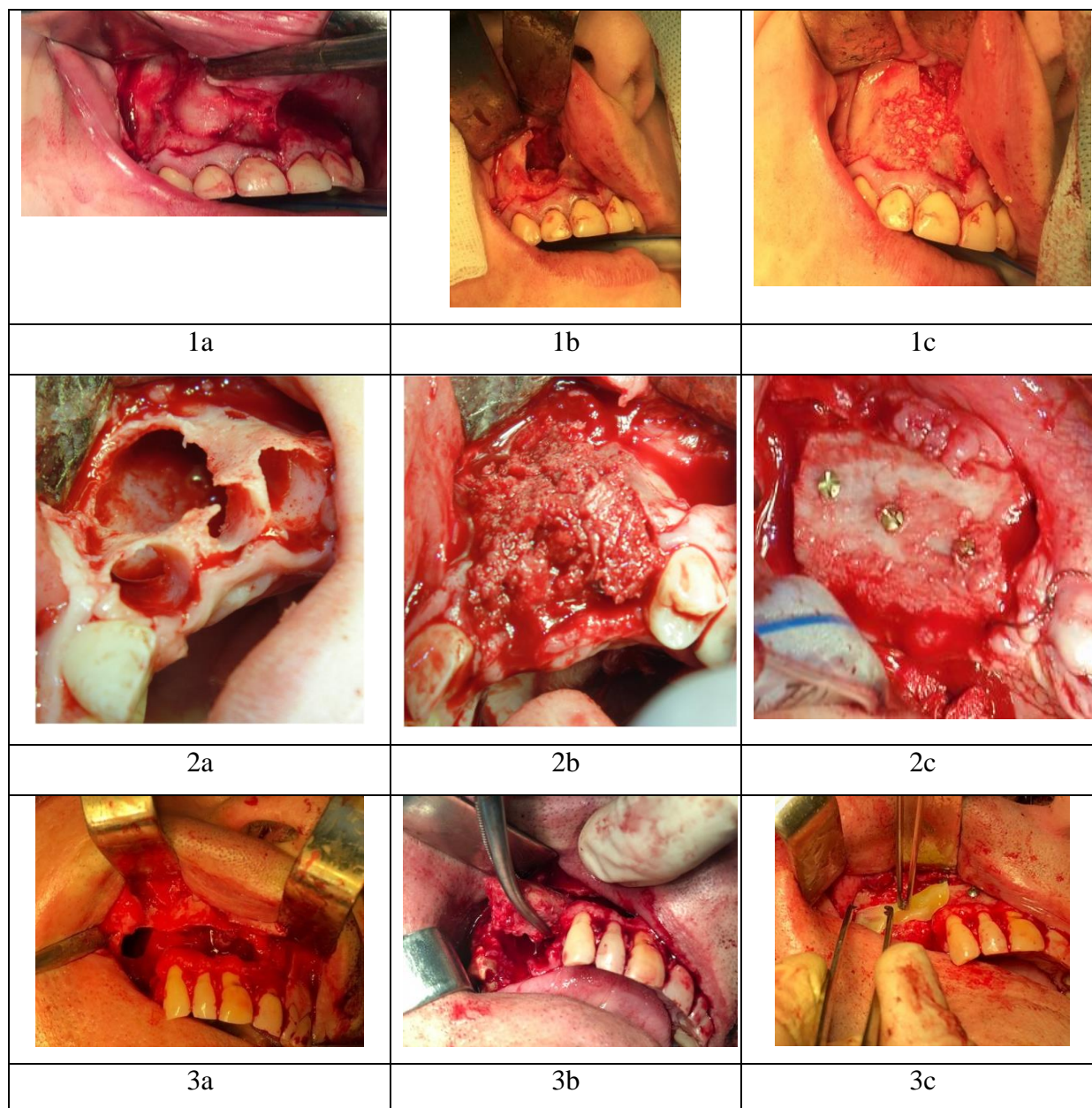


Figure 1. Reconstructive procedures with the use of different types of bone grafts: 1 - xenogenic bone substitutes; 2 - autologous bone grafts; 3- autologous bone grafts combined with PRGF.

In the postoperative period, all patients received anti-inflammatory and antibacterial therapy in accordance with standard protocols. Patients' status was assessed throughout their stay in the hospital and during control visits in the early (up to 1 month) and long-term postoperative period (more than 6 months). In the early postoperative period, the intensity of pain (VAS scale), the severity of edema, and the terms of wound epithelization were determined. To establish the integral efficacy of bone grafting procedure, clinical and

radiological criteria proposed by Barone et al. were used [26].

Table 1

General characteristics of jaw defects in clinical groups

Clinical group	Group I (xenogenic bone substitutes)	Group II (autologous bone grafts)	Group III (autologous bone grafts combined with PRGF)
The average age of patients	38.3±12	38.3±14	36.2±13.4
Associated somatic pathology	29.6%	21,8%	24.3%
Harmful habits (smoking, alcohol abuse)	11.1%	15.5%	16%
Average defect volume, mm <sup>3</sup>	2055±929.2	3013±2767	3103±1011
Localization of the defect - maxilla - mandible	59.3% 40.7%	59.5 40.5	58.06 41.94
Primary reconstruction	48.2%	55.1%	45.1%
Terms from defect formation to secondary reconstructions (months)	28.3 ± 8.2	21.6±9.5	26.1 ± 3.2

They included the absence of bone graft exposure, infection complications and sites of bone destruction on radiograms, the integration and absence of graft mobility in the recipient site, bleeding from grafted bone during drilling for dental implantation, and the presence of sufficient bone volume for dental implants placement or fixation of removable dentures in the long-term postoperative period.

In addition, all patients underwent cone-beam tomographic examination on PlanmecaProMax 3D with a subsequent analysis of the obtained data using SimPlantPro 11.04 software (Materialize, Belgium). Computer tomography was performed before surgery, in the early (up to 1 month) and late (more than 6 months) postoperative period. Based on the obtained data, the processes of regeneration, resorption and remodelling of the bone grafts were evaluated. In addition, using special tools for segmentation and editing of the 3-D images, virtual models of the bone grafts were created in the software environment, their volume was determined, and the percentage of different bone types by C. Misch (1999) was calculated in the area of bone reconstruction [28]. Additionally, the bone density of the recipient site was evaluated near the border of the defect in the pre-and postoperative period.

Statistical analysis of the data included the calculation of mean values, and standard deviation for each parameter in the clinical groups. The Kolmogorov-Smirnov test for

normality verification was used to determine the distribution pattern of the sample. For analysis of the data the non parametrical statistics was applied. The Mann–Whitney U test was used to compare the differences between the clinical and radiological parameters in the study groups. The level of significance was set at  $p < 0.05$ . Statistical calculations were performed in SPSS Statistics software environment (IBM SPSS, USA).

The study was approved by the Bioethics Commission at the Bogomolets National Medical University.

**Results.** Analysis of the clinical and radiological data revealed a significant variation of the bone defects in shape and size. Defects up to  $3 \text{ cm}^3$  were observed in 59 % of the patients, from 3 to  $5 \text{ cm}^3$  – in 29,6 % and over  $5 \text{ cm}^3$  – in 11,4 %. The average defect volume was  $2723 \pm 4033 \text{ mm}^3$ .

Primary reconstructions immediately after removal of tumours or affected bone were used 49,4 % of patients. In other patients, the surgery was performed within the period from 2 to 36 months from the time of defect formation, on average  $25 \pm 6,9$  months.

The duration of surgical intervention in the studied patients was  $57.4 \pm 29.3$  minutes. It was significantly higher ( $p < 0,05$ ) in patients of groups II and III. Although the graft harvesting from the iliac crest was performed simultaneously by a second brigade of surgeons, in cases with complex geometry of the defect, bone autografts required preliminary preparation and reshaping, sometimes fragmentation, to achieve a certain compliance with the relief of the recipient area, and it increased the time of the surgery. The average length of the hospital stay was  $5,42 \pm 2,28$  days and it did not differ significantly between clinical groups. The course of the early postoperative period in patients depended on the size of the defect and the applied method of surgical intervention. While analysing the severity of the pain syndrome, edema and the terms of wound epithelization in the oral cavity, it was found that the above parameters were significantly lower in the III group where the PRGF was used (Table 2).

Complications in the early and long-term postoperative period occurred in 13,02 % of the operated patients. Among them, infection complications and the graft exposure with wound dehiscence were prevalent. The use of appropriate conservative and surgical measures, in particular long-term antibiotic therapy, allowed retaining partially the grafted bone in the defect site and to use it for further implantation and prosthetic rehabilitation in most of the patients. Only 6 % of the grafts were completely lost, requiring secondary bone surgery and reconstructive interventions. Differences in the frequency and structure of postoperative complications in the study groups were not significant for this number of observations,



although, when using PRGF in group III, their frequency and severity were somewhat lower than in groups I and II.

Table 2

Clinical efficacy of reconstructive procedures with the use of different types of bone grafts

Clinical group	Group I (xenogenic bone substitutes)	Group II (autologous bone grafts)	Group III (autologous bone grafts combined with PRGF)
Average duration of surgery	57.7±28.9	79.5±35.1	82.5±24.09
Loss of graft volume within 6 months	19,9±8,1* <sup>II, III</sup>	45.6±21.84	46,1±23,8
Frequency of infection complications and exposure of grafts in the postoperative period	14.8%	15.1%	9.2%
Terms of complete wound epithelisation in the oral cavity	7.1±1.05days	7.3±0.94days	5.3±0.75days* <sup>I, II</sup>
Duration of severe postoperative edema	3.8±0.98 days	4.92±1.3 days	2.6±0.6days* <sup>II</sup>
Expression of pain syndrome on VAS in the early postoperative period	4,43±0,72	5,26±0,94	2,8±0,64* <sup>I, II</sup>
Installation of dental implants into the bone grafts	68.96%	59.5%	61.23%
Radiological density of the bone in the site of the bone grafting within 6 months.	D4 35.2±11,4 D3 40.7±18.2% D1 and D2 24.2±16.7%	D4 55.6±16.4% D3 39.3±12.3% D1 and D2 25±6%	D4 52.4±17.3% D3 42.5±14.8% D1 and D2 5±6.5%

\*- differences between groups are significant,  $p < 0.05$

75,4 % of all operated patients required prosthetic rehabilitation. In all these cases, non-removable and removable prosthetic constructions were manufactured or dental implants were placed (in 63,2 % of cases) (**fig. 2**). An intra operative assessment of the graft integration and remodelling in the recipient area during installation of dental implants revealed that in all cases the bleeding of the bone graft was present, indicating the restoration of the vascular net. In all observations of group II and III the signs of bone graft integration with recipient bone were detected. In group I, in the site of xenogenic bone grafting, the bone tissue conglomerates with varying degree of maturity, non-uniform density and inclusions of

residual material particles were seen. When dental implants were placed, in all cases the torque level of 30 Ncm or more was reached. In groups of patients with autografts (groups II and III), primary implant stability was higher, however, the differences for this parameter with group I were insignificant.

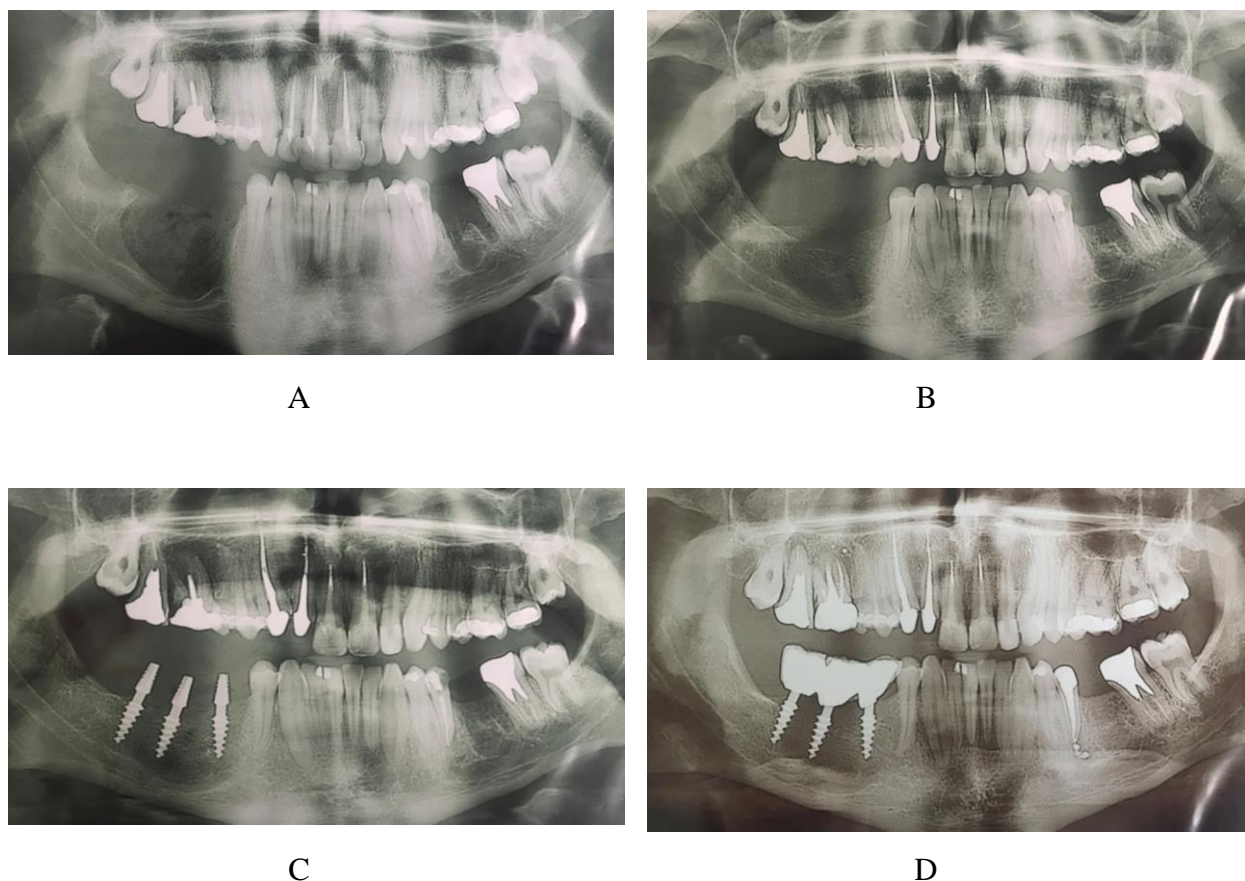


Fig. 2 Implant placement after bone reconstruction procedure with autologous bone graft from iliac crest

- A. Odontogenic ceratocyst of the mandible before radical surgical removal
- B. Defect filled with autologous bone graft at 5 month follow-up
- C Implant placement 5 months after bone grafting procedure
- D. Immediate loading of the implants with temporary crowns

Evaluation of the volumetric stability of the grafts in the long-term postoperative period revealed that autotransplants during their remodelling in the recipient site lost the volume by  $45,6 \pm 21,8$  %, the differences between groups II and III (PRGF group) for this parameter were insignificant (**fig. 3**). The mean loss of xenomaterial volume consisted  $19,9 \pm 8,1$  %. It was significantly lower than in groups II and III.

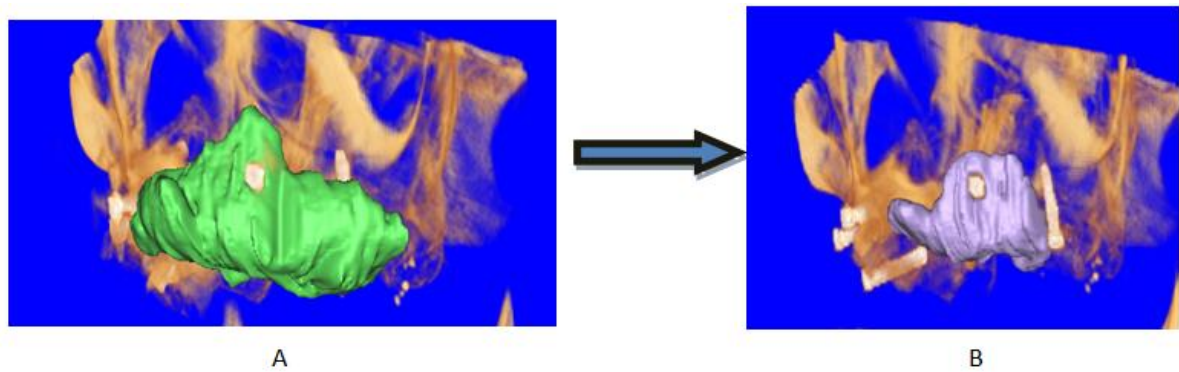


Fig. 3. Bone volume loss within the autologous bone graft caused by its resorbition and remodeling

- A. 3-D model of the graft immediately after the operation
- B. 3-D model of the graft at 6 month follow up.

Autologous grafts remodelling was characterized by an increase in the radiological density of the spongiuous layer of the graft: the percent volume of the type D3 bone increased by an average of  $15,9 \pm 13,6$  %, and the volume of type D4 bone decreased correspondingly (fig. 4). Thus, following the volume loss, during adaptive remodelling, autologous bone grafts underwent a structural transformation, acquiring better mechanical properties. At the same time, the use of platelet concentrates in combination with autologous grafts did not significantly affect the changes in their volume and density.

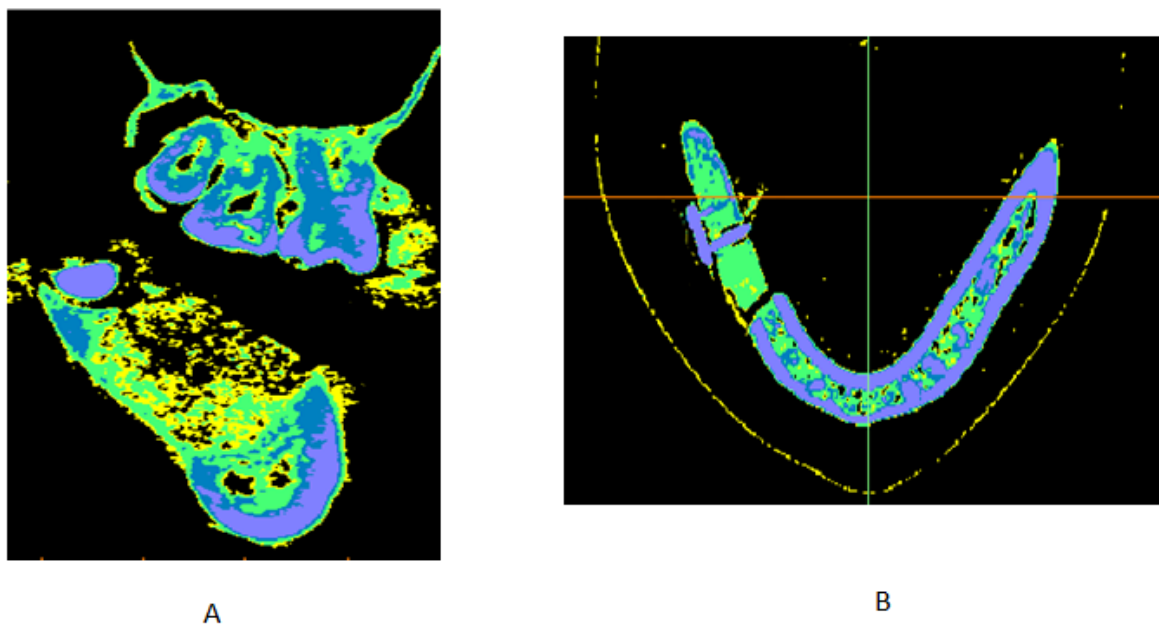


Fig. 4. Distribution of the bone tissue with different mineral density in the areas of bone reconstruction: A – Xenogenic material (group I), B - Autogenous bone graft (group II).

In group I at the site of grafted xenogenic material, after 6 months from the surgical intervention, the bone structure was significantly different from the normal jaw architectonics. The bone conglomerates had a higher density compared with autografts from the iliac crest. Although type D3 bone tissue was the most predominant (an average of  $40,7 \pm 18$  %), the bone content of type D1 and D2 turned out to be significantly higher ( $p < 0,05$ ). These types of bone were presented by numerous diffuse small areas located inside the regenerate, which determined the mosaic structure of the bone conglomerate with a chaotic alternation of areas with higher and lower radiological density. Pores and bone marrow spaces were practically absent. This generally determined the lower quality of the bone regenerate in its mechanical and biological properties compared with the remodelled bone autografts in groups II and III.

**Discussion.** The issue of the optimal method for replacing bone defects of the jaws and creating the bone volume sufficient for dental implantation and adequate prosthetic rehabilitation remains the subject of scientific discussion [13, 19, 27]. According to the literature, none of the existing bone replacement materials can ensure the predicted achievement of desired outcomes in all clinical cases. Each of the many methods based on the use of auto-, allo- and xenogenic grafts has its own drawbacks and limitations of usage, which are interpreted in differently in various scientific papers, clinical guidelines and protocols [28, 29].

At present, most authors consider that the use of bone autografts with good osteoinductive and osteoconductive properties is a 'gold standard' of replacing large jaw defects [7, 8, 11]. The present study demonstrated satisfactory results in 87 % of patients when using autologous bone grafts (according to Barone et al. criteria), which is generally consistent with the results obtained by other authors [30, 31]. The main causes of failure during reconstructive procedures included the development of infectious complications, wound dehiscence and graft exposure, which arose mainly in the early postoperative period. Noteworthy is the fact that only in 6 % of cases the complications resulted in complete loss of graft and the need for secondary reconstructions.

At the same time, long-term follow up findings from CT data revealed the main disadvantage of autologous bone application in bone reconstruction, namely its volumetric instability and significant loss of volume following resorption and bone graft remodelling [13-15]. According to our data, during the first 6 months, by the moment when in the majority of patients the dental implants or final dentures were installed, an average loss of graft volume was  $45,6 \pm 21,84$  % and in individual observations it reached 65,3 %. Although in the present study, dental implants were successfully installed in 63,23 % of patients, to achieve such

outcomes, we had to plan carefully all treatment and rehabilitation measures, select specific implantation systems and use surgical guides to determine the appropriate position of the implant, taking into account the topographic features of resorption and bone graft rearrangement.

Xenogenic bone substitutes in group I provided satisfactory results in 85,2 % of cases, which did not significantly differ from the results in groups II and III, but they showed higher levels of volumetric stability. The main disadvantage of xenogenic bone materials, revealed in this study, was that bone conglomerates formed as a result of their remodelling differed significantly from the intact jaw bone in structure, physico-mechanical and biological properties. Our findings do not confirm the results of the authors (RenzoGuarnieri, 2016 and BaroneA., 2012) who showed that xenogenic grafts can be completely replaced by the normal bone within 6-14 months, with the exception of small fragments [32, 33]. When placing implants in this group of patients, in any case, we did not observe a complete reorganization of the xenogenic material or its replacement with the newly formed bone tissue. The degree of xenograft integration with the surrounding bone tissue was always lower than in cases with the autologous bone. According to the CT, the bone conglomerate, which is formed in the site of xenogenic bone grafting, was characterized by a higher density, almost complete absence of pores and bone marrow spaces, a mosaic internal structure with a chaotic alternation of areas with higher and lower radiological density, simpler geometry of structures with different mineral content as compared with the intact bone. This determined the worse biomechanical characteristics and the lower resistance of bone than in autologous grafts.

Thus, in most cases, the techniques of bone reconstruction with autologous or xenogenic grafts allowed creating the adequate bone volume, restoring the anatomical shape of the bone and its function, as well as further prosthetic rehabilitation. However, the quality of the formed bone tissue and its architectonics substantially differed from the normal organ-specific architectonics of the jaw. This should be taken into account when selecting the optimal type of dental implants, determining the time of their placement and loading, the type of prosthetic construction to be installed, etc.

The present study also confirms the authors' opinion that one of the main challenges that arise when replacing large jaw defects is the low predictability of the outcome in terms of bone graft remodeling and its integration with the recipient bone in each individual case [34, 35]. It is known that in patients with compromised regenerative potential resulting from a deteriorated condition of somatic health, age-related changes, genetic predisposition, or unfavourable local conditions, the course of regeneration and graft remodelling may slow



down and change qualitatively, which compromise integral treatment outcome. In this regard, there is a tendency for an active search for new options to optimize the processes of bone reparative regeneration [36]. One of such options is plasma rich in platelets, and one of the variations offered by E. Anitua - the method for obtaining plasma rich in growth factors (PRGF) [37]. The authors prove that PRGF is capable of stimulating osteogenesis and angiogenesis by creating a fibrin matrix that promotes cellular migration, activates the processes of proliferation and differentiation of connective tissue cells, and increases the synthesis of the organic bone matrix [38]. At the same time some authors reported no significant differences in the long-term outcomes of bone regeneration while using PRGF as compared with the control group after tooth extraction, periodontal operations, etc [38, 40, 41].

Our study have shown that the use of PRGF (BTI, Spain) in autologous bone grafting procedures is capable to accelerate wound epithelisation, reduce pain and edema in the early postoperative period, and slightly reduce the incidence of complications [39]. However, we have not revealed a statistically significant effect of PRGF on the volumetric stability or mineral bone density in the long-term postoperative period. This can be explained by the fact that the growth factors contained in the platelet granules act primarily on the angiogenesis, the proliferation of the epithelium and fibroblasts and to a lesser extent influence the osteogenic stem cells and the bone matrix formation. A similar conclusion comes from Rivera C, 2013, who showed that platelet concentrates practically do not affect osteogenic precursor cells (stem cells), whose differentiation is regulated mainly by morphogenetic bone proteins (BMPs) [40]. Wiltfang J, 2004, and Thor A, 2007 reported that the osteoinductive effect of platelet plasma is only partially manifested in the initial stages of bone regeneration due to activation of pre-osteoblasts chemotaxis, and further it became non-significant under the influence of other factors regulating bone tissue metabolism [41, 42].

Thus, the study did not reveal significant differences in the integral outcome of treatment in patients with jaw defects. At the same time, it demonstrated certain pros and cons of each technique used. This indicates the need for a differentiated and personalized approach to selecting the bone grafting method in each particular situation.

**Conclusions.** 1. In the study series, xenogenic materials showed the highest volumetric stability in the remote postoperative period ( $19,9 \pm 8,1\%$  versus  $45.6 \pm 21.84\%$  for bone autografts). However, autologous grafts demonstrated better integration and quality of bone tissue, which was formed during the process of regeneration and remodelling of the graft.

2. There were no significant differences in frequency of postoperative complications within the 6 months or the possibility of implant placement in the study groups. Implants installed in the area of autologous bone grafts demonstrated the higher primary stability, although for a given number of observations, the differences were statistically insignificant.

3. The use of PRGF in combination with autologous bone grafts accelerated the regeneration of soft tissues and reduced the time of wound epithelisation, postoperative edema and pain syndrome, but it does not affect significantly the incidence of infection complications and the severity of postoperative resorption and volume loss of the bone grafts.

### **References**

1. Vovk Y. Results of the guided bone regeneration in patients with jaw defects and atrophies by means of Mondeal® occlusive titanium membranes. - International Journal of Oral and Maxillofacial Surgery. 2005;1(34):123.

2. Shnayder Y.et al. Reconstruction of the Lateral Mandibular Defect: A Review and Treatment Algorithm: JAMA Facial Plast Surg. 2015;17(5):367-73.

3. Greenbaum M., Kanat I. Current concepts in bone healing. Review of the literature. Journal of the American Podiatric Medical Association. 1993;83(3):123–129.

4. Schmitz J., Hollinger J. The critical size defect as an experimental model for craniomandibulofacial nonunions. Clinical Orthopaedics and Related Research. 1986;205:299–308.

5. Jensen S.S., Terheyden H. Bone augmentation procedures in localized defects in the alveolar ridge: clinical results with different bone grafts and bone-substitute materials.:Int J Oral Maxillofac Implants. 2009;24:218-36.

6. Spin-Neto R., Stavropoulos A., F.L. Coletti et al. Graft incorporation and implant osseointegration following the use of autologous and fresh-frozen allogeneic block bone grafts for lateral ridge augmentation.:Clin Oral Implants Res. 2014;25(2):226-33.

7. Sbordonea C., et al. Volumetric changes after sinus augmentation using blocks of autogenous iliac bone or freeze-dried allogeneic bone. A non-randomized study. - Int J Oral Maxillofac Surg. 2014;42:113-118.

8. Abdulrazaq S.S. Evaluation of the Trephine Method in Harvesting Bone Graft From the Anterior Iliac Crest for Oral and Maxillofacial Reconstructive Surgery. -J Craniofac Surg. 2015;26(8):744-6.

9. Streckbein P., Kähling C. Wilbrand J.F. et al. Horizontal alveolar ridge augmentation using autologous press fit bone cylinders and micro-lag-screw fixation: technical note and initial experience. J Craniomaxillofac Surg. 2014;42(5):387-91.

10. RevieJ., Kerns G.:Mechanisms of Guided Bone Regeneration. *Open Dent J.* 2014; 8: 56–65.
11. Miron R.J., Hedbom E., Saulacic N. et al. Osteogenic potential of autogenous bone grafts harvested with four different surgical techniques. *J. Dent Res.* 2011;90:1428–1433.
12. Brugnami F. Local intraoral autologous bone harvesting for dental implant treatment: alternative sources and criteria of choice. *Keio J Med.* 2009;58(1):24-8.
13. Johansson B., Grepe A., Wannfors K. et al. A clinical study of changes in the volume of bone grafts in the atrophic maxilla. *DentomaxillofacRadiol.* 2001;30:157.
14. Dasmah A., Tho A., Ekestubbe A., Sennerby L., Rasmusson L. et al. Particulate vs. block bone grafts: three-dimensional changes in graft volume after reconstruction of the atrophic maxilla, a 2-year radiographic follow-up. *J. Craniomaxillofac Surg.* 2012;40(8):654-9.
15. Mertens C., Decker C., Engel M., Sander A., Hoffmann J., Freier K. Early bone resorption of free microvascular reanastomized bone grafts for mandibular reconstruction--a comparison of iliac crest and fibula grafts. *J. Craniomaxillofac Surg.* 2014;42(5):217-23.
16. Galindo-Moreno, P., Padial-Molina, M., Fernandez-Barbero, J.E., Mesa, F., Rodriguez-Martinez, D. &O'Valle, F. Optimal microvessel density from composite graft of autogenous maxillary cor-tical bone and anorganic bovine bone in sinus augmentation: influence of clinical variables. *Clinical Oral Implants Research.* 2010;21:221–227.
17. Berglundh T, Lindhe J. Healing around implants placed in bone defects treated with Bio-Oss: an experimental study in the dog. *Clin Oral Implants Res.* 1997;8:117–24.
18. Artzi Z., Tal H., Dayan D. Porous bovine bone mineral in healing of human extraction sockets. Part 1. histomorphometric evaluations at 9 months. *J Periodontol.* 2000;71:1015–23.
19. Wetzel A.C., Stich H., Caffesse R.G. Bone apposition onto oral implants in the sinus area filled with different grafting materials: a histological study in beagle dogs. *Clin Oral Implants Res.* 1995;6:155–63.
20. Hallman, M., Lundgren, S., Sennerby, L. Histologic analysis of clinical biopsies taken 6 months and 3 years after maxillary sinus floor augmentation with 80% bovine hydroxyapatite and 20% autogenous bone mixed with fibrin glue. *Clinical Implant Dentistry and Related Research.* 2001;3: 87–96.
21. Piattelli M., Favero G.A., Scarano A. et al. Bone reactions to anorganic bovine bone (Bio-Oss) used in sinus augmentation procedures: a histologic long-term report of 20 cases in humans. *Int J Oral Maxillofac Implants.* 1999;14:835–40.

22. Piattelli M., Favero G.A., Scarano A. et al. Bone reactions to anorganic bovine bone (Bio-Oss) used in sinus augmentation procedures: a histologic long-term report of 20 cases in humans. *Int J Oral Maxillofac Implants*. 1999; 14:835–40.
23. Macera A., Nistri L., Redl B., Innocenti M., Civinini R. The use of autologous blood-derived growth factors in bone regeneration, *Clin Cases Miner Bone Metab*. 2011; 8(1):25–31.
24. Hakimi M, Jungbluth P, Sager M, et al.: Combined use of platelet-rich plasma and autologous bone grafts in the treatment of long bone defects in mini-pigs. *Injury*. 2010;41(7):717–723.
25. Isaac A., Rodriguez E., Gowney Kalaf A.: Platelet-Rich Plasma in Bone Regeneration: Engineering the Delivery for Improved Clinical Efficacy - *Biomed Res Int*. 2014; 2014: 392398. 2014 Jun 23. doi: 10.1155/2014/392398.
26. Barone A., Covani U. Maxillary alveolar ridge reconstruction with nonvascularized autogenous block bone: clinical results. *J Oral Maxillofac Surg* 65:2039, 2007.
27. Gultekin B.A., Bedeloglu E., Kose T.E., Mijiritsky E. Comparison of Bone Resorption Rates after Intraoral Block Bone and Guided Bone Regeneration Augmentation for the Reconstruction of Horizontally Deficient Maxillary Alveolar Ridges E.: *Biomed Res Int.*, 2016;26.
28. Misch C.E., Dietsh F. Bone-grafting materials in implant dentistry. *Implant Dent*. 1993;2:158–67.
29. Wetzel A.C., Stich H., Caffesse R.G. Bone apposition onto oral implants in the sinus area filled with different grafting materials: a histological study in beagle dogs. *Clin Oral Implants Res*. 1995;6:155–63.
30. Timothy M., Deeb H., Pushkar M. Iliac crest bone grafting for mandibular reconstruction: 10-year experience outcomes. *J Oral Biol Craniofac Res*. 2018 Jan-Apr; 8(1): 25–29.
31. Waseem Ahmed, Muhammad Adil Asim, Afeefa Ehsan, Qalab Abbas Non-Vascularized Autogenous Bone Grafts for Reconstruction of Maxillofacial Osseous Defects.- *Journal of the College of Physicians and Surgeons Pakistan*. 2018;28(1):17-21.
32. Barone A., Ricci M., Covani U., Nannmark U., Azarmehr I., Calvo-Guirado J.L. Maxillary sinus augmentation using prehydrated corticocancellous porcine bone: histomorphometric evaluation after 6 months. *Clin Implant Dent Relat Res*. 2012;14(3):373-9.

33. Guarnieri R., Belleggia F., Ippoliti S. et al. Clinical, Radiographic, and Histologic Evaluation of Maxillary Sinus Lift Procedure Using a Highly Purified Xenogenic Graft (Laddec®). *J Oral Maxillofac Res.* 2016; 7(1);3.
34. Alayan J., IvanovskS. A prospective controlled trial comparing xenograft/autogenous bone and collagen-stabilized xenograft for maxillary sinus augmentation—Complications, patient-reported outcomes and volumetric analysis. *Clin Oral Impl Res.* 2017;1–15.
35. Brugnami F., Caiazzo A., Leone C. Local intraoral autologous bone harvesting for dental implant treatment: alternative sources and criteria of choice. *Keio J Med.* 2009;58(1):24-8.
36. Pacifici L., Casella F., Ripari M. Lifting of the maxillary sinus: complementary use of platelet rich plasma, autologous bone deproteinised bovine bone. Case report. *Minerva Stomatologica.* 2003;52(9):471–478.
37. Anitua E., Prado R., Troya M. et al. Implementation of more physiological plasma rich in growth factor (PRGF) protocol: Anticoagulant removal and reduction in activator concentration. *J Platelets.* 2016;5(27):459-466.
38. Isaac A. Rodriguez, Emily A. GrowneyKalaf, Gary L. Bowlin, and Scott A. Sell, “Platelet-Rich Plasma in Bone Regeneration: Engineering the Delivery for Improved Clinical Efficacy,” *BioMed Research International*, vol. 2014, Article ID 392398, 15 pages, 2014. <https://doi.org/10.1155/2014/392398>.
39. Anitua E. The use of plasma-rich growth factors (PRGF) in oral surgery. *J PractProcedAesthet Dent.* 2001;6(5):487-493.
40. Rivera C., Monsalve F., Salas J., Morán A., Suazo I. Platelet-rich plasma, plasma rich in growth factors and simvastatin in the regeneration and repair of alveolar bone. *ExpTher Med.* 2013;6(6):1543-1549.
41. Thor A., Franke-Stenport V., Johansson C.B., et al. Early bone formation in human bone grafts treated with platelet rich plasma: Preliminary histomorphometric results. *Int. J Oral Maxillofac Surg.* 2007; 36:1164–1171.
42. Wiltfang J., Kloss F.R., Kessler P., Nkenke E., Schultze-Mosgau S., Zimmermann R., et al. Effects of platelet-rich plasma on bone healing in combination with autogenous bone and bone substitutes in criticalsize defects. *Clin Oral Implants Res.* 2004;15(2):187–93.