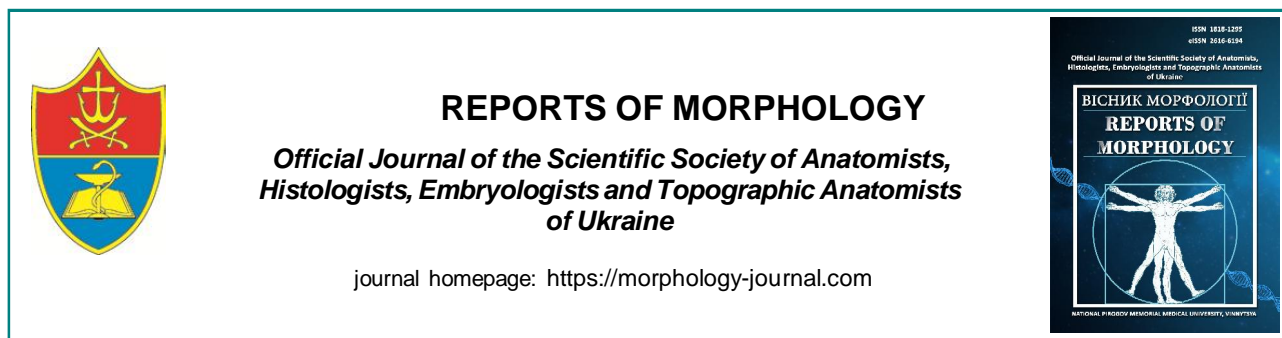

REPORTS OF MORPHOLOGY

Official Journal of the Scientific Society of Anatomists,
Histologists, Embryologists and Topographic Anatomists
of Ukraine

journal homepage: <https://morphology-journal.com>

Histological changes in the liver of rats under the influence of *Vipera berus berus* venom

Turbal L. V.¹, Yaremenko L. M.¹, Maievskiy O. Ye.²

¹Bogomolets National Medical University, Kyiv, Ukraine

²Educational and Scientific Center "Institute of Biology and Medicine", Taras Shevchenko National University of Kyiv, Kyiv, Ukraine

ARTICLE INFO

Received: 20 July 2023

Accepted: 6 October 2023

UDC: 61:615.9/616:616-005/616.3

CORRESPONDING AUTHOR

e-mail: ludmilaturbal@gmail.com

Turbal L. V.

CONFLICT OF INTEREST

The authors have no conflicts of interest to declare.

FUNDING

Not applicable.

DATA SHARING

Data are available upon reasonable request to corresponding author.

Animal venoms contain a whole complex of compounds, among which there are peptides, proteins, as well as other organic molecules and salts. Their toxins are able to cause pronounced disturbances in the functioning of physiological systems, leading to the appearance of pathological conditions, complications, or even death. The aim of the research is to study the histological changes in the liver of rats under the influence of Vipera berus berus venom. Experimental studies were carried out on white non-linear male rats. The animals were conditionally divided into two groups - a control and an experimental group of 10 individuals in each. Experimental rats were injected intraperitoneally with a semi-lethal dose (LD50) (1.576 mg/g-1) of Vipera berus berus venom in saline solution. Animals of the control group were injected intraperitoneally with only saline solution. Rats were removed from the experiment 24 hours after exposure to the venom, anesthetized by cervical dislocation. Liver samples of animals of all groups were taken for microscopic examination. Histological preparations of the liver were stained with hematoxylin and eosin. Histological preparations were studied using a SEO SCAN light microscope. To identify the key enzyme of the citric acid cycle - succinate dehydrogenase, histochemical studies were performed according to the Nakhlas method. To study the features of glycogen accumulation in hepatocytes, sections were stained using Schiff's reagent, after pretreatment with iodic acid (PAS reaction) in Shabadash's modification. An immunohistochemical research method was used to detect a subpopulation of CD86+ cells in the liver of experimental animals. Under the influence of Vipera berus berus venom, the development of alterative changes in the liver parenchyma and vascular disorders were microscopically revealed. The appearance of foci of leukocyte infiltration was established, which indicates the development of inflammatory processes. A histochemical study of the content of succinate dehydrogenase in the liver of animals injected with Vipera berus berus venom showed uneven activity of the mitochondrial enzyme in the lobules. A histochemical study of glycogen in hepatocytes of the liver of rats exposed to Vipera berus berus venom showed a decrease in the content of trophic inclusions. An increase in the population of CD86+ cells indicates reactive inflammatory processes observed in the body as a result of the action of components of Vipera berus berus venom.

Keywords: vipers, liver, succinate dehydrogenase, glycolen, CD86+.

Introduction

In the processes of evolutionary adaptation, a significant number of both invertebrates and vertebrates have acquired poisonous properties. Their venoms play numerous functions, providing adaptation, protection and necessary for hunting prey and interspecies competition. A combination of environmental, genetic, climatic and biogeographical factors over millions of years has given rise to a fascinating variety of their constituent toxic

components, which have become a key feature of these animal species [3, 4, 18]. Animal venoms contain a whole complex of compounds, among which there are peptides, proteins, as well as other organic molecules and salts. Their toxins are able to cause pronounced disturbances in the functioning of physiological systems, leading to the appearance of pathological conditions, complications, or even death [5, 13, 20].

To date, the scientometric databases contain studies regarding the biological activity of certain components of the venom of snakes and vipers, the peculiarities of their tropism to tissues and organs. It has been established that their toxic substances exhibit a wide range of pathological effects in relation to most vital systems, causing damage to the lungs, heart, kidneys, skeletal muscles, etc. [6, 11, 12, 14]. However, the number of experimental works on the influence of the venom of various species of snakes and vipers on the morpho-functional changes of the liver is too limited. The fact that the liver occupies one of the main places in the detoxification processes of exogenous and endogenous toxic compounds is indisputable. In modern conditions of the world existence, the human body is in constant contact with toxicants of various origins, and the ability of the liver to quickly dispose of them determines in a certain way the ability to survive and maintain homeostasis parameters at a relatively constant level. However, during the metabolism of many xenobiotics, including animal venom toxins, irreversible changes in the features of histological organization and the course of biochemical processes in liver cells are possible, which ultimately leads to its dysfunction in general, and in severe cases to the development of toxic necrosis. Scientists assume that this condition arises as a result of the formation of toxic metabolites during detoxification, which have a detrimental effect on the molecular structures of hepatocytes, causing their death [15, 16, 17, 19].

The aim of the research is to study the histological changes in the liver of rats under the influence of *Vipera berus berus* venom.

Materials and methods

Experimental studies were carried out on white non-linear male rats. For preliminary acclimatization, the animals were kept for 7 days in the animal facility of Taras Shevchenko National University of Kyiv, and then kept in laboratory conditions at constant temperature (22 ± 3 °C), humidity (60 ± 5 %) and light (12 h light/12 h dark cycle), being fed standard rodent food and water ad libitum [7]. All experiments were conducted in accordance with the National Institutes of Health Guidelines for the Care and Use of Laboratory Animals and the European Council Directive of November 24, 1986 for the Care and Use of Laboratory Animals (86/609/EEC). The research was approved and confirmed by the bioethics commission of the Institute of Biology and Medicine of the Taras Shevchenko National University of Kyiv (protocol № 2 dated August 19, 2021).

Vipera berus berus venom was obtained from the V. N. Karazin Kharkiv National University. The lyophilized crude venom was stored at -20 °C and then dissolved in saline solution immediately before the experiment.

The animals were conditionally divided into two groups - a control and an experimental group of 10 individuals in

each. Experimental rats were injected intraperitoneally with a semi-lethal dose (LD50) (1.576 mg/g-1) of *Vipera berus berus* venom in saline solution. Animals of the control group were injected intraperitoneally with only saline solution. Rats were removed from the experiment 24 hours after exposure to the venom, anesthetized by cervical dislocation.

Liver samples of animals of all groups were taken for microscopic examination. The pieces were fixed in a 10 % formalin solution for 1 day. Next, the pieces were dehydrated in alcohols of increasing concentration and embedded in paraffin blocks. Histological preparations of the liver were stained with hematoxylin and eosin [10]. Histological preparations were studied using a SEO SCAN light microscope and photo-documented using a Vision CCD camera with a system of image output from histological preparations.

To identify the key enzyme of the citric acid cycle - succinate dehydrogenase, histochemical studies were performed according to the Nakhlas method [10]. These studies were carried out on sections made in a cryostat microtome from unfixed tissue using nitro blue tetrazole. The precipitate in the form of blue granules of diformazan testified to the presence and localization of the enzyme.

To study the features of glycogen accumulation in hepatocytes, sections were stained using Schiff's reagent, after pretreatment with iodic acid (PAS reaction) in Shabadash's modification.

An immunohistochemical research method was used to detect a subpopulation of CD86+ cells in the liver of experimental animals. Liver sections (thickness 4 μm) made from paraffin blocks using an AMR-400 rotary microtome (Amos scientific, Australia) were subjected to deparaffinization and rehydrated. Antigen recovery was performed in the KOS histoprocessor (Milestone, Italy). In the immunohistochemical staining protocol, mouse monoclonal primary antibodies Anti-CD86 (BP2-44514-0.1 mg, Novus Biologicals, USA) and the polymer detection system Mouse/Rabbit PolyVue™ HRP/DAB (Diagnostic BioSystems, USA) were used. Sections were counterstained with Mayer's hematoxylin (Biognost, Croatia).

Results

Histological studies of rat liver preparations under the influence of *Vipera berus berus* viper venom showed the manifestation of reactive alternative changes in the stroma and parenchyma of the organ. Violations of the microcirculatory system are observed, namely, sinusoidal hemocapillaries, the lumens of which are unevenly expanded, full of blood, with erythrocyte stasis, few lymphocytes are noted. Sinusoids with narrowed lumens were also detected (Fig. 1). Leukocyte infiltration is observed in the connective tissue around the triads. Stasis and coagulation of erythrocytes are found in the lumen of blood-filled interlobular veins (Fig. 2).

The location of hepatocytes in the form of plates, which

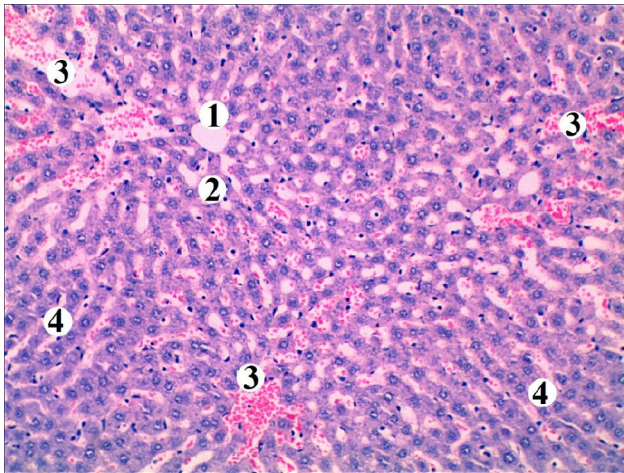


Fig. 1. Microscopic changes in the rat liver under the influence of *Vipera berus berus* venom: 1 - central vein, 2 - dilated lumens of sinusoidal hemocapillaries, 3 - erythrocyte stasis, 4 - hepatocyte plate. Staining with hematoxylin and eosin. Magnification: x100.

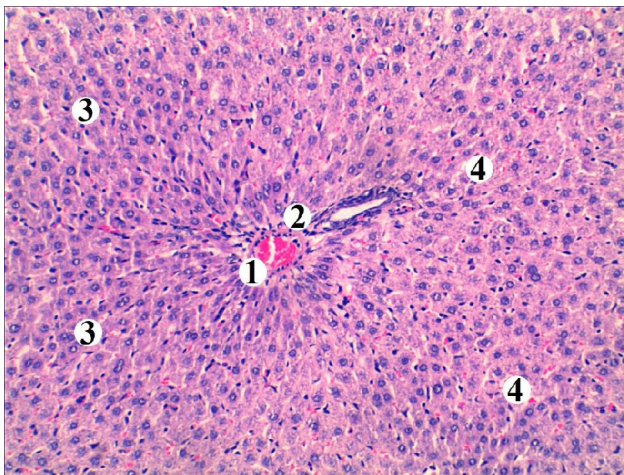


Fig. 2. Microscopic changes in the rat liver under the influence of *Vipera berus berus* venom: 1 - blood-filled interlobular vein with coagulation of erythrocytes in the lumen, 2 - lymphohistiocytic infiltration of the portal tract, 3 - hepatocyte plates, 4 - unevenly expanded spaces of sinusoidal hemocapillaries. Staining with hematoxylin and eosin. Magnification: x100.

diverge radially, is mostly preserved. Hepatocytes with hyperchromic nuclei are found in the periportal and centrilobular areas of classic liver lobes. Individual cells with pyknotic nuclei and intensely basophilic cytoplasm were observed, especially in the periportal areas. Many nuclei in the cells are normochromic. Binucleated hepatocytes with light euchromatin nuclei were found in the centrilobular parts of the lobule (Fig. 3). An increase in the population of Kupffer cells was noted in the space of Disse.

A histochemical study of the content of succinate dehydrogenase in the liver of animals injected with *Vipera berus berus* venom showed uneven activity of the mitochondrial enzyme in the lobules. Hepatocytes with moderate enzyme activity are intensely stained,

characterized by large granules of diformazan and a powdery-amorphous sediment and are located mainly in the peripheral areas of the lobule (Fig. 4). In the centrilobular zone, hepatocytes with a low degree of staining are observed, which indicates a decrease in succinate dehydrogenase in the cytoplasm of cells. The average value of the activity coefficient of succinate dehydrogenase in hepatocytes of the liver of experimental rats is 3.652 ± 0.171 nmol succinate/(min/mg protein), which is significantly ($p < 0.001$) 0.76 times lower than the similar parameter of the intact group of animals.

A histochemical study of glycogen in hepatocytes of the liver of rats exposed to *Vipera berus berus* venom showed a decrease in the content of trophic inclusions. In most hepatocytes, there is an accumulation of pink-red glycogen granules peripherally, while part of the cytoplasm is freed from its contents and has an oxyphilic color (Fig. 5). There are individual cells with the typical localization of this trophic

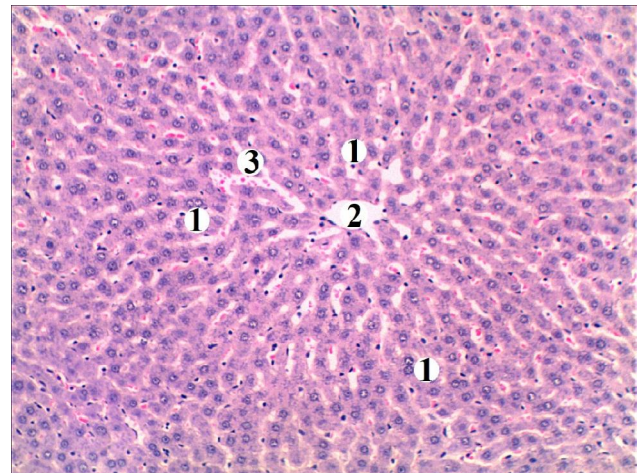


Fig. 3. Microscopic changes in the rat liver under the influence of *Vipera berus berus* venom: 1 - binucleated hepatocytes, 2 - central vein, 3 - expanded sinusoidal hemocapillaries with formal elements in the lumen. Hematoxylin and eosin staining. Magnification: x100.

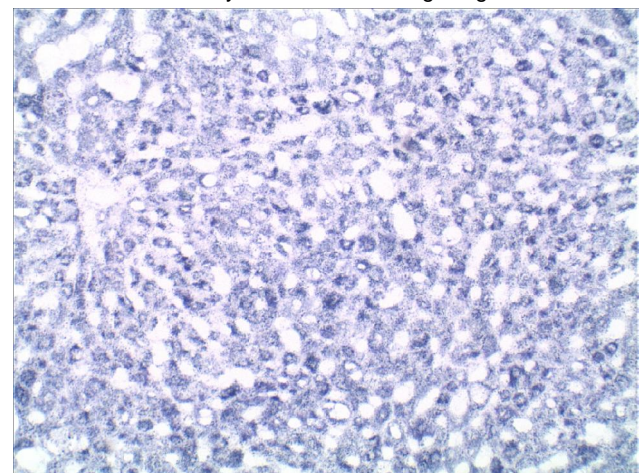


Fig. 4. Succinate dehydrogenase activity in rat liver hepatocytes under the influence of *Vipera berus berus* venom. Cells with low and high enzyme activity. The Nakhlas method. Magnification: x200.

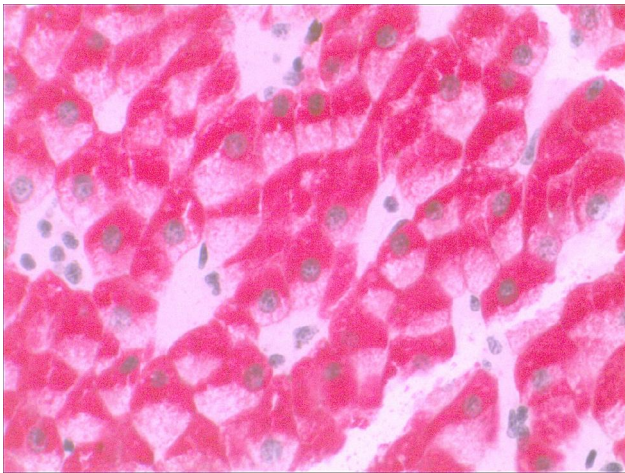


Fig. 5. The presence of glycogen in the liver of rats exposed to *Vipera berus berus* venom. Low content of trophic inclusions in the cytoplasm of hepatocytes. Shabadash method. Magnification: x400.

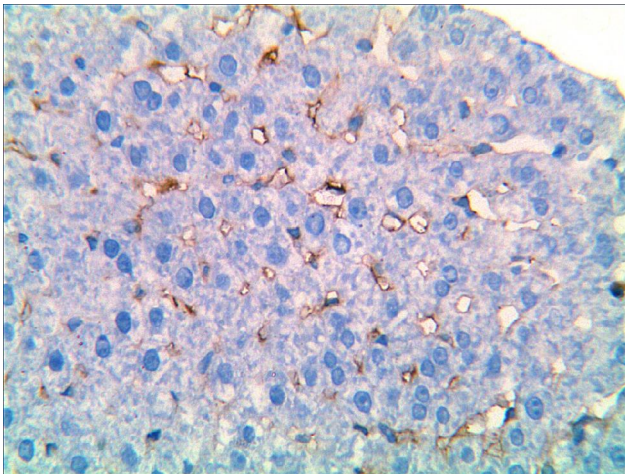


Fig. 6. Expression of CD86+ cells of the rat liver lobule under the influence of *Vipera berus berus* venom. Immunohistochemical reaction of CD86+ antibody. Staining with Mayer's hematoxylin. Magnification: x400.

compound. The average value of the cytochemical indicator is 3.413 ± 0.160 nmol succinate/(min/mg protein) and decreases significantly ($p < 0.001$) by 0.69 times compared to the indicator of the intact group of animals.

Immunohistochemical examination of the liver of animals injected with *Vipera berus berus* venom showed that populations of CD86+ cells are found in different areas of the liver lobe. Most of them have light brown or brown cytoplasm with numerous processes that lie along the lumen of the sinusoid, sometimes found in the perisinusoidal spaces (Fig. 6). The degree of expression of CD86 transmembrane glycoprotein is low (+--), but more intense compared to the intact group of animals. An increase in the population of CD86+ cells indicates reactive inflammatory processes observed in the organ due to the action of components of the *Vipera berus berus* venom.

Discussion

Envenomation as a result of snake and viper bites is accompanied by morphological and biochemical changes in the victim's body. A. K. Asmari et al. [2] investigated serological markers of acute hepatotoxicity caused by *Echys pyramidum* snake venom in rats. After 3-6 hours of intraperitoneal venom injection, pronounced changes in the functional activity of the organ were detected in experimental animals. In particular, an increase in serum levels of ALT, alkaline phosphatase, gammaglutamyl transpeptidase (GGT) and bilirubin were recorded. Liver damage was accompanied by a significant and dose-dependent decrease in the activity of antioxidant defense enzymes, namely superoxide dismutase (SOD) and catalase (CAT) in liver tissue. The authors reported on the activation of lipid peroxidation (LP) as a result of the generation of a significant amount of reactive oxygen species (ROS), which led to hepatocyte apoptosis. In addition, an increase in markers of oxidative stress (OS), the activity of cytoplasmic, lysosomal and extracellular matrix-degrading enzymes, and levels of pro-inflammatory mediators were characteristic.

According to certain studies, the toxins of *Crotalus durissus terrificus* vipers cause the development of acute liver damage. Its administration to rats at a dose of 100 mg/kg caused an increase in the activity of AST, ALT, alkaline phosphatase, and GGT after 3 hours of the experiment. Histological studies of the liver tissue under these conditions at different times (from 3 to 12 hours) demonstrated the presence of disorganization of the structural components of the organ, swelling of hepatocytes, and sometimes their necrosis. Histioleukocyte infiltration, congestion in vessels and a significant increase in the functional activity of Kupffer cells were also detected [8].

The results of research by Ghosh R. and co-authors [9] on the hepatotoxicity of *Vipera russelli* viper venom confirmed the development of destructive and dystrophic changes in the structure of the liver under the conditions of its administration to experimental animals. During histological examination of organ samples, signs of karyopyknosis, karyorrhexis of hepatocytes, their vacuolar and fatty dystrophy were observed. Sometimes characteristic manifestations of necrosis of liver cells, pronounced dilatation of sinusoidal capillaries, stagnation of central veins were noted. Leukocyte infiltration of liver tissue was characteristic. An increase in ALT and AST activity was recorded in the blood plasma of experimental rats.

S. Al-Quraishy et al. [1], studying the effect of *Naja haje* snake venom on the structural and functional parameters of the liver of laboratory rats, proved its hepatotoxic effect and ability to cause the development of OS. The levels of AST, ALT, GGT, and bilirubin increased in the blood serum of animals. The activation of LP and the increase of NO in liver homogenates were characteristic. At the same time, the content of glutathione in blood plasma and organ tissue and the activity of such enzymes as glutathione reductase

(GR), glutathione-S-transferase (GST), CAT decreased significantly. At the same time, high levels of SOD and glutathione peroxidase (GPx) were detected. The authors note that under these conditions, the functioning of the respiratory chain complexes of hepatocyte mitochondria, in particular II, III and V, was disturbed. Histological studies revealed leukocyte infiltration of liver tissue around the central veins, expansion of sinusoidal capillaries, vacuolization of hepatocyte cytoplasm, and increased activity of Kupffer cells. Severe necrosis or apoptosis of liver cells was observed in some places. Immunohistochemical studies established the pronounced activity of caspase-3 in hepatocytes, which demonstrates their high readiness for apoptosis.

Conclusions

1. Under the influence of *Vipera berus berus* venom, the development of alterative changes in the liver parenchyma

and vascular disorders were microscopically revealed. The appearance of foci of leukocyte infiltration was established, which indicates the development of inflammatory processes, many binucleated hepatocytes are found in the lobules as an adaptive and compensatory reaction of the organ, unevenly and locally sharply expanded sinusoidal hemocapillaries with a sludge effect of erythrocytes are also noted.

2. A histochemical study of the content of succinate dehydrogenase in the liver of animals injected with *Vipera berus berus* venom showed uneven activity of the mitochondrial enzyme in the lobules.

3. A histochemical study of glycogen in hepatocytes of the liver of rats exposed to *Vipera berus berus* venom showed a decrease in the content of trophic inclusions.

4. An increase in the population of CD86+ cells indicates reactive inflammatory processes observed in the body as a result of the action of components of *Vipera berus berus* venom.

References

- [1] Al-Quraishy, S., Dkhil, M. A., & Abdel Moneim, A. E. (2014). Hepatotoxicity and oxidative stress induced by *Naja haje* crude venom. *J Venom Anim Toxins Incl Trop Dis*, 20 (1). doi: 10.1186/1678-9199-20-42
- [2] Asmari, A. K., Khan, H. A., Banah, F. A., Buraidi, A. A., & Manthiri, R. A. (2015). Serum biomarkers for acute hepatotoxicity of *Echis pyramidum* snake venom in rats. *Int J Clin Exp Med*, 8(1), 1376-1380. PMID: 25785140
- [3] Bališa, T., Leonardi, A., Brgles, M., Sviben, D., Kurtovic, T., Halassy, B., ... & Krizaj, I. (2020). Biological activities and proteomic profile of the venom of *Vipera ursinii ssp.*, a very rare Karst Viper from Croatia. *Toxins* (Basel), 12(3), 187. doi: 10.3390/toxins12030187
- [4] Bennett, J. M., Sunday, J., Calosi, P., Villalobos, F., Martinez, B., Molina-Venegas, R., ... & Olalla-Tarraga, M. A. (2021). The evolution of critical thermal limits of life on Earth. *Nat Commun*, 12(1), 1198. doi: 10.1038/s41467-021-21263-
- [5] Casewell, N. R., Jackson, T. N. W., Laustsen, A. H., & Sunagar, K. (2020). Causes and consequences of snake venom variation. *Trends Pharmacol Sci*, 41(8), 570-581. doi: 10.1016/j.tips.2020.05.006
- [6] Chaiyabutr, N., Chanhome, L., Vasaruchapong, T., Laoungbua, P., Khow, O., Rungsipipat, A., ... & Sitprija, V. (2020). The pathophysiological effects of Russell's viper (*Daboia siamensis*) venom and its fractions in the isolated perfused rabbit kidney model: A potential role for platelet activating factor. *Toxicon X*, (7), 100046. doi: 10.1016/j.toxcx.2020.100046
- [7] Dobrelia, N. V., Boitsova, L. V. & Danova, I. V. (2015). Правова база для проведення етичної експертизи доклінічних досліджень лікарських засобів з використанням лабораторних тварин [Legal basis for ethical examination of preclinical studies of drugs using laboratory animals]. *Фармакологія та лікарська токсикологія - Pharmacology and drug toxicology*, (2), 95-100.
- [8] França, R. F., Vieira, R. P., Ferrari, E. F., Souza, R. A., Osorio, R. A. L., Prianti-Jr, A. C. G., ... & Ribeiro, W. (2009). Acute hepatotoxicity of *Crotalus durissus terrificus* (South American rattlesnake) venom in rats. *J Venom Anim Toxins Incl Trop Dis*, 15(1), 61-78. doi: 10.1590/S1678-91992009000100007
- [9] Ghosh, R., Mana, K., & Sarkhel, S. (2018). Ameliorating effect of *Alstonia scholaris* L. bark extract on histopathological changes following viper envenomation in animal models. *Toxicol Rep*, 5, 988-993. doi: 10.1016/j.toxrep.2018.10.004.
- [10] Horalskyi, L. P., Khomych, V. T., & Kononskyi, O. I. (2011). *Основи гістологічної техніки і морфофункціональні методи досліджень у нормі та при патології [Fundamentals of histological technique and morphofunctional research methods in normal and pathology]*. Житомир, Полісся - Зhytomyr: Polissya.
- [11] Karabuvu, S., Lukšić, B., Brizić, I., Latinović, Z., Leonardi, A., & Križaj, I. (2017). Ammodytin L is the main cardiotoxic component of the *Vipera ammodytes ammodytes* venom. *Toxicon*, 139, 94-100. doi: 10.1016/j.toxicon.2017.10.003
- [12] Makarova, Y. V., Kryukova, E. V., Shelukhina, I. V., Lebedev, D. S., Andreeva, T. V., Ryazantsev, D. Y., ... & Utkin, Y. N. (2018). The First recombinant viper three-finger toxins: Inhibition of muscle and neuronal nicotinic acetylcholine receptors. *Dokl Biochem Biophys*, 479(1), 127-130. doi: 10.1134/S1607672918020205
- [13] Malina, T., Krečsak, L., Westerström, A., Szeman-Nagy, G., Gyemant, G., M-Hamvas, M., ... & Vasas, G. (2017). Individual variability of venom from the European adder (*Vipera berus berus*) from one locality in Eastern Hungary. *Toxicon*, 135, 59-70. doi: 10.1016/j.toxicon.2017.06.004
- [14] Marinho, A. D., Silveira, J. A. M., Chaves Filho, A. J. M., Jorge, A. R. C., Nogueira Junior, F. A., Pereira, V. B. M., ... & Monteiro, H. S. A. (2021). Bothrops pauloensis snake venom-derived Asp-49 and Lys-49 phospholipases A2 mediates acute kidney injury by oxidative stress and release of inflammatory cytokines. *Toxicon*, 190, 31-38. doi: 10.1016/j.toxicon.2020.12.004
- [15] Mohi-Ud-Din, R., Mir, R. H., Sawhney, G., Dar, M. A., & Bhat, Z. A. (2019). Possible pathways of hepatotoxicity caused by chemical agents. *Curr Drug Metab*, 20(11), 867-879. doi: 10.2174/1389200220666191105121653
- [16] Razok, A., Shams, A., & Yousaf, Z. (2020). Cerastes cerastes snakebite complicated by coagulopathy and cardiotoxicity with electrocardiographic changes. *Toxicon*, 188, 1-4. doi: 10.1016/j.toxicon.2020.10.003
- [17] Silva, A., Kuruppu, S., Othman, I., Goode, R. J., Hodgson, W. C., & Isbister, G. K. (2017). Neurotoxicity in Sri Lankan Russell's viper (*Daboia russelii*) envenoming is primarily due to U1-

- viperitoxin-Dr1a, a pre-synaptic neurotoxin. *Neurotox Res*, 31(1), 11-19. doi: 10.1007/s12640-016-9650-4
- [18] Siqueira-Silva, T., Lima, L., Chaves-Silveira, J., Amado, T., Naipauer, J., Riul, P., ... & Martinez, P. (2021). Ecological and biogeographic processes drive the proteome evolution of snake venom. *Global Ecology and Biogeography*, 30(10), 1978-1989. doi: 10.1111/geb.13359
- [19] Tohamy, A. A., Mohamed, A. F., Abdel Moneim, A. E., & Diab, M. S. M. (2014). Biological effects of *Naja haje* crude venom on the hepatic and renal tissues of mice. *J King Saud Univ Sci*, 26(3), 205-212. doi: 10.1016/j.jksus.2014.01.003
- [20] Wang, S. Z., & Qin, Z. H. (2018). Anti-inflammatory and immune regulatory actions of *Naja naja atra* venom. *Toxins (Basel)*, 10(3), 100. doi: 10.3390/toxins10030100

ГІСТОЛОГІЧНІ ЗМІНИ ПЕЧІНКИ ЩУРІВ ЗА УМОВ ВПЛИВУ ОТРУТИ ГАДЮК *VIPERA BERUS BERUS*

Турбал Л.В., Яременко Л.М., Масєвський О.Є.

Отрути тварин містять цілий комплекс сполук, серед яких пептиди, білки, а також інші органічні молекули та солі. Їх токсини здатні викликати виражені порушення у функціонуванні фізіологічних систем, що призводить до виникнення патологічних станів, ускладнень і навіть смерті. Метою дослідження є вивчення гістологічних змін в печінці щурів під впливом отрути гадюки *Vipera berus berus*. Експериментальні дослідження проводили на білих нелінійних щурах-самцях. Тварин умовно розділили на дві групи - контрольну та дослідну, по 10 особин у кожній. Піддослідним щурам внутрішньоочередово вводили напівлетальну дозу (LD50) (1,576 мг/г-1) отрути *Vipera berus berus* на фізіологічному розчині. Тваринам контрольної групи вводили внутрішньоочередово тільки фізіологічний розчин. Щурів виводили з експерименту через 24 години після впливу отрути, знеживляючи шляхом цервікальної дислокації. Відбирали зразки печінки тварин усіх груп для мікроскопічного дослідження. Гістологічні препарати печінки забарвлювали гематоксиліном та еозином. Гістологічні препарати досліджували за допомогою світлового мікроскопа SEO SCAN. Для ідентифікації ключового ферменту циклу лимонної кислоти - сукцинатдегідрогенази, проводили гістохімічні дослідження за методом Нахласа. Для вивчення особливостей накопичення глікогену в гепатоцитах зрізи фарбували реактивом Шиффа після попередньої обробки йодною кислотою (PAS-реакція) у модифікації Шабадаша. Імуногістохімічним методом виявлено субпопуляцію клітин CD86+ у печінці експериментальних тварин. Під впливом отрути гадюки *Vipera berus berus* мікроскопічно виявлено розвиток альтеративних змін паренхіми печінки та судинних розладів. Встановлено появу вогнищ лейкоцитарної інфільтрації, що свідчить про розвиток запальних процесів. Гістохімічне дослідження вмісту сукцинатдегідрогенази в печінці тварин, яким вводили отруту *Vipera berus berus*, показало нерівномірність активності мітохондріального ферменту в часточках. При гістохімічному дослідженні глікогену в гепатоцитах печінки щурів, які зазнали дії отрути *Vipera berus berus*, виявлено зниження вмісту трофічних включень. Збільшення популяції клітин CD86+ свідчить про реактивні запальні процеси, що спостерігаються в організмі внаслідок дії компонентів отрути гадюки.

Ключові слова: гадюки, печінка, сукцинатдегідрогеназа, глікоген, CD86+.

Author's contribution

Turbal L. V.: analysis of scientific literature, development of the main theoretical and practical provisions of the study, conducting the study, analysis of the obtained results.

Yaremenko L. M.: development of the study's main theoretical and practical provisions, formulation of conclusions.

Maievskiy O. Ye.: development of the study's main theoretical and practical provisions, formulation of conclusions.